National Comprehensive Cancer Network®

NCCN Clinical Practice Guidelines in Oncology (NCCN Guidelines®)

Bone Cancer

Version 2.2026 — December 19, 2025

NCCN recognizes the importance of clinical trials and encourages participation when applicable and available. Trials should be designed to maximize inclusiveness and broad representative enrollment.

NCCN Guidelines for Patients® available at www.nccn.org/patients

Version 2.2026, 12/19/2025 © 2025 National Comprehensive Cancer Network® (NCCN®), All rights reserved. NCCN Guidelines® and this illustration may not be reproduced in any form without the express written permission of NCCN.

PLEASE NOTE that use of this NCCN Content is governed by the End-User License Agreement, and you MAY NOT distribute this Content or use it with any artificial intelligence model or tool.
Printed by Galya Basol Kochav on 12/28/2025 10:24:40 AM. Copyright © 2025 National Comprehensive Cancer Network, Inc. All Rights Reserved.

***J. Sybil Biermann, MD/Chair ¶ ᵀ**
University of Michigan Rogel Cancer Center

***Angela Hirbe, MD, PhD/Vice-Chair † ‡**
Siteman Cancer Center at Barnes-Jewish Hospital and Washington University School of Medicine

Shivani Ahlawat, MD ф
Johns Hopkins Kimmel Cancer Center

Nicholas M. Bernthal, MD ᵀ
UCLA Jonsson Comprehensive Cancer Center

Odion Binitie, MD ᵀ ¶
Moffitt Cancer Center

Sarah Boles, MD † ‡
UC San Diego Moores Cancer Center

Brian Brigman, MD, PHD ¶ ᵀ
Duke Cancer Institute

Alexandra K. Callan, MD ᵀ ¶
UT Southwestern Simmons Comprehensive Cancer Center

Cara Cipriano, MD, MSc ᵀ
Abramson Cancer Center at the University of Pennsylvania

Lee D. Cranmer, MD, PhD † Þ
City of Hope National Medical Center

Jessica L. Davis, MD ≠
Indiana University Melvin and Bren Simon Comprehensive Cancer Center

Eric Donnelly, MD §
Robert H. Lurie Comprehensive Cancer Center of Northwestern University

Ann Graham ¥
MIB Agents Osteosarcoma Alliance

John Groundland, MD ¶
Huntsman Cancer Institute at the University of Utah

Matthew Hess, MD ᵀ
O'Neal Comprehensive Cancer Center at UAB

Susan M. Hiniker, MD §
Stanford Cancer Institute

Margo L. Hoover-Regan, MD €
University of Wisconsin Carbone Cancer Center

Jason L. Hornick, MD, PhD ≠
Dana-Farber/Brigham and Women's Cancer Center

Brandon Jonard, MD ᵀ ¶
Case Comprehensive Cancer Center/ University Hospitals Seidman Cancer Center and Cleveland Clinic Taussig Cancer Institute

Joseph B. Kuechle, MD, PhD ¶ ᵀ
Roswell Park Comprehensive Cancer Center

Dieter Lindskog, MD ᵀ
Yale Cancer Center/Smilow Cancer Hospital

Joel L. Mayerson, MD ¶ ᵀ
The Ohio State University Comprehensive Cancer Center - James Cancer Hospital and Solove Research Institute

Sean V. McGarry, MD ᵀ ¶
Fred & Pamela Buffett Cancer Center

Carol D. Morris, MD, MS ¶ ᵀ
Memorial Sloan Kettering Cancer Center

Daniel Olson, MD †
The UChicago Medicine Comprehensive Cancer Center

Peter S. Rose, MD ᵀ ¶
Mayo Clinic Comprehensive Cancer Center

Victor M. Santana, MD €
St. Jude Children's Research Hospital/The University of Tennessee Health Science Center

Robert L. Satcher, MD, PhD ¶ ᵀ
The University of Texas MD Anderson Cancer Center

Herbert Schwartz, MD ¶ ᵀ
Vanderbilt-Ingram Cancer Center

Rebecca M. Shulman, MD §
Fox Chase Cancer Center

Catherine Vu, MD ф
UC Davis Comprehensive Cancer Center

Breelyn A. Wilky, MD †
University of Colorado Cancer Center

Rosanna L. Wustrack, MD ¶ ᵀ
UCSF Helen Diller Family Comprehensive Cancer Center

NCCN
Frankie Jones
Megan Lyons, MS
Nicholas Sansone, MFA

NCCN Guidelines Panel Disclosures

ф Diagnostic/Interventional radiology
‡ Hematology/Hematologic oncology
Þ Internal medicine
† Medical oncology
ᵀ Orthopedics
≠ Pathology
¥ Patient advocacy
€ Pediatric oncology
§ Radiotherapy/Radiation oncology
¶ Surgery/Surgical oncology
* Discussion Writing Committee Member

PLEASE NOTE that use of this NCCN Content is governed by the End-User License Agreement, and you MAY NOT distribute this Content or use it with any artificial intelligence model or tool.
Printed by Galya Basol Kochav on 12/28/2025 10:24:40 AM. Copyright © 2025 National Comprehensive Cancer Network, Inc. All Rights Reserved.

NCCN Guidelines Version 2.2026
Bone Cancer

NCCN Bone Cancer Panel Members
Summary of the Guidelines Updates

Multidisciplinary Team (TEAM-1)
Bone Cancer Workup (BONE-1)

Chondrosarcoma:
- Presentation (CHON-1)
- Primary Treatment, Atypical Cartilaginous Tumors (CHON-2)
- Primary Treatment, Low-Grade Extracompartmental Appendicular Tumors, Grade I Axial Tumors, High Grade, Clear Cell, or Extracompartmental (CHON-3)
- Metastatic Chondrosarcoma (CHON-4)

Chordoma:
- Workup and Histologic Subtype (CHOR-1)
- Presentation and Primary/Adjuvant Treatment (CHOR-2)
- Surveillance, Recurrence, and Treatment (CHOR-3)

Ewing Sarcoma:
- Workup, Primary Treatment, Restage (EW-1)
- Additional Treatment, Surveillance, and Relapse (EW-2)
- Metastatic Disease (EW-3)

Giant Cell Tumor of Bone:
- Workup and Presentation (GCTB-1)
- Primary Treatment (GCTB-2)
- Surveillance, Recurrence (GCTB-3)

Osteosarcoma:
- Workup and Primary Treatment (OSTEO-1)
- Neoadjuvant and Adjuvant Treatment (OSTEO-2)
- Metastatic Disease (OSTEO-3)
- Surveillance and Relapse (OSTEO-4)

Principles of Bone Cancer Management (BONE-A)
Systemic Therapy Agents (BONE-B)
Principles of Radiation Therapy (BONE-C)
Principles of Pathology (BONE-D)

Staging (ST-1)

Abbreviations (ABBR-1)

Find an NCCN Member Institution: https://www.nccn.org/home/member-institutions.

NCCN Categories of Evidence and Consensus: All recommendations are category 2A unless otherwise indicated.

See NCCN Categories of Evidence and Consensus.

NCCN Categories of Preference: All recommendations are considered appropriate.

See NCCN Categories of Preference.

The NCCN Guidelines® are a statement of evidence and consensus of the authors regarding their views of currently accepted approaches to treatment. Any clinician seeking to apply or consult the NCCN Guidelines is expected to use independent medical judgment in the context of individual clinical circumstances to determine any patient's care or treatment. The National Comprehensive Cancer Network® (NCCN®) makes no representations or warranties of any kind regarding their content, use or application and disclaims any responsibility for their application or use in any way. The NCCN Guidelines are copyrighted by National Comprehensive Cancer Network®. All rights reserved. The NCCN Guidelines and the illustrations herein may not be reproduced in any form without the express written permission of NCCN. ©2025.

PLEASE NOTE that use of this NCCN Content is governed by the End-User License Agreement, and you MAY NOT distribute this Content or use it with any artificial intelligence model or tool.
Printed by Galya Basol Kochav on 12/28/2025 10:24:40 AM. Copyright © 2025 National Comprehensive Cancer Network, Inc. All Rights Reserved.

Updates in Version 2.2026 of the NCCN Guidelines for Bone Cancer include:

BONE-B 1 of 7
- Footnote c added: Pembrolizumab and berahyaluronidase alfa-pmph subcutaneous injection may be substituted for IV pembrolizumab. Pembrolizumab and berahyaluronidase alfa-pmph has different dosing and administration instructions compared to IV pembrolizumab. (Also for BONE-B 2)

MS-1
- The discussion section has been updated to reflect the changes in the algorithm.

Updates in Version 1.2026 of the NCCN Guidelines for Bone Cancer include:

Global
- References updated throughout the guideline.

TEAM-1
- Footnote a added: Refer to the NCCN Distress Thermometer and Problem List, which includes social determinants of health. See NCCN Guidelines for Distress Management (DIS-A).

BONE-1
- Workup for potential bone metastasis as clinically indicated, imaging recommendations revised: Bone scan or FDG-PET/CT (category 2B) *and/or Skeletal survey, plain film, or CT (if multiple myeloma suspected)*

CHON-4
- Footnote k revised: Consider ~~comprehensive genomic profiling (CGP)~~*multigene panel testing (MGPT)* with a validated and/or FDA-approved assay to determine targeted therapy opportunities. (Also for CHOR-3 and EW-3)

CHOR-1
- Workup, 3rd bullet revised: Adequate cross-sectional imaging of primary site (eg, ~~x-ray,~~ MRI, CT) and screening MRI of spinal axis
- Histologic Subtype revised: Conventional ~~or~~ *(including* chondroid)

EW-1
- Workup
  - 6th bullet revised: Cytogenetics and/or ~~molecular studies~~ *biomarker testing*
  - 8th bullet revised: Fertility consultation should be ~~considered~~ *offered*
- Footnote d revised: Consider ~~CGP~~ *MGPT*... (Also for EW-3 and OSTEO-3)
- Footnote g revised: Ninety percent of Ewing sarcomas will have one of four specific ~~cytogenetic~~ *chromosome* translocations...For those who are negative, additional ~~molecular~~ *biomarker*...
- Footnote i added: For patients with mesenchymal chondrosarcoma, single-agent doxorubicin and doxorubicin/ifosfamide can be considered as primary systemic therapy treatment options. See BONE-B 1 of 7.
- Footnote j revised: Longer treatment prior to local control therapy can be considered in patients with metastatic disease based on response*; select patients with present, or impending, pathologic fracture or fungation may benefit from immediate surgery.*

Continued

Version 2.2026, 12/19/2025 © 2025 National Comprehensive Cancer Network® (NCCN®), All rights reserved. NCCN Guidelines® and this illustration may not be reproduced in any form without the express written permission of NCCN.

PLEASE NOTE that use of this NCCN Content is governed by the End-User License Agreement, and you MAY NOT distribute this Content or use it with any artificial intelligence model or tool.
Printed by Galya Basol Kochav on 12/28/2025 10:24:40 AM. Copyright © 2025 National Comprehensive Cancer Network, Inc. All Rights Reserved.

Updates in Version 1.2026 of the NCCN Guidelines for Bone Cancer include:

GCTB-2
- Footnote removed and added to BONE-B: An FDA-approved biosimilar is an appropriate substitute for any systemic biologic therapy in the NCCN Guidelines. (Also for GCTB-3)

OSTEO-2
- Neoadjuvant Treatment revised: ~~Preoperative~~ *Perioperative* chemotherapy (category 1) *(preoperative preferred)*
- Footnote i added: There does not appear to be a survival benefit for individuals who have received neoadjuvant chemotherapy compared to adjuvant chemotherapy. Histologic response to neoadjuvant chemotherapy may provide prognostic information, but does not affect outcome. Bernthal NM, et al. Cancer 2012;118:5888-5893; Provisor AJ, et al. J Clin Oncol 1997;15:76-84.

OSTEO-4
- Relapse/Progression
  - Treatment option added: Excision, if possible or Clinical trial or RT *or Embolization/ablation* or Best supportive care

BONE-A
- Principles of Bone Cancer Management language updated throughout section: ~~molecular studies~~ *biomarker testing*

BONE-B 1 of 7
- Chondrosarcoma
  - Dedifferentiated
    - Preferred, 1st bullet revised: ~~Follow~~ *Consider* osteosarcoma regimens (category 2B)
    - Useful in Certain Circumstances, treatment options added as category 2A recommendations
      - Pazopanib or Sunitinib
      - Pembrolizumab or Nivolumab
      - Sunitinib + Nivolumab
  - Mesenchymal, Preferred
    - 1st bullet revised: ~~Follow~~ Ewing sarcoma regimens (category 2B)
    - Treatment options added as category 2A recommendations
      - Doxorubicin
      - Doxorubicin/Ifosfamide
- Footnote b revised: Pembrolizumab is a systemic treatment option for adult and pediatric patients with unresectable or metastatic, MSI-high (MSI-H) or MMR deficient (dMMR) solid tumors that have progressed following prior treatment and who have no satisfactory alternative treatment options. ~~Additional dosing recommendations are as follows: 200 mg IV Day 1, repeat every 3 weeks or 400 mg IV Day 1, repeat every 6 weeks until disease progression, unacceptable toxicity, or up to 24 months for treatment of patients with MSI-H bone cancer.~~ Not for giant cell tumor of bone.
- Footnote c revised: Consider ~~CGP~~ *MGPT* with a validated and/or FDA-approved assay to determine targeted therapy opportunities. TMB~~-high (TMB-H)~~ *testing is recommended* for patients with unresectable or metastatic tumors who have progressed following prior treatment and who have no satisfactory alternative treatment options. Not for giant cell tumor of bone.
- Footnote e added: Nivolumab and hyaluronidase-nvhy subcutaneous injection may be substituted for IV nivolumab. Nivolumab and hyaluronidase-nvhy has different dosing and administration instructions compared to IV nivolumab.

Continued

Version 2.2026, 12/19/2025 © 2025 National Comprehensive Cancer Network® (NCCN®), All rights reserved. NCCN Guidelines® and this illustration may not be reproduced in any form without the express written permission of NCCN.

PLEASE NOTE that use of this NCCN Content is governed by the End-User License Agreement, and you MAY NOT distribute this Content or use it with any artificial intelligence model or tool.
Printed by Galya Basol Kochav on 12/28/2025 10:24:40 AM. Copyright © 2025 National Comprehensive Cancer Network, Inc. All Rights Reserved.

Updates in Version 1.2026 of the NCCN Guidelines for Bone Cancer include:

BONE-B 2 of 7
- Chordoma, Other Recommended: Pembrolizumab added as a category 2A recommendation

BONE-C 1 of 6
- Principles of Radiation Therapy language updated throughout section
  - R0 replaced with: negative margins
  - R1 replaced with: microscopically positive margins
  - R2 replaced with: gross positive margins
  - Footnote removed: R0 = No microscopic residual disease, R1 = Microscopic residual disease, R2 = Gross residual disease.

BONE-C 3 of 6
- Principles of Radiation Therapy
  - Preoperative RT, 1st bullet, 1st sub-bullet revised: May be considered for marginally resectable tumors and is given concurrently with ~~consolidation~~ chemotherapy
  - Postoperative RT, 1st bullet, 1st sub-bullet revised: Should begin within 60 days of surgery and is given concurrently with ~~consolidation~~ chemotherapy

BONE-D 1 of 2
- Principles of Pathology
  - 4th bullet, 11th sub-bullet, Margin status
    - 1st diamond sub-bullet removed: R0, R1, or R2 (R classification system per AJCC)
    - 2nd diamond sub-bullet, 1st dash revised: Necrotic tumor at margin for Ewing sarcoma is considered a negative ~~(R0)~~ margin if there is a complete pathologic response.
  - 4th bullet, 12th sub-bullet, Ancillary studies
    - 1st diamond sub-bullet revised: Decalcification *on a portion of the specimen* should optimally be performed with solutions that preserve RNA and DNA; *strong* acid-based decalcification (other than EDTA *or EDTA + formic acid solutions*) should therefore be avoided.

Version 2.2026, 12/19/2025 © 2025 National Comprehensive Cancer Network® (NCCN®), All rights reserved. NCCN Guidelines® and this illustration may not be reproduced in any form without the express written permission of NCCN.

PLEASE NOTE that use of this NCCN Content is governed by the End-User License Agreement, and you MAY NOT distribute this Content or use it with any artificial intelligence model or tool.
Printed by Galya Basol Kochav on 12/28/2025 10:24:40 AM. Copyright © 2025 National Comprehensive Cancer Network, Inc. All Rights Reserved.

MULTIDISCIPLINARY TEAM[a]

Primary bone tumors and selected metastatic tumors should be evaluated and treated by a multidisciplinary team with expertise in the management of these tumors. The team should meet on a regular basis and should include:

Core Group
- **Orthopedic oncologist**
- **Bone pathologist**
- **Medical/pediatric oncologist**
- **Radiation oncologist**
- **Musculoskeletal radiologist**

Specialists Critical in Certain Cases
- **Thoracic surgeon**
- **Plastic surgeon**
- **Interventional radiologist**
- **Physiatrist**
- **Vascular/general surgeon**
- **Neurosurgeon/orthopedic spine surgeon**
- **Palliative care physician**
- **Additional surgical subspecialties as clinically indicated**

[a] Refer to the NCCN Distress Thermometer and Problem List, which includes social determinants of health. See NCCN Guidelines for Distress Management (DIS-A).

Note: All recommendations are category 2A unless otherwise indicated.

Version 2.2026, 12/19/2025 © 2025 National Comprehensive Cancer Network® (NCCN®), All rights reserved. NCCN Guidelines® and this illustration may not be reproduced in any form without the express written permission of NCCN.

PLEASE NOTE that use of this NCCN Content is governed by the End-User License Agreement, and you MAY NOT distribute this Content or use it with any artificial intelligence model or tool.
Printed by Galya Basol Kochav on 12/28/2025 10:24:40 AM. Copyright © 2025 National Comprehensive Cancer Network, Inc. All Rights Reserved.

WORKUP

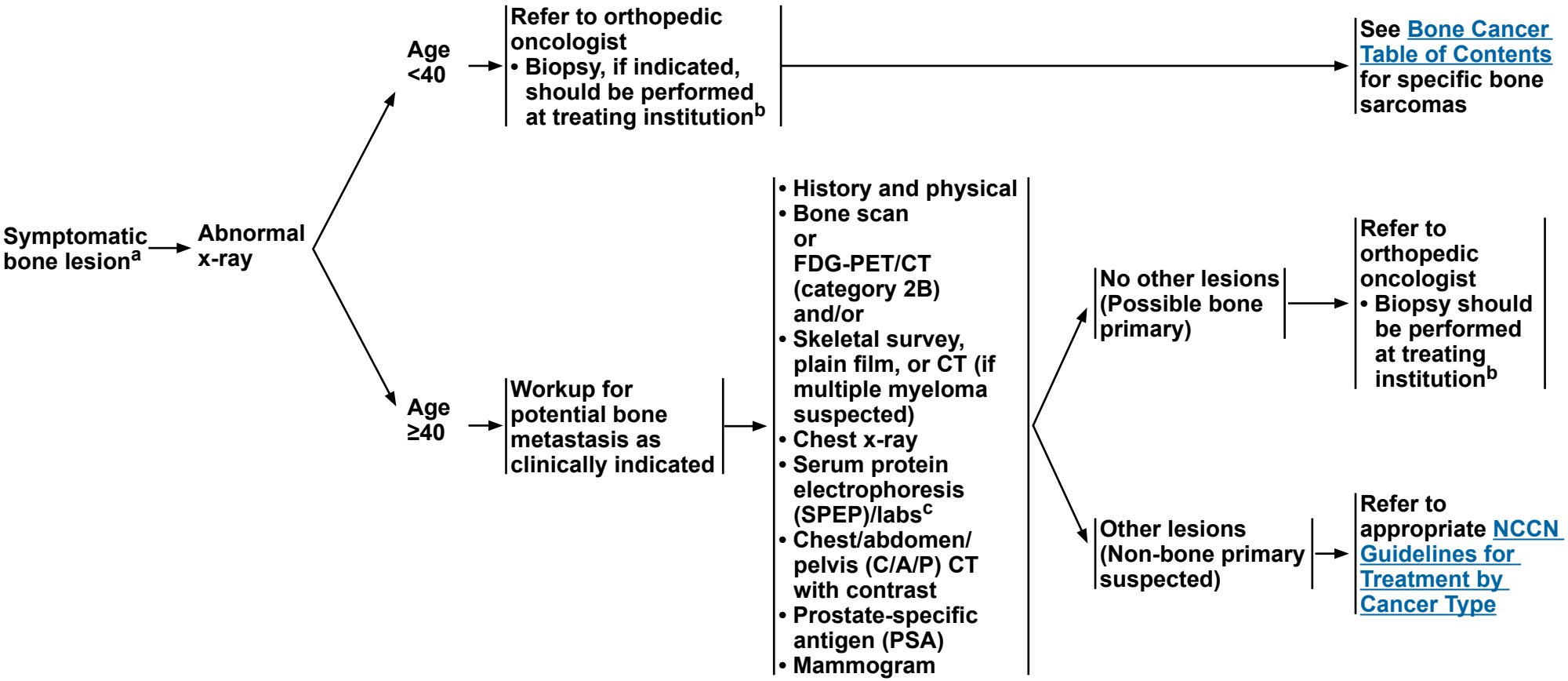

[a] Multidisciplinary Team (TEAM-1).
[b] Principles of Bone Cancer Management (BONE-A).
[c] Labs include complete blood count (CBC) and comprehensive metabolic panel (CMP) with calcium to assess for hypercalcemia.

Note: All recommendations are category 2A unless otherwise indicated.

Version 2.2026, 12/19/2025 © 2025 National Comprehensive Cancer Network® (NCCN®), All rights reserved. NCCN Guidelines® and this illustration may not be reproduced in any form without the express written permission of NCCN.

PLEASE NOTE that use of this NCCN Content is governed by the End-User License Agreement, and you MAY NOT distribute this Content or use it with any artificial intelligence model or tool.
Printed by Galya Basol Kochav on 12/28/2025 10:24:40 AM. Copyright © 2025 National Comprehensive Cancer Network, Inc. All Rights Reserved.

PRESENTATION[a,b,c]

Atypical cartilaginous tumors[d] → CHON-2

Low-grade extracompartmental appendicular tumors
or
Grade I axial tumors
or
High-grade (grade II, grade III)
or
Clear cell
or
Extracompartmental → CHON-3

Metastatic disease at presentation → CHON-4

Dedifferentiated → CHON-3 and CHON-4

Mesenchymal → CHON-3 and CHON-4

[a] Multidisciplinary Team (TEAM-1).
[b] Principles of Bone Cancer Management (BONE-A).
[c] There is considerable controversy regarding the grading of chondrosarcoma. In addition to histology, radiologic features, size, and location of tumors should also be considered in deciding local treatment.
[d] Defined as low-grade intracompartmental appendicular tumors. WHO Classification of Tumours Editorial Board. Soft Tissue and Bone Tumours. Lyon (France): International Agency for Research on Cancer; 2020. WHO Classification of Tumours Series, 5th Edition, Volume 3.

Note: All recommendations are category 2A unless otherwise indicated.

Version 2.2026, 12/19/2025 © 2025 National Comprehensive Cancer Network® (NCCN®), All rights reserved. NCCN Guidelines® and this illustration may not be reproduced in any form without the express written permission of NCCN.

PLEASE NOTE that use of this NCCN Content is governed by the End-User License Agreement, and you MAY NOT distribute this Content or use it with any artificial intelligence model or tool.
Printed by Galya Basol Kochav on 12/28/2025 10:24:40 AM. Copyright © 2025 National Comprehensive Cancer Network, Inc. All Rights Reserved.

	PRIMARY TREATMENT[e]	SURVEILLANCE	RECURRENCE	WORKUP
Atypical cartilaginous tumors[d] →	Intralesional excision ± surgical adjuvant[f] or Observation →	• Physical exam • X-rays of primary site and/or cross-sectional imaging every 6–12 mo for 2 y, then yearly, as clinically indicated: ▸ CT with contrast or ▸ MRI with and without contrast	→ Local recurrence →	• Imaging of primary site as clinically indicated (eg, x-ray, MRI with and without contrast, and CT with contrast) • Chest imaging • Bone scan (optional) • Biopsy to confirm diagnosis • If there is malignant transformation, treat as described on CHON-3

[d] Defined as low-grade intracompartmental appendicular tumors. WHO Classification of Tumours Editorial Board. Soft tissue and bone tumours. Lyon (France): International Agency for Research on Cancer; 2020. (WHO classification of tumours series, 5th ed.; vol. 3).
[e] There are no known standard chemotherapy options for conventional chondrosarcoma grades 1–3, but ivosidenib is an option for susceptible *IDH1* mutations. See Systemic Therapy Agents (BONE-B).
[f] Wide excision optional in expendable bones.

Note: All recommendations are category 2A unless otherwise indicated.

Version 2.2026, 12/19/2025 © 2025 National Comprehensive Cancer Network® (NCCN®), All rights reserved. NCCN Guidelines® and this illustration may not be reproduced in any form without the express written permission of NCCN.

PLEASE NOTE that use of this NCCN Content is governed by the End-User License Agreement, and you MAY NOT distribute this Content or use it with any artificial intelligence model or tool.
Printed by Galya Basol Kochav on 12/28/2025 10:24:40 AM. Copyright © 2025 National Comprehensive Cancer Network, Inc. All Rights Reserved.

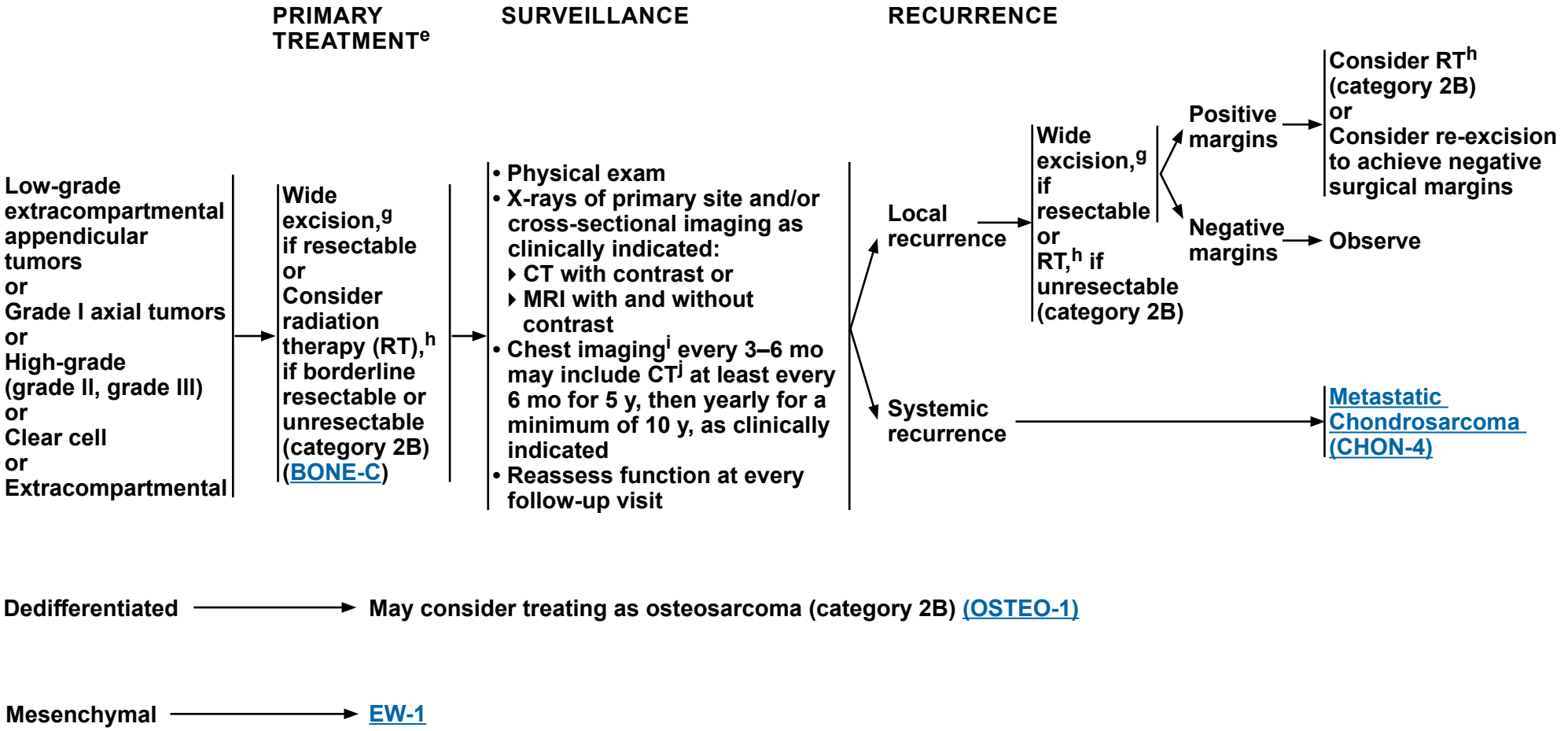

[e] There are no known standard chemotherapy options for conventional chondrosarcoma grades 1–3, but ivosidenib is an option for susceptible *IDH1* mutations. See Systemic Therapy Agents (BONE-B).
[g] Wide excision should provide histologically negative surgical margins. This may be achieved by either limb-sparing excision or limb amputation.
[h] Principles of Radiation Therapy (BONE-C).
[i] Based on physician's concern for risk of recurrence.
[j] Chest CT can be performed with or without contrast as clinically indicated. Low-dose, non-contrast CT is recommended for restaging.

Note: All recommendations are category 2A unless otherwise indicated.

Version 2.2026, 12/19/2025 © 2025 National Comprehensive Cancer Network® (NCCN®), All rights reserved. NCCN Guidelines® and this illustration may not be reproduced in any form without the express written permission of NCCN.

PLEASE NOTE that use of this NCCN Content is governed by the End-User License Agreement, and you MAY NOT distribute this Content or use it with any artificial intelligence model or tool.
Printed by Galya Basol Kochav on 12/28/2025 10:24:40 AM. Copyright © 2025 National Comprehensive Cancer Network, Inc. All Rights Reserved.

METASTATIC CHONDROSARCOMA[k]

Dedifferentiated[l]

Mesenchymal (EW-1)

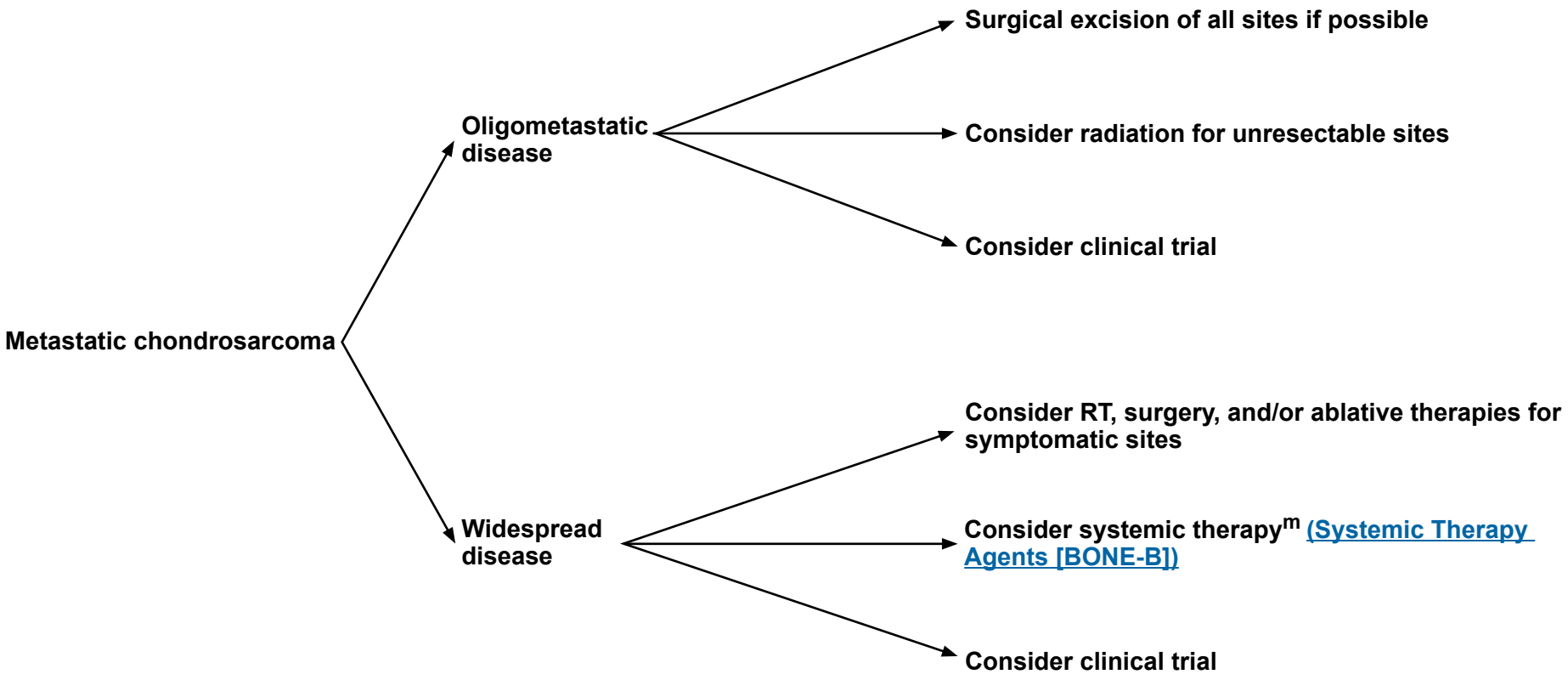

[k] Consider multigene panel testing (MGPT) with a validated and/or FDA-approved assay to determine targeted therapy opportunities.
[l] May consider treating as osteosarcoma (category 2B) (OSTEO-1).
[m] Consider testing for tumor mutational burden (TMB) and mismatch repair/microsatellite instability (MMR/MSI) as determined by a validated and/or FDA-approved assay to inform treatment options.

Note: All recommendations are category 2A unless otherwise indicated.

Version 2.2026, 12/19/2025 © 2025 National Comprehensive Cancer Network® (NCCN®), All rights reserved. NCCN Guidelines® and this illustration may not be reproduced in any form without the express written permission of NCCN.

PLEASE NOTE that use of this NCCN Content is governed by the End-User License Agreement, and you MAY NOT distribute this Content or use it with any artificial intelligence model or tool.
Printed by Galya Basol Kochav on 12/28/2025 10:24:40 AM. Copyright © 2025 National Comprehensive Cancer Network, Inc. All Rights Reserved.

WORKUP[a]

- All patients should be evaluated and treated by a multidisciplinary team with expertise in the management of chordoma[a]
- History and physical
- Adequate cross-sectional imaging of primary site (eg, MRI, CT) and screening MRI of spinal axis
- C/A/P CT with contrast
- Consider FDG-PET/CT (skull base to mid-thigh)
- Consider bone scan if FDG-PET/CT is negative

HISTOLOGIC SUBTYPE

- Conventional (including chondroid) → Presentation and Primary Treatment (CHOR-2)
- Poorly differentiated or Dedifferentiated → NCCN Guidelines for Soft Tissue Sarcoma

[a] Multidisciplinary Team (TEAM-1).

Note: All recommendations are category 2A unless otherwise indicated.

Version 2.2026, 12/19/2025 © 2025 National Comprehensive Cancer Network® (NCCN®), All rights reserved. NCCN Guidelines® and this illustration may not be reproduced in any form without the express written permission of NCCN.

PLEASE NOTE that use of this NCCN Content is governed by the End-User License Agreement, and you MAY NOT distribute this Content or use it with any artificial intelligence model or tool.
Printed by Galya Basol Kochav on 12/28/2025 10:24:40 AM. Copyright © 2025 National Comprehensive Cancer Network, Inc. All Rights Reserved.

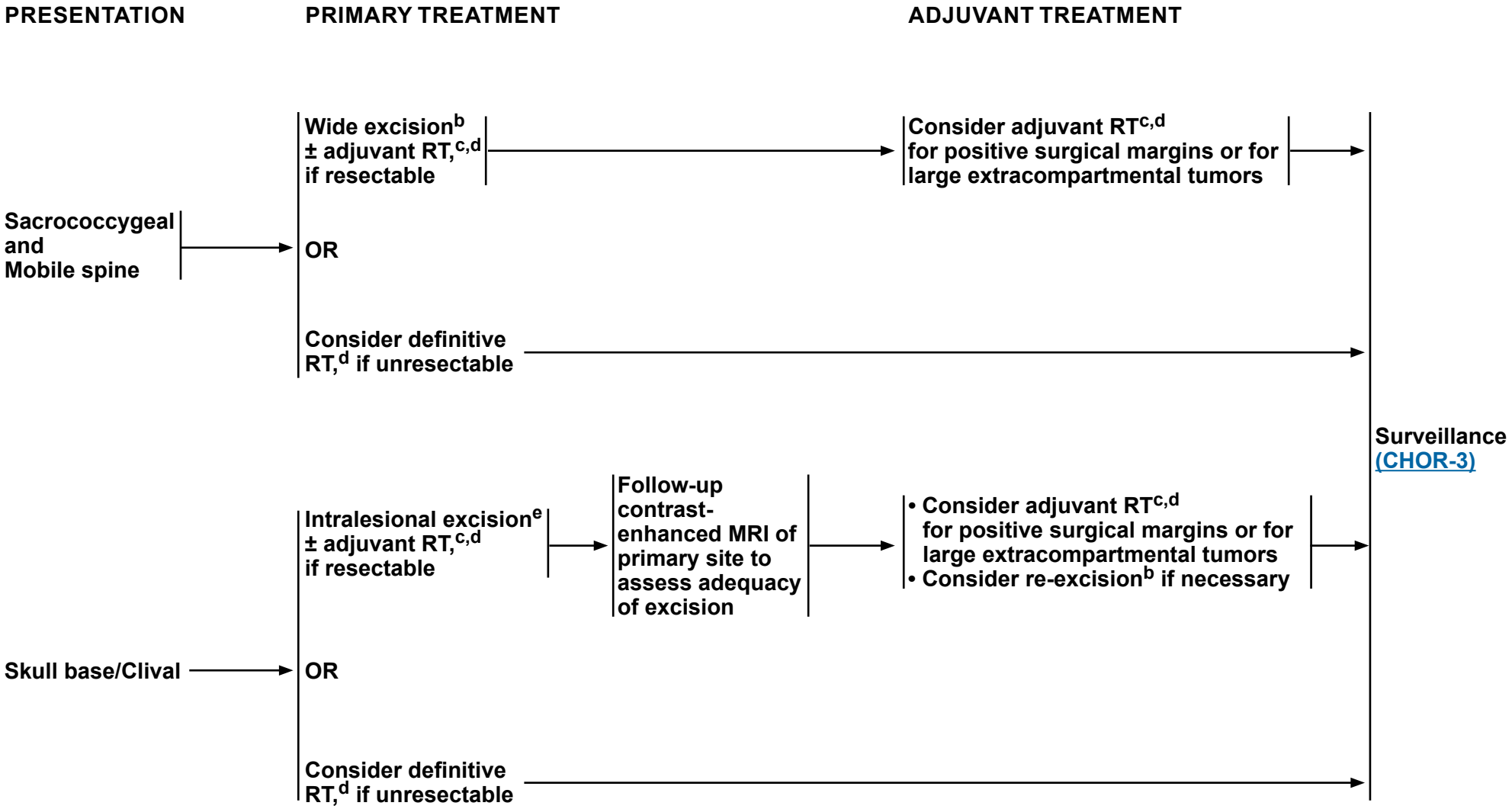

[b] Principles of Bone Cancer Management (BONE-A).
[c] RT may be given preoperatively, intraoperatively, and/or postoperatively.
[d] Principles of Radiation Therapy (BONE-C).
[e] Maximal safe excision. Maximal tumor removal is recommended when appropriate.

Note: All recommendations are category 2A unless otherwise indicated.

Version 2.2026, 12/19/2025 © 2025 National Comprehensive Cancer Network® (NCCN®), All rights reserved. NCCN Guidelines® and this illustration may not be reproduced in any form without the express written permission of NCCN.

PLEASE NOTE that use of this NCCN Content is governed by the End-User License Agreement, and you MAY NOT distribute this Content or use it with any artificial intelligence model or tool.
Printed by Galya Basol Kochav on 12/28/2025 10:24:40 AM. Copyright © 2025 National Comprehensive Cancer Network, Inc. All Rights Reserved.

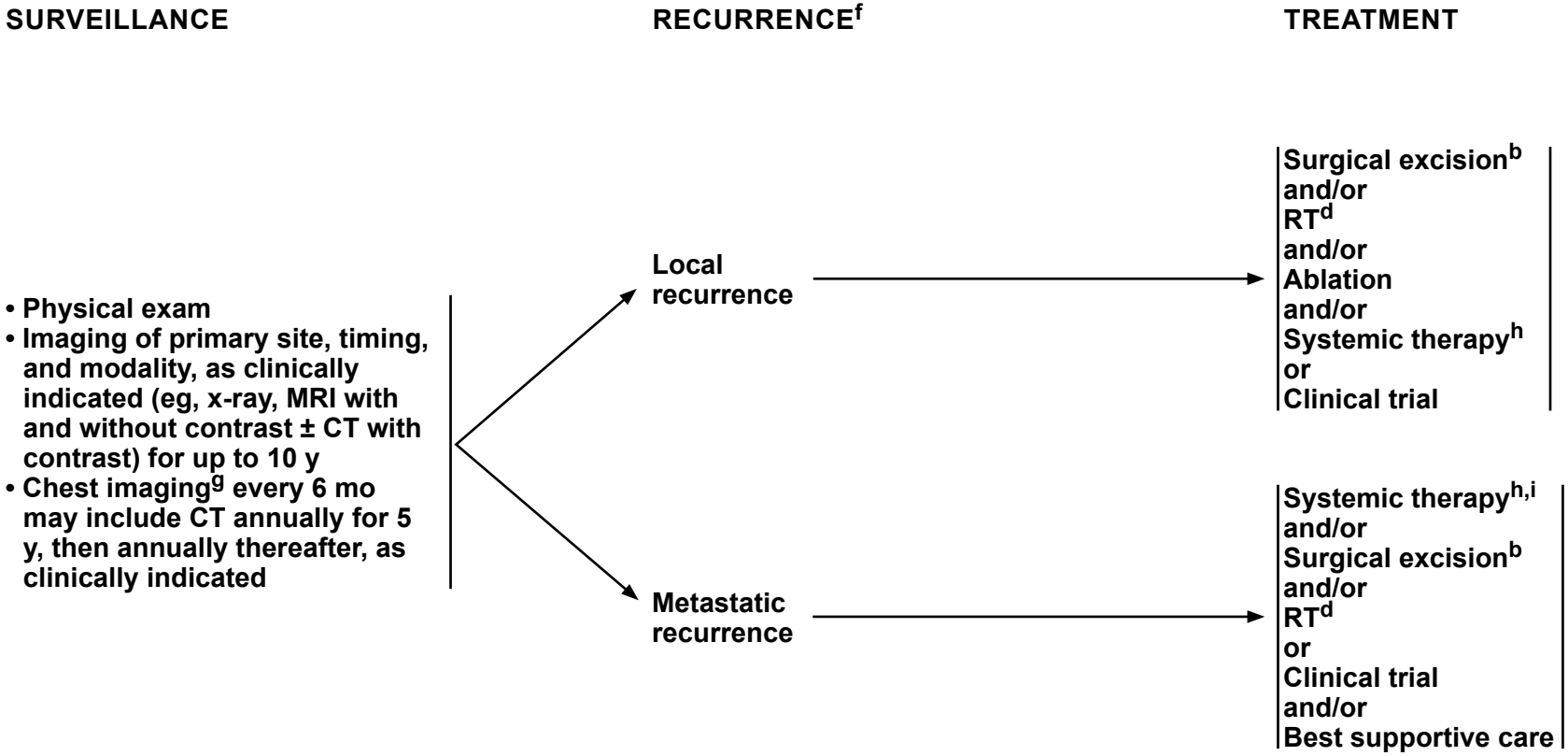

[b] Principles of Bone Cancer Management (BONE-A).
[d] Principles of Radiation Therapy (BONE-C).
[f] Consider MGPT with a validated and/or FDA-approved assay to determine targeted therapy opportunities.
[g] Chest CT can be performed with or without contrast as clinically indicated. Low-dose, non-contrast CT is recommended for restaging.
[h] Bone Cancer Systemic Therapy Agents (BONE-B).
[i] Consider testing for TMB and MMR/MSI as determined by a validated and/or FDA-approved assay to inform treatment options.

Note: All recommendations are category 2A unless otherwise indicated.

Version 2.2026, 12/19/2025 © 2025 National Comprehensive Cancer Network® (NCCN®), All rights reserved. NCCN Guidelines® and this illustration may not be reproduced in any form without the express written permission of NCCN.

PLEASE NOTE that use of this NCCN Content is governed by the End-User License Agreement, and you MAY NOT distribute this Content or use it with any artificial intelligence model or tool.
Printed by Galya Basol Kochav on 12/28/2025 10:24:40 AM. Copyright © 2025 National Comprehensive Cancer Network, Inc. All Rights Reserved.

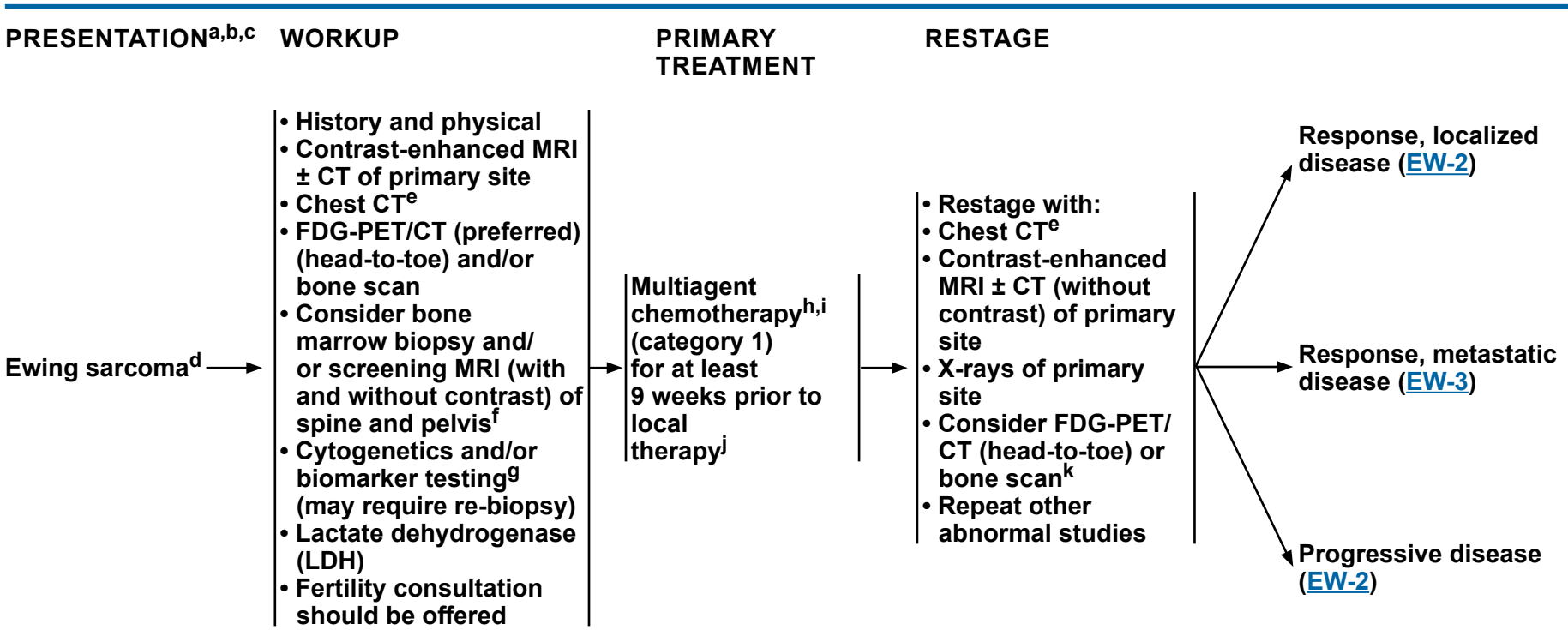

[a] Multidisciplinary Team (TEAM-1).
[b] Principles of Bone Cancer Management (BONE-A).
[c] Ewing sarcoma can be treated using this algorithm, including primitive neuroectodermal tumor of bone, Askin tumor, and extraosseous Ewing sarcoma.
[d] Consider MGPT or other fusion panel for Ewing sarcoma to identify translocations if pathologic workup of targeted polymerase chain reaction (PCR), fluorescence in situ hybridization (FISH), or cytogenetics is negative.
[e] Chest CT can be performed with or without contrast as clinically indicated. Low-dose, non-contrast CT is recommended for restaging.
[f] Campbell KM, et al. Pediatr Blood Cancer 2021;68:e28807.
[g] Ninety percent of Ewing sarcomas will have one of four specific chromosome translocations. For patients with other primary round cell sarcomas of bone (eg, *CIC::DUX4, BCOR::CCNB3*), treating as Ewing sarcoma can be considered. For those who are negative, additional biomarker testing is recommended. Other primary round cell sarcoma of bone was previously referred to as Ewing-like sarcoma, which is terminology that is no longer included in the WHO classification.
[h] Bone Cancer Systemic Therapy Agents (BONE-B).
[i] For patients with mesenchymal chondrosarcoma, single-agent doxorubicin and doxorubicin/ifosfamide can be considered as primary systemic therapy treatment options. See BONE-B 1 of 7.
[j] Longer treatment prior to local control therapy can be considered in patients with metastatic disease based on response; select patients with present, or impending, pathologic fracture or fungation may benefit from immediate surgery.
[k] Use the same imaging technique that was performed in the initial workup.

Note: All recommendations are category 2A unless otherwise indicated.

Version 2.2026, 12/19/2025 © 2025 National Comprehensive Cancer Network® (NCCN®), All rights reserved. NCCN Guidelines® and this illustration may not be reproduced in any form without the express written permission of NCCN.

PLEASE NOTE that use of this NCCN Content is governed by the End-User License Agreement, and you MAY NOT distribute this Content or use it with any artificial intelligence model or tool.
Printed by Galya Basol Kochav on 12/28/2025 10:24:40 AM. Copyright © 2025 National Comprehensive Cancer Network, Inc. All Rights Reserved.

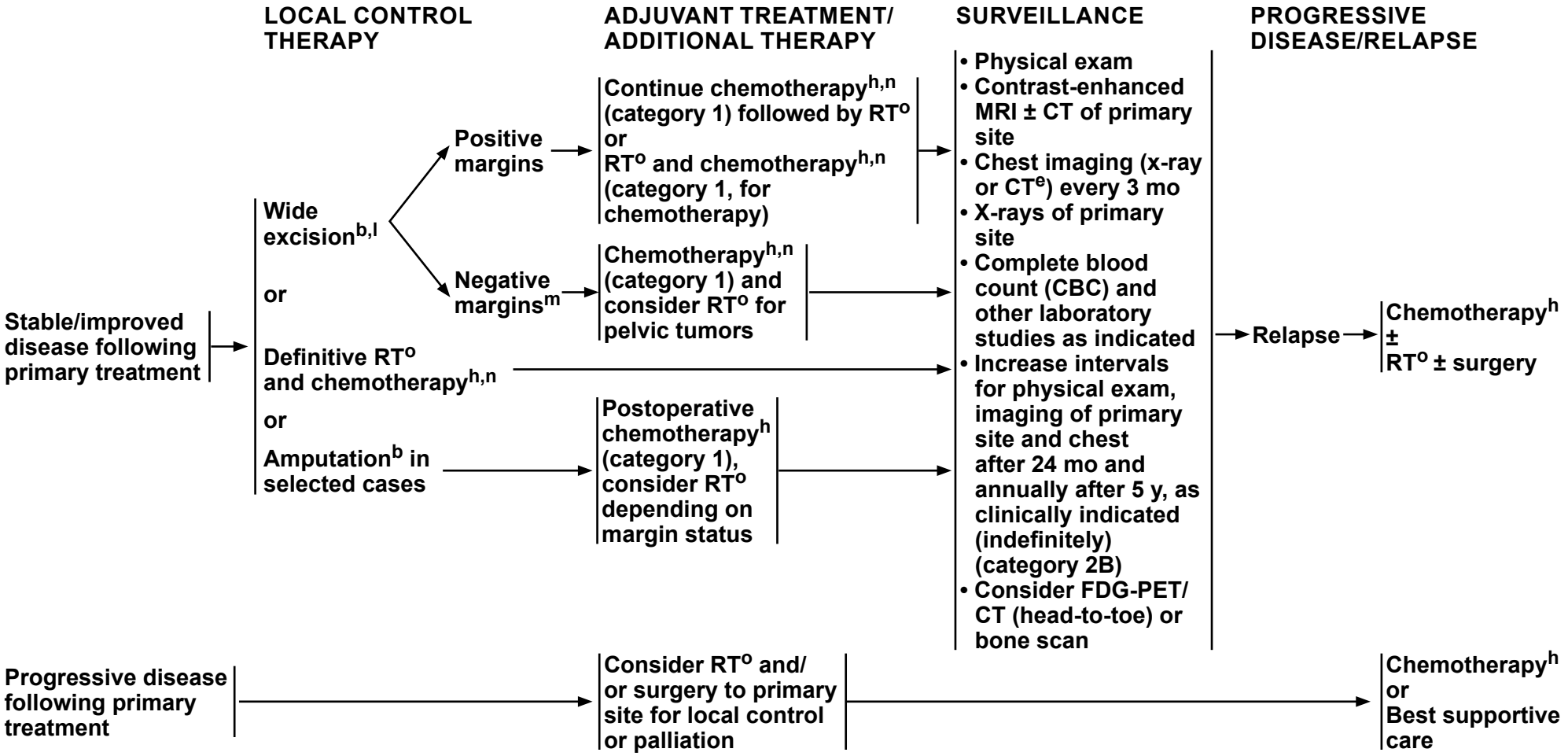

[b] Principles of Bone Cancer Management (BONE-A).
[e] Chest CT can be performed with or without contrast as clinically indicated. Low-dose, non-contrast CT is recommended for restaging.
[h] Bone Cancer Systemic Therapy Agents (BONE-B).
[l] Consider preoperative RT for marginally resectable lesions.
[m] RT may be considered for close margins.
[n] There is category 1 evidence for between 28 and 49 weeks of chemotherapy depending on the chemotherapy and dosing schedule used.
[o] Principles of Radiation Therapy (BONE-C).

Note: All recommendations are category 2A unless otherwise indicated.

Version 2.2026, 12/19/2025 © 2025 National Comprehensive Cancer Network® (NCCN®), All rights reserved. NCCN Guidelines® and this illustration may not be reproduced in any form without the express written permission of NCCN.

PLEASE NOTE that use of this NCCN Content is governed by the End-User License Agreement, and you MAY NOT distribute this Content or use it with any artificial intelligence model or tool.
Printed by Galya Basol Kochav on 12/28/2025 10:24:40 AM. Copyright © 2025 National Comprehensive Cancer Network, Inc. All Rights Reserved.

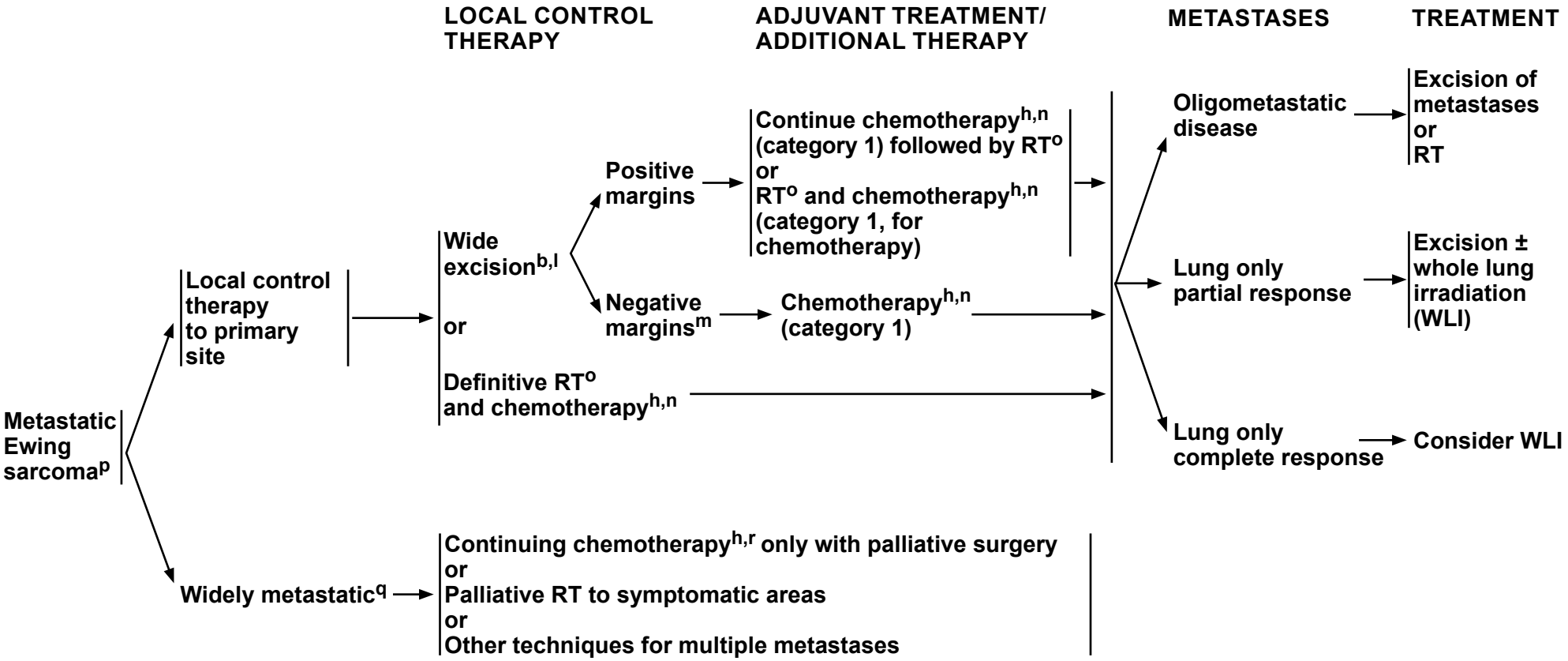

[b] Principles of Bone Cancer Management (BONE-A).
[h] Bone Cancer Systemic Therapy Agents (BONE-B).
[l] Consider preoperative RT for marginally resectable lesions.
[m] RT may be considered for close margins.
[n] There is category 1 evidence for between 28 and 49 weeks of chemotherapy depending on the chemotherapy and dosing schedule used.
[o] Principles of Radiation Therapy (BONE-C).
[p] Consider MGPT with a validated and/or FDA-approved assay to determine targeted therapy opportunities.
[q] Local control cannot be delivered to all areas of disease.
[r] Consider testing for TMB (category 2B) and MMR/MSI as determined by a validated and/or FDA-approved assay to inform treatment options.

Note: All recommendations are category 2A unless otherwise indicated.

Version 2.2026, 12/19/2025 © 2025 National Comprehensive Cancer Network® (NCCN®), All rights reserved. NCCN Guidelines® and this illustration may not be reproduced in any form without the express written permission of NCCN.

PLEASE NOTE that use of this NCCN Content is governed by the End-User License Agreement, and you MAY NOT distribute this Content or use it with any artificial intelligence model or tool.
Printed by Galya Basol Kochav on 12/28/2025 10:24:40 AM. Copyright © 2025 National Comprehensive Cancer Network, Inc. All Rights Reserved.

WORKUP

- History and physical examination
- Imaging of primary site as clinically indicated (eg, x-ray and MRI with and without contrast ± CT)
- Chest imaging
- Bone scan (optional)
- Biopsy to confirm diagnosis[a,b]
- If there is malignant transformation, treat as described for osteosarcoma (OSTEO-1)

PRESENTATION

Localized disease → GCTB-2

Metastatic disease at presentation → GCTB-2

[a] Brown tumor of hyperparathyroidism should be considered as a differential diagnosis.
[b] Principles of Bone Cancer Management (BONE-A).

Note: All recommendations are category 2A unless otherwise indicated.

Version 2.2026, 12/19/2025 © 2025 National Comprehensive Cancer Network® (NCCN®), All rights reserved. NCCN Guidelines® and this illustration may not be reproduced in any form without the express written permission of NCCN.

PLEASE NOTE that use of this NCCN Content is governed by the End-User License Agreement, and you MAY NOT distribute this Content or use it with any artificial intelligence model or tool.
Printed by Galya Basol Kochav on 12/28/2025 10:24:40 AM. Copyright © 2025 National Comprehensive Cancer Network, Inc. All Rights Reserved.

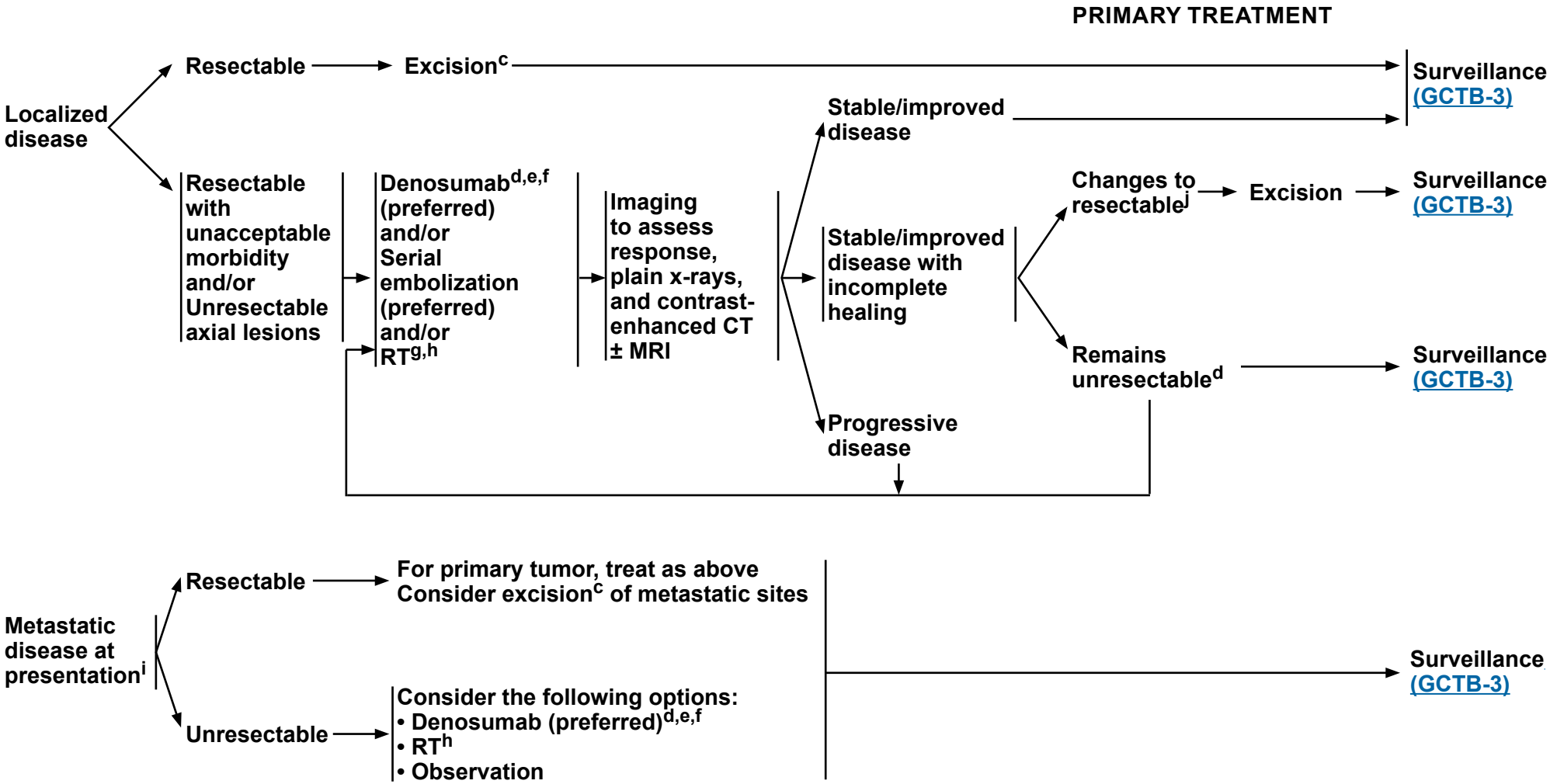

[c] Intralesional excision with an effective adjuvant may be adequate.
[d] Denosumab may be continued until disease progression, in responding disease.
[e] Bone Cancer Systemic Therapy Agents (BONE-B).
[f] Consider consultation with dentist prior to initial therapy.
[g] RT may be associated with increased risk of malignant transformation.
[h] Principles of Radiation Therapy (BONE-C).
[i] Treatment of primary tumor is as described for localized disease.
[j] Long-term denosumab use may be associated with increased risk of local recurrence.

Note: All recommendations are category 2A unless otherwise indicated.

Version 2.2026, 12/19/2025 © 2025 National Comprehensive Cancer Network® (NCCN®), All rights reserved. NCCN Guidelines® and this illustration may not be reproduced in any form without the express written permission of NCCN.

PLEASE NOTE that use of this NCCN Content is governed by the End-User License Agreement, and you MAY NOT distribute this Content or use it with any artificial intelligence model or tool.
Printed by Galya Basol Kochav on 12/28/2025 10:24:40 AM. Copyright © 2025 National Comprehensive Cancer Network, Inc. All Rights Reserved.

SURVEILLANCE

- Physical exam
- Imaging of surgical site as clinically indicated (eg, x-ray, contrast-enhanced CT and/or MRI)
- Chest imaging every 6–12 mo for 4 y then annually thereafter, as clinically indicated

RECURRENCE

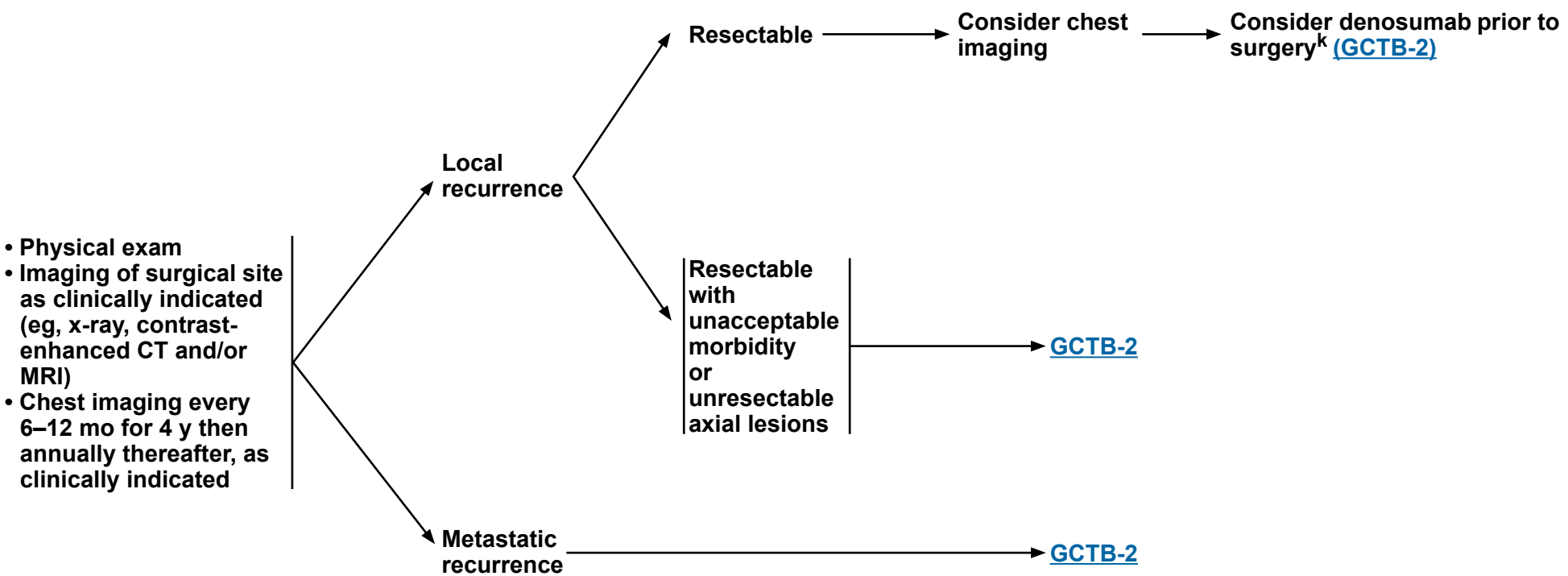

[k] Risk of local recurrence is increased when denosumab is used prior to curettage. Denosumab may be beneficial to define peripheral tumor extent when planning wide excision.

Note: All recommendations are category 2A unless otherwise indicated.

Version 2.2026, 12/19/2025 © 2025 National Comprehensive Cancer Network® (NCCN®), All rights reserved. NCCN Guidelines® and this illustration may not be reproduced in any form without the express written permission of NCCN.

PLEASE NOTE that use of this NCCN Content is governed by the End-User License Agreement, and you MAY NOT distribute this Content or use it with any artificial intelligence model or tool.
Printed by Galya Basol Kochav on 12/28/2025 10:24:40 AM. Copyright © 2025 National Comprehensive Cancer Network, Inc. All Rights Reserved.

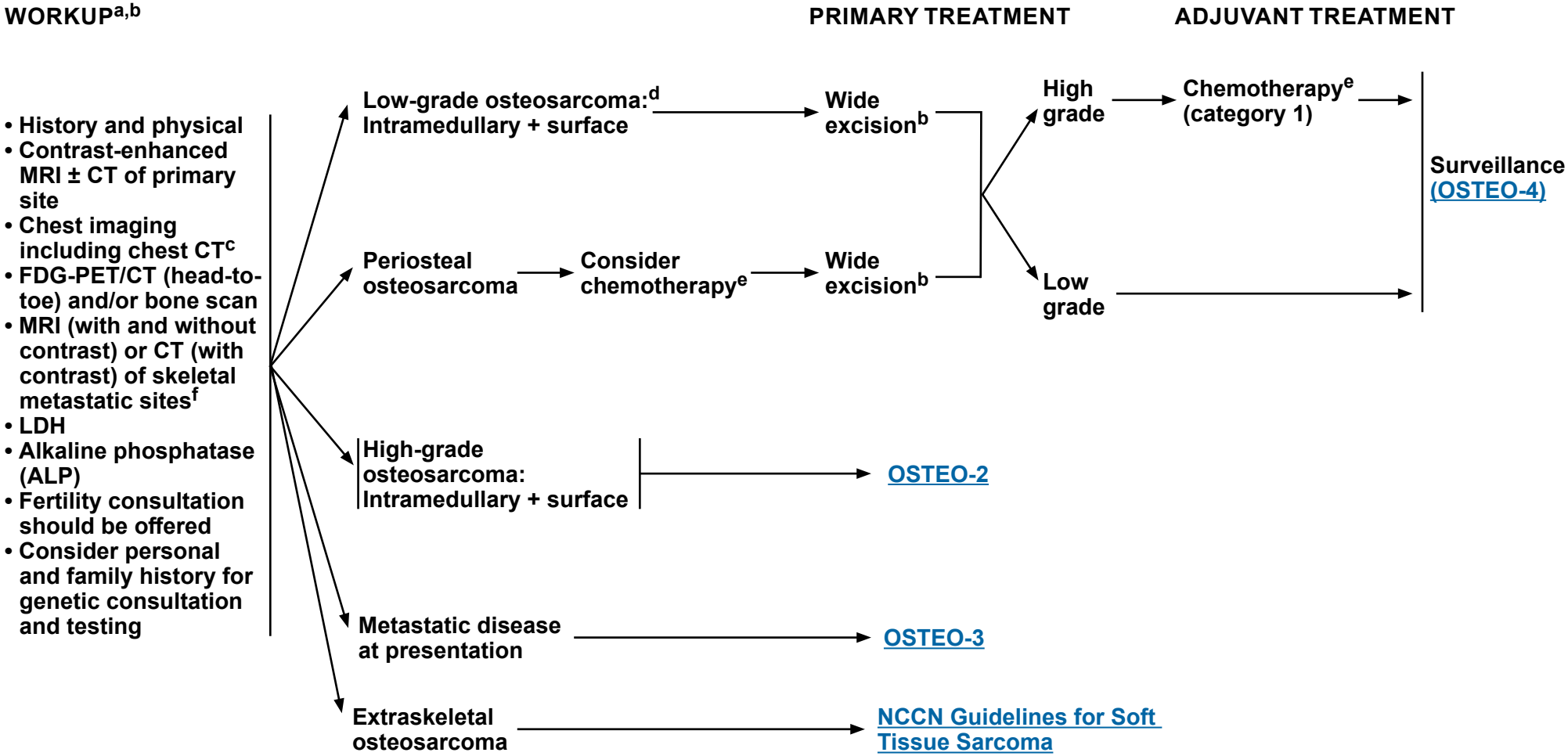

[a] Multidisciplinary Team (TEAM-1).
[b] Principles of Bone Cancer Management (BONE-A).
[c] Chest CT can be performed with or without contrast as clinically indicated. Low-dose, non-contrast CT is recommended for restaging.
[d] Dedifferentiated parosteal osteosarcomas are not considered to be low-grade tumors.
[e] Bone Cancer Systemic Therapy Agents (BONE-B).
[f] More detailed imaging (CT or MRI) of abnormalities identified on primary imaging is required for suspected metastatic disease.

Note: All recommendations are category 2A unless otherwise indicated.

Version 2.2026, 12/19/2025 © 2025 National Comprehensive Cancer Network® (NCCN®), All rights reserved. NCCN Guidelines® and this illustration may not be reproduced in any form without the express written permission of NCCN.

PLEASE NOTE that use of this NCCN Content is governed by the End-User License Agreement, and you MAY NOT distribute this Content or use it with any artificial intelligence model or tool.
Printed by Galya Basol Kochav on 12/28/2025 10:24:40 AM. Copyright © 2025 National Comprehensive Cancer Network, Inc. All Rights Reserved.

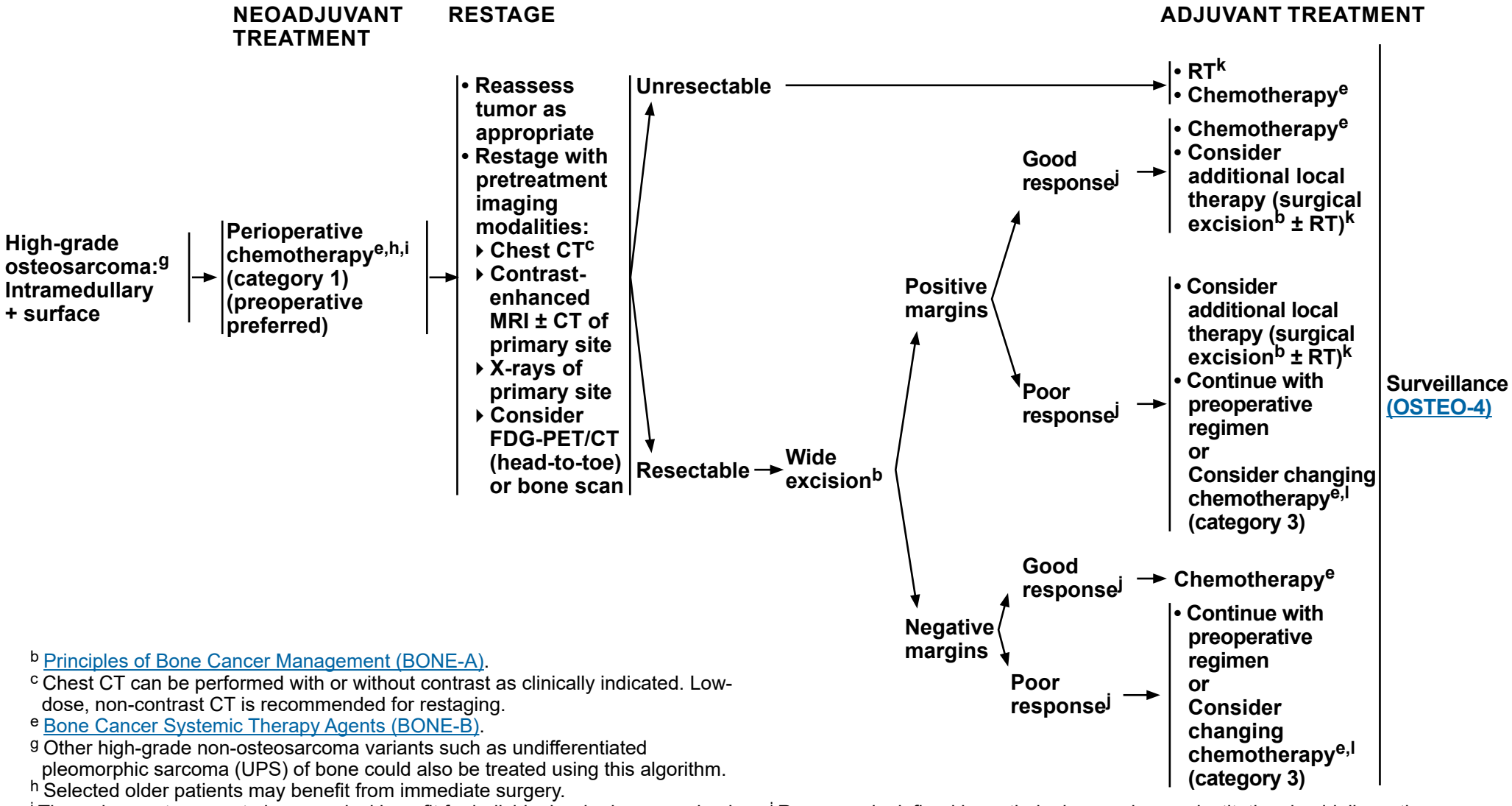

[b] Principles of Bone Cancer Management (BONE-A).
[c] Chest CT can be performed with or without contrast as clinically indicated. Low-dose, non-contrast CT is recommended for restaging.
[e] Bone Cancer Systemic Therapy Agents (BONE-B).
[g] Other high-grade non-osteosarcoma variants such as undifferentiated pleomorphic sarcoma (UPS) of bone could also be treated using this algorithm.
[h] Selected older patients may benefit from immediate surgery.
[i] There does not appear to be a survival benefit for individuals who have received neoadjuvant chemotherapy compared to adjuvant chemotherapy. Histologic response to neoadjuvant chemotherapy may provide prognostic information, but does not affect outcome. Bernthal NM, et al. Cancer 2012;118:5888-5893; Provisor AJ, et al. J Clin Oncol 1997;15:76-84.
[j] Response is defined by pathologic mapping per institutional guidelines; the amount of viable tumor is reported as <10% of the tumor area in cases showing a good response and ≥10% in cases showing a poor response.
[k] Principles of Radiation Therapy (BONE-C).
[l] See Discussion for further information.

Note: All recommendations are category 2A unless otherwise indicated.

Version 2.2026, 12/19/2025 © 2025 National Comprehensive Cancer Network® (NCCN®), All rights reserved. NCCN Guidelines® and this illustration may not be reproduced in any form without the express written permission of NCCN.

PLEASE NOTE that use of this NCCN Content is governed by the End-User License Agreement, and you MAY NOT distribute this Content or use it with any artificial intelligence model or tool.
Printed by Galya Basol Kochav on 12/28/2025 10:24:40 AM. Copyright © 2025 National Comprehensive Cancer Network, Inc. All Rights Reserved.

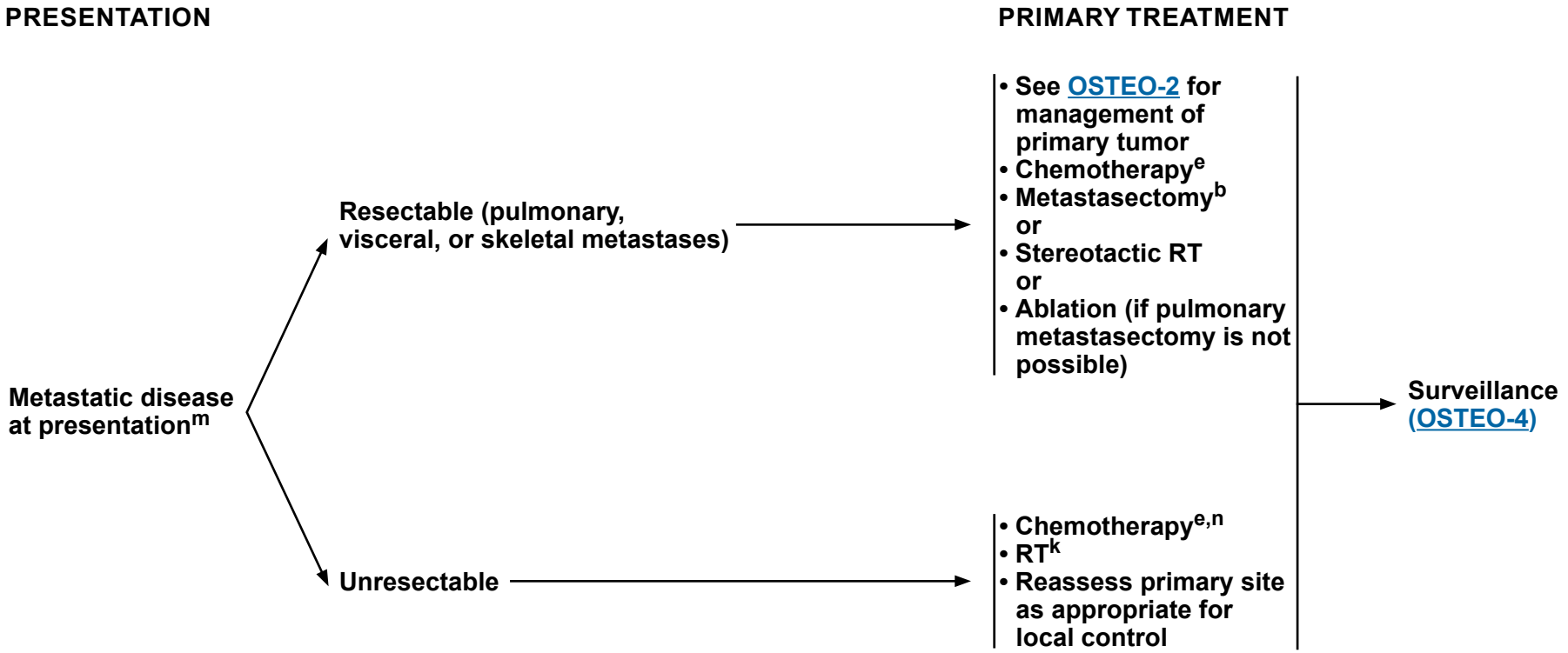

[b] Principles of Bone Cancer Management (BONE-A).
[e] Bone Cancer Systemic Therapy Agents (BONE-B).
[k] Principles of Radiation Therapy (BONE-C).
[m] Consider MGPT with a validated and/or FDA-approved assay to determine targeted therapy opportunities.
[n] Consider testing for TMB and MMR/MSI as determined by a validated and/or FDA-approved assay to inform treatment options.

Note: All recommendations are category 2A unless otherwise indicated.

Version 2.2026, 12/19/2025 © 2025 National Comprehensive Cancer Network® (NCCN®), All rights reserved. NCCN Guidelines® and this illustration may not be reproduced in any form without the express written permission of NCCN.

PLEASE NOTE that use of this NCCN Content is governed by the End-User License Agreement, and you MAY NOT distribute this Content or use it with any artificial intelligence model or tool.
Printed by Galya Basol Kochav on 12/28/2025 10:24:40 AM. Copyright © 2025 National Comprehensive Cancer Network, Inc. All Rights Reserved.

SURVEILLANCE

- Physical exam, imaging of primary site and chest[o]
- Follow-up schedule: (Orthopedic and oncologic)
  - Every 3 mo for y 1 and 2
  - Every 4 mo for y 3
  - Every 6 mo for y 4 and 5 and yearly thereafter, as clinically indicated
- CBC and other laboratory studies as clinically indicated
- Consider FDG-PET/CT (head-to-toe) and/or bone scan (category 2B)
- Reassess function every visit

RELAPSE

→ Relapse → Chemotherapy[e] and/or excision if possible →

Imaging to assess response:
- X-rays of primary site
- Contrast-enhanced CT ± MRI of local sites
- Chest CT[c]

→ Response → Surveillance

→ Relapse/Progression → Excision,[b] if possible
or
Clinical trial
or
RT[k,p]
or
Embolization/ablation
or
Best supportive care

[b] Principles of Bone Cancer Management (BONE-A).
[c] Chest CT can be performed with or without contrast as clinically indicated. Low-dose, non-contrast CT is recommended for restaging.
[e] Bone Cancer Systemic Therapy Agents (BONE-B).
[k] Principles of Radiation Therapy (BONE-C).
[o] Use the same imaging technique that was performed in the initial workup.
[p] May include radiopharmaceuticals, including radium-223.

Note: All recommendations are category 2A unless otherwise indicated.

Version 2.2026, 12/19/2025 © 2025 National Comprehensive Cancer Network® (NCCN®), All rights reserved. NCCN Guidelines® and this illustration may not be reproduced in any form without the express written permission of NCCN.

PLEASE NOTE that use of this NCCN Content is governed by the End-User License Agreement, and you MAY NOT distribute this Content or use it with any artificial intelligence model or tool.
Printed by Galya Basol Kochav on 12/28/2025 10:24:40 AM. Copyright © 2025 National Comprehensive Cancer Network, Inc. All Rights Reserved.

PRINCIPLES OF BONE CANCER MANAGEMENT

Biopsy
- Prior to biopsy, consultation should be obtained with an orthopedic oncologist regarding appropriate prebiopsy imaging.
- Preoperative biopsy consultation with a pediatric oncologist as appropriate is recommended for children.
- Biopsy diagnosis is necessary prior to any surgical procedure or fixation of primary site.
- Biopsy is optimally performed at a center that will do definitive management.
- Placement of biopsy is critical.
- Biopsy should be core needle or surgical biopsy.
- Technique: Apply same principles for core needle or open biopsy. Needle biopsy is not recommended for skull base tumors.
- Appropriate communication between the surgeon, musculoskeletal or interventional radiologist, and bone pathologist is critical.
- Fresh tissue may be needed for biomarker testing and tissue banking.
- In general, not following appropriate biopsy procedures may lead to adverse patient outcomes.

Surgery
- Wide excision should achieve histologically negative surgical margins.
- Negative surgical margins optimize local tumor control.
- Local tumor control may be achieved by either limb-sparing excision or limb amputation (individualized for a given patient).
- Limb-sparing excision is preferred to optimize function if reasonable functional expectations can be achieved.
- Final pathologic evaluation should include assessment of surgical margins, size/dimensions of tumor, and response to preoperative therapy.
- Fresh tissue may be needed for biomarker testing and tissue banking.

Laboratory Studies
- Laboratory studies such as CBC, LDH, and ALP may have relevance in the diagnosis, prognosis, and treatment of patients with bone sarcoma and should be done prior to definitive treatment and periodically during treatment and surveillance.
- Consider biomarker testing to delineate potential therapeutic options.

Treatment
- Fertility issues should be addressed with patients prior to commencing chemotherapy.
- See NCCN Guidelines for Adolescent and Young Adult (AYA) Oncology.
- Select patients with osteosarcoma or chondrosarcoma may benefit from a referral for genetic consultation and testing based on family history with a genetic predisposition for bone sarcomas.
- Care for patients with bone cancer should be delivered directly by physicians on the multidisciplinary team (category 1). See TEAM-1.

Long-Term Follow-up and Surveillance/Survivorship
- Patients should have a survivorship prescription to schedule follow-up with a multidisciplinary team.
- Life-long follow-up is recommended for surveillance and treatment of late effects of surgery, radiation, and chemotherapy in long-term survivors.
- See NCCN Guidelines for Survivorship.

Note: All recommendations are category 2A unless otherwise indicated.

Version 2.2026, 12/19/2025 © 2025 National Comprehensive Cancer Network® (NCCN®), All rights reserved. NCCN Guidelines® and this illustration may not be reproduced in any form without the express written permission of NCCN.

PLEASE NOTE that use of this NCCN Content is governed by the End-User License Agreement, and you MAY NOT distribute this Content or use it with any artificial intelligence model or tool.
Printed by Galya Basol Kochav on 12/28/2025 10:24:40 AM. Copyright © 2025 National Comprehensive Cancer Network, Inc. All Rights Reserved.

SYSTEMIC THERAPY AGENTS[a]

MSI-H/dMMR Tumors
Preferred • Pembrolizumab[1,2,b,c]
TMB-H (≥10 mutations/megabase) Tumors
Useful in Certain Circumstances • Pembrolizumab[3,4,c,d] • Ipilimumab + Nivolumab[5,d]

Chondrosarcoma	
Metastatic and widespread disease	**Other Recommended** • Dasatinib[6,7] • Pazopanib[8]
Conventional (Grades 1–3)	**Preferred** • No known standard chemotherapy options **Useful in Certain Circumstances** • Ivosidenib[9,d] (for susceptible *IDH1* mutations)
Dedifferentiated	**Preferred** • Consider osteosarcoma regimens (category 2B) **Useful in Certain Circumstances** • Ivosidenib[9,e] (for susceptible *IDH1* mutations) • Pazopanib[8] or Sunitinib[10] • Pembrolizumab[c,11] or Nivolumab[10,f] • Sunitinib + Nivolumab[10,f]
Mesenchymal	**Preferred** • Ewing sarcoma regimens (category 2B) • Doxorubicin[12-14,g] • Doxorubicin/Ifosfamide/Mesna[12-16,g]

[a] An FDA-approved biosimilar is an appropriate substitute for any recommended systemic biologic therapy in the NCCN Guidelines.
[b] Pembrolizumab is a systemic treatment option for adult and pediatric patients with unresectable or metastatic, MSI-high (MSI-H) or MMR deficient (dMMR) solid tumors that have progressed following prior treatment and who have no satisfactory alternative treatment options. Not for giant cell tumor of bone.
[c] Pembrolizumab and berahyaluronidase alfa-pmph subcutaneous injection may be substituted for IV pembrolizumab. Pembrolizumab and berahyaluronidase alfa-pmph has different dosing and administration instructions compared to IV pembrolizumab.
[d] Consider MGPT with a validated and/or FDA-approved assay to determine targeted therapy opportunities. TMB testing is recommended for patients with unresectable or metastatic tumors who have progressed following prior treatment and who have no satisfactory alternative treatment options. Not for giant cell tumor of bone.
[e] Testing for *IDH1* mutation can be performed by next-generation sequencing (NGS) or targeted exon sequencing.
[f] Nivolumab and hyaluronidase-nvhy subcutaneous injection may be substituted for IV nivolumab. Nivolumab and hyaluronidase-nvhy has different dosing and administration instructions compared to IV nivolumab.
[g] Dactinomycin can be substituted for doxorubicin for concerns regarding cardiotoxicity.

References

Note: All recommendations are category 2A unless otherwise indicated.

Version 2.2026, 12/19/2025 © 2025 National Comprehensive Cancer Network® (NCCN®), All rights reserved. NCCN Guidelines® and this illustration may not be reproduced in any form without the express written permission of NCCN.

PLEASE NOTE that use of this NCCN Content is governed by the End-User License Agreement, and you MAY NOT distribute this Content or use it with any artificial intelligence model or tool.
Printed by Galya Basol Kochav on 12/28/2025 10:24:40 AM. Copyright © 2025 National Comprehensive Cancer Network, Inc. All Rights Reserved.

SYSTEMIC THERAPY AGENTS[a]

Chordoma	
Other Recommended • Imatinib[17,18,19] • Dasatinib[6,7] • Pembrolizumab[20,c] • Sunitinib[21]	**Useful in Certain Circumstances** • Cisplatin/Imatinib[22] • Imatinib/Sirolimus[23] • Erlotinib[24] • Lapatinib for EGFR-positive chordomas[25] • Sorafenib[26,27]

[a] An FDA-approved biosimilar is an appropriate substitute for any recommended systemic biologic therapy in the NCCN Guidelines.
[c] Pembrolizumab and berahyaluronidase alfa-pmph subcutaneous injection may be substituted for IV pembrolizumab. Pembrolizumab and berahyaluronidase alfa-pmph has different dosing and administration instructions compared to IV pembrolizumab.

References

Note: All recommendations are category 2A unless otherwise indicated.

Version 2.2026, 12/19/2025 © 2025 National Comprehensive Cancer Network® (NCCN®), All rights reserved. NCCN Guidelines® and this illustration may not be reproduced in any form without the express written permission of NCCN.

PLEASE NOTE that use of this NCCN Content is governed by the End-User License Agreement, and you MAY NOT distribute this Content or use it with any artificial intelligence model or tool.
Printed by Galya Basol Kochav on 12/28/2025 10:24:40 AM. Copyright © 2025 National Comprehensive Cancer Network, Inc. All Rights Reserved.

SYSTEMIC THERAPY AGENTS[a]

Ewing Sarcoma[h]			
First-line therapy (primary/ neoadjuvant/adjuvant therapy)[g]	Preferred • VDC-IE (Vincristine/Doxorubicin/ Cyclophosphamide/ Mesna-Ifosfamide/Mesna/ Etoposide)[28,29,i] (category 1)	Other Recommended • VAIA (Vincristine/Doxorubicin/Ifosfamide/Mesna/ Dactinomycin)[30,31,33] • VIDE (Vincristine/Ifosfamide/Mesna/Doxorubicin/Etoposide)[32,33]	
Primary therapy for metastatic disease at initial presentation[g]	Preferred • VAIA[30,31] • VDC (Vincristine/Doxorubicin/Cyclophosphamide)[34] • VDC-IE[28] • VIDE[32]		
Second-line therapy (relapsed/ refractory or metastatic disease)	Preferred • Cyclophosphamide/ Topotecan[35-38,j] • Irinotecan/Temozolomide[39-44] • Irinotecan/Temozolomide/ Vincristine[39-44]	Other Recommended • Cabozantinib[45] • Docetaxel/Gemcitabine[46,j] • High-Dose Ifosfamide/Mesna[47] • Regorafenib[48]	Useful in Certain Circumstances • ICE (Ifosfamide/Mesna/ Carboplatin/Etoposide)[49,j] • Lurbinectedin[50,k] (category 2B)

[a] An FDA-approved biosimilar is an appropriate substitute for any recommended systemic biologic therapy in the NCCN Guidelines.
[g] Dactinomycin can be substituted for doxorubicin for concerns regarding cardiotoxicity.
[h] Other primary round cell tumors of bone (eg, *CIC::DUX4, BCOR::CCNB3*) can be treated like Ewing sarcoma.
[i] In patients <18 years, evidence supports 2-week compressed treatment.
[j] Vincristine could be added to these regimens.
[k] Myelosuppression was reversible and primary granulocyte colony-stimulating factor (G-CSF) prophylaxis may be considered during lurbinectedin treatment (category 2B).

References

Note: All recommendations are category 2A unless otherwise indicated.

Version 2.2026, 12/19/2025 © 2025 National Comprehensive Cancer Network® (NCCN®), All rights reserved. NCCN Guidelines® and this illustration may not be reproduced in any form without the express written permission of NCCN.

PLEASE NOTE that use of this NCCN Content is governed by the End-User License Agreement, and you MAY NOT distribute this Content or use it with any artificial intelligence model or tool.
Printed by Galya Basol Kochav on 12/28/2025 10:24:40 AM. Copyright © 2025 National Comprehensive Cancer Network, Inc. All Rights Reserved.

SYSTEMIC THERAPY AGENTS[a]

Giant Cell Tumor of Bone
Preferred • Denosumab[51-55]

Osteosarcoma			
First-line therapy (primary/ neoadjuvant/adjuvant therapy or metastatic disease)[g]	**Preferred** • Cisplatin/Doxorubicin[56-58] (category 1) • MAP (High-Dose Methotrexate/ Leucovorin/Doxorubicin/ Cisplatin)[58-61] (category 1)[l,m]	**Other Recommended** • Cisplatin/Doxorubicin/Ifosfamide/Mesna/High-Dose Methotrexate/ Leucovorin[66,l]	
Second-line therapy (relapsed/ refractory or metastatic disease)	**Preferred** • Etoposide/High-Dose Ifosfamide/Mesna[62,63] • High-Dose Ifosfamide/ Mesna[62,63] • Regorafenib[64] (category 1) • Sorafenib[65]	**Other Recommended** • Cabozantinib[45] • Cyclophosphamide/ Topotecan[37,38] • Docetaxel/Gemcitabine[46,67] • Gemcitabine[67] • Everolimus/Sorafenib (category 2B)[68]	**Useful in Certain Circumstances** • Cyclophosphamide/Mesna/ Etoposide[69] • ICE[49] • High-Dose Methotrexate/ Leucovorin - Etoposide/ Ifosfamide/Mesna[70,l] • High-Dose Methotrexate/ Leucovorin[l] • Radiopharmaceuticals including radium-223 for relapsed or refractory disease beyond second-line therapy[71]

High-Grade Undifferentiated Pleomorphic Sarcoma (UPS)
Follow osteosarcoma regimens (category 2B)

[a] An FDA-approved biosimilar is an appropriate substitute for any recommended systemic biologic therapy in the NCCN Guidelines.
[g] Dactinomycin can be substituted for doxorubicin for concerns regarding cardiotoxicity.
[l] In the event a patient receiving high-dose methotrexate experiences delayed elimination due to renal impairment, glucarpidase is strongly recommended. See glucarpidase prescribing information for more information.
[m] MAP is preferred in patients <40 years with excellent performance status.

References

Note: All recommendations are category 2A unless otherwise indicated.

Version 2.2026, 12/19/2025 © 2025 National Comprehensive Cancer Network® (NCCN®), All rights reserved. NCCN Guidelines® and this illustration may not be reproduced in any form without the express written permission of NCCN.

PLEASE NOTE that use of this NCCN Content is governed by the End-User License Agreement, and you MAY NOT distribute this Content or use it with any artificial intelligence model or tool.
Printed by Galya Basol Kochav on 12/28/2025 10:24:40 AM. Copyright © 2025 National Comprehensive Cancer Network, Inc. All Rights Reserved.

BONE CANCER SYSTEMIC THERAPY AGENTS REFERENCES

[1] Marabelle A, Le DT, Ascierto PA, et al. Efficacy of pembrolizumab in patients with noncolorectal high microsatellite instability/mismatch repair-deficient cancer: results from the phase II KEYNOTE-158 study. J Clin Oncol 2019;38:1-10.
[2] Lala M, Li TR, De Alwis DP, et al. A six-weekly dosing schedule for pembrolizumab in patients with cancer based on evaluation using modelling and simulation. Eur J Cancer 2020;131:68-75.
[3] Marabelle A, Fakih M, Lopez J, et al. Association of tumour mutational burden with outcomes in patients with advanced solid tumours treated with pembrolizumab: Prospective biomarker analysis of the multicohort, open-label, phase 2 KEYNOTE-158 study. Lancet Oncol 2020;21:1353-1365.
[4] Merino DM, McShane LM, Fabrizio D, et al. Establishing guidelines to harmonize tumor mutational burden (TMB): In silico assessment of variation in TMB quantification across diagnostic platforms: phase I of the Friends of Cancer Research TMB Harmonization Project. J Immunother Cancer 2020;8:e000147.
[5] Schenker M, Burotto M, Richardet M, et al. Randomized, open-label, phase 2 study of nivolumab plus ipilimumab or nivolumab monotherapy in patients with advanced or metastatic solid tumors of high tumor mutational burden. J Immunother Cancer 2024;12:e008872.
[6] Schuetze SM, Bolejack V, Choy E, et al. Phase 2 study of dasatinib in patients with alveolar soft part sarcoma, chondrosarcoma, chordoma, epithelioid sarcoma, or solitary fibrous tumor. Cancer 2017;123:90-97.
[7] Villalobos VM, Hoffner B, Elias AD. We can study ultrarare tumors effectively in this day and age, it just takes a cooperative approach: The role of dasatinib in assorted indolent sarcomas. Cancer 2017;123:20-24.
[8] Chow W, Frankel P, Ruel C, et al. Results of a prospective phase 2 study of pazopanib in patients with surgically unresectable or metastatic chondrosarcoma. Cancer 2020;126:105-111.
[9] Tap WD, Villalobos VM, Cote GM, et al. Phase I study of the mutant IDH1 inhibitor ivosidenib: safety and clinical activity in patients with advanced chondrosarcoma. J Clin Oncol 2020;38:1693-1701.
[10] Palmerini E, Lopez Pousa A, Grignani G, et al. Nivolumab and sunitinib in patients with advanced bone sarcomas: a multicenter, single-arm, phase 2 trial. Cancer 2025;131:e35628.
[11] Tawbi HA, Burgess M, Bolejack V, et al. Pembrolizumab in advanced soft-tissue sarcoma and bone sarcoma (SARC028): a multicentre, two-cohort, single-arm, open-label, phase 2 trial. Lancet Oncol 2017;18:1493-1501.
[12] Frezza AM, Cesari M, Baumhoer D, et al. Mesenchymal chondrosarcoma: Prognostic factors and outcome in 113 patients. A European Musculoskeletal Oncology Society study. Eur J Cancer 2015;51:374-381.
[13] van Maldegem A, Conley AP, Rutkowski P, et al. Outcome of first-line systemic treatment for unresectable conventional, dedifferentiated, mesenchymal, and clear cell chondrosarcoma. Oncologist 2018;24:110-116.
[14] Italiano A, Mir O, Cioffi A, et al. Advanced chondrosarcomas: Role of chemotherapy and survival. Ann Oncol 2013;24:2916-2922.
[15] Strach MC, Grimison PS, Hong A, et al. Mesenchymal chondrosarcoma: An Australian multi-centre cohort study. Cancer Med 2023;12:368-378.
[16] Bishop MW, Somerville JM, Bahrami A, et al. Mesenchymal chondrosarcoma in children and young adults: A single institution retrospective review. Sarcoma 2015;2015:608279.
[17] Geoerger B, Morland B, Ndiaye A, et al. Target-driven exploratory study of imatinib mesylate in children with solid malignancies by the Innovative Therapies for Children with Cancer (ITCC) European Consortium. Eur J Cancer 2009;45:2342-2351.
[18] Casali PG, Messina A, Stacchiotti S, et al. Imatinib mesylate in chordoma. Cancer 2004;101:2086-2097.
[19] Stacchiotti S, Longhi A, Ferraresi V, et al. Phase II study of imatinib in advanced chordoma. J Clin Oncol 2012;30:914-920.
[20] Blay JY, Chevret S, Le Cesne A, et al. Pembrolizumab in patients with rare and ultra-rare sarcomas (AcSé Pembrolizumab): Analysis of a subgroup from a non-randomised, open-label, phase 2, basket trial. Lancet Oncol 2023;24:892-902.
[21] George S, Merriam P, Maki RG, et al. Multicenter phase II trial of sunitinib in the treatment of nongastrointestinal stromal tumor sarcomas. J Clin Oncol 2009;27:3154-3160.
[22] Casali PG, Stacchiotti S, Grosso F, et al. Adding cisplatin (CDDP) to imatinib (IM) re-establishes tumor response following secondary resistance to IM in advanced chordoma [abstract]. J Clin Oncol 2007;25(Suppl): Abstract 10038.
[23] Stacchiotti S, Marrari A, Tamborini E, et al. Response to imatinib plus sirolimus in advanced chordoma. Ann Oncol 2009;20:1886-1894.
[24] Singhal N, Kotasek D, Parnis FX. Response to erlotinib in a patient with treatment refractory chordoma. Anticancer Drugs 2009;20:953-955.
[25] Stacchiotti S, Tamborini E, LoVullo S, et al. Phase II study on lapatinib in advanced EGFR-positive chordoma. Ann Oncol 2013;24:1931-1936.
[26] Amela E, Bompas E, Le Cesne A, et al. A phase II trial of sorafenib (SO) in advanced chordoma patients (pt) [abstract]. J Clin Oncol 2015;33(Suppl):Abstract 10520.
[27] Bompas E, Le Cesne A, Tresch-Bruneel E, et al. Sorafenib in patients with locally advanced and metastatic chordomas: a phase II trial of the French Sarcoma Group (GSF/GETO). Ann Oncol 2015;10:2168-2173.

Continued

Note: All recommendations are category 2A unless otherwise indicated.

Version 2.2026, 12/19/2025 © 2025 National Comprehensive Cancer Network® (NCCN®), All rights reserved. NCCN Guidelines® and this illustration may not be reproduced in any form without the express written permission of NCCN.

PLEASE NOTE that use of this NCCN Content is governed by the End-User License Agreement, and you MAY NOT distribute this Content or use it with any artificial intelligence model or tool.
Printed by Galya Basol Kochav on 12/28/2025 10:24:40 AM. Copyright © 2025 National Comprehensive Cancer Network, Inc. All Rights Reserved.

BONE CANCER SYSTEMIC THERAPY AGENTS REFERENCES

[28] Grier HE, Krailo MD, Tarbell NJ, et al. Addition of ifosfamide and etoposide to standard chemotherapy for Ewing's sarcoma and primitive neuroectodermal tumor of bone. N Engl J Med 2003;348:694-701.
[29] Womer RB, West DC, Krailo MD, et al. Randomized controlled trial of interval-compressed chemotherapy for the treatment of localized Ewing sarcoma: A report from the Children's Oncology Group. J Clin Oncol 2012;30:4148-4154.
[30] Paulussen M, Ahrens S, Dunst J, et al. Localized Ewing tumor of bone: final results of the cooperative Ewing's Sarcoma Study CESS 86. J Clin Oncol 2001;19:1818-1829.
[31] Paulussen M, Craft AW, Lewis I, et al. Results of the EICESS-92 Study: two randomized trials of Ewing's sarcoma treatment--cyclophosphamide compared with ifosfamide in standard-risk patients and assessment of benefit of etoposide added to standard treatment in high-risk patients. J Clin Oncol 2008;26:4385-4393.
[32] Brennan B, Kirton L, Marec-Berard P, et al. Comparison of two chemotherapy regimens in Ewing sarcoma (ES): Overall and subgroup results of the Euro Ewing 2012 randomized trial (EE2012) [abstract]. J Clin Oncol 2020;38(Suppl):Abstract 11500.
[33] Albergo JI, Gaston CL, Laitinen M, et al. Ewing's sarcoma: only patients with 100% of necrosis after chemotherapy should be classified as having a good response. Bone Joint J 2016;98-B:1138-1144.
[34] Miser JS, Krailo MD, Tarbell NJ, et al. Treatment of metastatic Ewing's sarcoma or primitive neuroectodermal tumor of bone: evaluation of combination ifosfamide and etoposide--a Children's Cancer Group and Pediatric Oncology Group study. J Clin Oncol 2004;22:2873-2876.
[35] Bernstein ML, Devidas M, Lafreniere D, et al. Intensive therapy with growth factor support for patients with Ewing tumor metastatic at diagnosis: Pediatric Oncology Group/Children's Cancer Group Phase II Study 9457--a report from the Children's Oncology Group. J Clin Oncol 2006;24:152-159.
[36] Hunold A, Weddeling N, Paulussen M, et al. Topotecan and cyclophosphamide in patients with refractory or relapsed Ewing tumors. Pediatr Blood Cancer 2006;47:795-800.
[37] Kushner BH, Kramer K, Meyers PA, et al. Pilot study of topotecan and high-dose cyclophosphamide for resistant pediatric solid tumors. Med Pediatr Oncol 2000;35:468-474.
[38] Saylors RL 3rd, Stine KC, Sullivan J, et al. Cyclophosphamide plus topotecan in children with recurrent or refractory solid tumors: a Pediatric Oncology Group phase II study. J Clin Oncol 2001;19:3463-3469.
[39] Casey DA, Wexler LH, Merchant MS, et al. Irinotecan and temozolomide for Ewing sarcoma: the Memorial Sloan-Kettering experience. Pediatr Blood Cancer 2009;53:1029-1034.
[40] Wagner LM, McAllister N, Goldsby RE, et al. Temozolomide and intravenous irinotecan for treatment of advanced Ewing sarcoma. Pediatr Blood Cancer 2007;48:132-139.
[41] McNall-Knapp RY, Williams CN, Reeves EN, et al. Extended phase I evaluation of vincristine, irinotecan, temozolomide, and antibiotic in children with refractory solid tumors. Pediatr Blood Cancer 2010;54:909-915.
[42] Reed DR, Hayashi M, Wagner L, et al. Treatment pathway of bone sarcoma in children, adolescents, and young adults. Cancer 2017;123:2206-2218.
[43] Raciborska A, Bilska K, Drabko K, et al. Vincristine, irinotecan, and temozolomide in patients with relapsed and refractory Ewing sarcoma. Pediatr Blood Cancer 2013;60:1621-1625.
[44] Wagner LM, Perentesis JP, Reid JM, et al. Phase I trial of two schedules of vincristine, oral irinotecan, and temozolomide (VOIT) for children with relapsed or refractory solid tumors: a Children's Oncology Group phase I consortium study. Pediatr Blood Cancer 2010;54:538-545.
[45] Italiano A, Mir O, Mathoulin-Pelissier S, et al. Cabozantinib in patients with advanced Ewing sarcoma or osteosarcoma (CABONE): a multicentre, single-arm, phase 2 trial. Lancet Oncol 2020;21:446-455.
[46] Navid F, Willert JR, McCarville MB, et al. Combination of gemcitabine and docetaxel in the treatment of children and young adults with refractory bone sarcoma. Cancer 2008;113:419-425.
[47] McCabe M, Kirton L, Khan M, et al. Phase III assessment of topotecan and cyclophosphamide and high-dose ifosfamide in rEECur: An international randomized controlled trial of chemotherapy for the treatment of recurrent and primary refractory Ewing sarcoma (RR-ES) [abstract]. J Clin Oncol 2022;40(Suppl):Abstract LBA2.
[48] Attia S, Bolejack V, Ganjoo K, et al. A phase II trial of regorafenib in patients with advanced Ewing sarcoma and related tumors of soft tissue and bone: SARC024 trial results. Cancer Med 2023;12:1532-1539.

Note: All recommendations are category 2A unless otherwise indicated.

Continued

Version 2.2026, 12/19/2025 © 2025 National Comprehensive Cancer Network® (NCCN®), All rights reserved. NCCN Guidelines® and this illustration may not be reproduced in any form without the express written permission of NCCN.

PLEASE NOTE that use of this NCCN Content is governed by the End-User License Agreement, and you MAY NOT distribute this Content or use it with any artificial intelligence model or tool.
Printed by Galya Basol Kochav on 12/28/2025 10:24:40 AM. Copyright © 2025 National Comprehensive Cancer Network, Inc. All Rights Reserved.

BONE CANCER SYSTEMIC THERAPY AGENTS REFERENCES

[49] Van Winkle P, Angiolillo A, Krailo M, et al. Ifosfamide, carboplatin, and etoposide (ICE) reinduction chemotherapy in a large cohort of children and adolescents with recurrent/refractory sarcoma: the Children's Cancer Group (CCG) experience. Pediatr Blood Cancer 2005;44:338-347.
[50] Subbiah V, Brana I, Longhi A, et al. Antitumor activity of lurbinectedin, a selective inhibitor or oncogene transcription, in patients with relapsed Ewing sarcoma: results of a basket phase II study. Clin Cancer Res 2022;28:2762-2770.
[51] Branstetter DG, Nelson SD, Manivel JC, et al. Denosumab induces tumor reduction and bone formation in patients with giant-cell tumor of bone. Clin Cancer Res 2012;18:4415-4424.
[52] Thomas D, Henshaw R, Skubitz K, et al. Denosumab in patients with giant-cell tumour of bone: an open-label, phase 2 study. Lancet Oncol 2010;11:275-280.
[53] Tsukamoto S, Tanaka Y, Mavrogenis AF, et al. Is treatment with denosumab associated with local recurrence in patients with giant cell tumor of bone treated with curettage? A systematic review. Clin Orthop Relat Res 2020;478:1076-1085.
[54] Hindiskere S, Errani C, Doddarangappa S, et al. Is a short-course of preoperative denosumab as effective as prolonged therapy for giant cell tumor of bone? Clin Orthop Relat Res 2020;478:2522-2533.
[55] Perrin DL, Visgauss JD, Wilson DA, et al. The role of Denosumab in joint preservation for patients with giant cell tumour of bone. Bone Joint J 2021;103-B:184-191.
[56] Bramwell V, Burgers M, Sneath R, et al. A comparison of two short intensive adjuvant chemotherapy regimens in operable osteosarcoma of limbs in children and young adults: the first study of the European Osteosarcoma Intergroup. J Clin Oncol 1992;10:1579-1591.
[57] Lewis IJ, Nooij MA, Whelan J, et al. Improvement in histologic response but not survival in osteosarcoma patients treated with intensified chemotherapy: a randomized phase III trial of the European Osteosarcoma Intergroup. J Natl Cancer Inst 2007;99:112-128.
[58] Souhami RL, Craft AW, Van der Eijken JW, et al. Randomised trial of two regimens of chemotherapy in operable osteosarcoma: a study of the European Osteosarcoma Intergroup. Lancet 1997;350:911-917.
[59] Bacci G, Ferrari S, Bertoni F, et al. Long-term outcome for patients with nonmetastatic osteosarcoma of the extremity treated at the istituto ortopedico rizzoli according to the istituto ortopedico rizzoli/osteosarcoma-2 protocol: an updated report. J Clin Oncol 2000;18:4016-4027.
[60] Winkler K, Beron G, Delling G, et al. Neoadjuvant chemotherapy of osteosarcoma: results of a randomized cooperative trial (COSS-82) with salvage chemotherapy based on histological tumor response. J Clin Oncol 1988;6:329-337.
[61] Marina NM, Smeland S, Bielack SS, et al. Comparison of MAPIE versus MAP in patients with a poor response to preoperative chemotherapy for newly diagnosed high-grade osteosarcoma (EUARMOS-1): an open-label, international, randomized controlled trial. Lancet Oncol 2016;17:1396-1408.
[62] Magnan H, Goodbody CM, Riedel E, et al. Ifosfamide dose-intensification for patients with metastatic Ewing sarcoma. Pediatr Blood Cancer 2015;62:594-597.
[63] Goorin AM, Harris MB, Bernstein M, et al. Phase II/III trial of etoposide and high-dose ifosfamide in newly diagnosed metastatic osteosarcoma: a pediatric oncology group trial. J Clin Oncol 2002;20:426-433.
[64] Davis LE, Bolejack V, Ryan CW, et al. Randomized double-blind phase II study of regorafenib in patients with metastatic osteosarcoma. J Clin Oncol 2019;37:1424-1431.
[65] Grignani G, Palmerini E, Dileo P, et al. A phase II trial of sorafenib in relapsed and unresectable high-grade osteosarcoma after failure of standard multimodal therapy: an Italian Sarcoma Group study. Ann Oncol 2012; 23:508-516.
[66] Bacci G, Briccoli A, Rocca M, et al. Neoadjuvant chemotherapy for osteosarcoma of the extremities with metastases at presentation: recent experience at the Rizzoli Institute in 57 patients treated with cisplatin, doxorubicin, and a high dose of methotrexate and ifosfamide. Ann Oncol 2003;14:1126-1134.
[67] Maki RG, Wathen JK, Patel SR, et al. Randomized phase II study of gemcitabine and docetaxel compared with gemcitabine alone in patients with metastatic soft tissue sarcomas: Results of sarcoma alliance for research through collaboration study 002. J Clin Oncol 2007;25:2755-2763.
[68] Grignani G, Palmerini E, Ferraresi V, et al. Sorafenib and everolimus for patients with unresectable high-grade osteosarcoma progressing after standard treatment: A non-randomised phase 2 clinical trial. Lancet Oncol 2015;16:98-107.
[69] Berger M, Grignani G, Ferrari S, et al. Phase 2 trial of two courses of cyclophosphamide and etoposide for relapsed high-risk osteosarcoma patients. Cancer 2009;115:2980-2987.
[70] Le Deley MC, Guinebretiere JM, Gentet JC, et al. SFOP OS94: A randomised trial comparing preoperative high-dose methotrexate plus doxorubicin to high-dose methotrexate plus etoposide and ifosfamide in osteosarcoma patients. Eur J Cancer 2007;43:752-761.
[71] Subbiah V, Anderson PM, Kairemo K, et al. Alpha particle radium 223 dichloride in high-risk osteosarcoma: A phase I dose escalation trial. Clin Cancer Res 2019;25:3802-3810.

Note: All recommendations are category 2A unless otherwise indicated.

Version 2.2026, 12/19/2025 © 2025 National Comprehensive Cancer Network® (NCCN®), All rights reserved. NCCN Guidelines® and this illustration may not be reproduced in any form without the express written permission of NCCN.

PLEASE NOTE that use of this NCCN Content is governed by the End-User License Agreement, and you MAY NOT distribute this Content or use it with any artificial intelligence model or tool.
Printed by Galya Basol Kochav on 12/28/2025 10:24:40 AM. Copyright © 2025 National Comprehensive Cancer Network, Inc. All Rights Reserved.

PRINCIPLES OF RADIATION THERAPY

General Principles

- **Patients should be strongly encouraged to have RT at the same specialized center that is providing surgical and systemic interventions.**
- **Specialized techniques such as intensity-modulated RT (IMRT); particle beam RT with protons, carbon ions, or other heavy ions; or stereotactic radiosurgery (SRS) should be considered as indicated in order to allow high-dose therapy while maximizing normal tissue sparing.**
- **The RT doses listed below for chondrosarcoma and chordoma are for conventional fractionated regimens (1.8–2.0 Gy). Alternative total dose and fractionation schemes are necessary for specialized techniques such as SRS and stereotactic body RT (SBRT).**

General Treatment and Dosing Information - Chondrosarcoma

Dosing Prescription Regimen

- **Low-grade extracompartmental appendicular or grade I axial tumors**
  - **Unresectable:**
    - ◊ **Consider RT (70 Gy) with specialized techniques.**

- **High-grade, clear cell, or extracompartmental**
  - **Resectable:**
    - ◊ **Preoperative RT: Consider if positive margins are likely (19.8–50.4 Gy) followed by individualized postoperative RT with final target dose of 70 Gy for microscopically positive margins and 72–78 Gy for gross positive margins.**
    - ◊ **Postoperative RT: Consider, especially for high-grade/dedifferentiated subtype, 70 Gy for microscopically positive margins and >70 Gy for gross positive margins using specialized techniques.**
    - ◊ **Radiation is not needed for negative margins; there should be no pre- or postoperative considerations.**
  - **Unresectable:**
    - ◊ **Consider RT (>70 Gy) with specialized techniques.**

Note: All recommendations are category 2A unless otherwise indicated.

Continued
References

Version 2.2026, 12/19/2025 © 2025 National Comprehensive Cancer Network® (NCCN®), All rights reserved. NCCN Guidelines® and this illustration may not be reproduced in any form without the express written permission of NCCN.

PLEASE NOTE that use of this NCCN Content is governed by the End-User License Agreement, and you MAY NOT distribute this Content or use it with any artificial intelligence model or tool.
Printed by Galya Basol Kochav on 12/28/2025 10:24:40 AM. Copyright © 2025 National Comprehensive Cancer Network, Inc. All Rights Reserved.

PRINCIPLES OF RADIATION THERAPY

General Treatment and Dosing Information - Chordoma

Dosing Prescription Regimen

- **Extracranial (mobile spine/sacrum)**
  - **Resectable:**
    - ◊ **Preoperative RT: Consider if positive margins are likely (19.8–50.4 Gy) followed by individualized postoperative RT.**
- **Postoperative RT: Consider postoperative RT for microscopically positive margins/gross positive margins using specialized techniques with final target dose of 70 Gy for microscopically positive margins and 72–78 Gy for gross positive margins.**
  - **Unresectable:**
    - ◊ **Consider RT (>70 Gy) using specialized techniques.**

- **Cranial (base of skull)**
  - **Resectable:**
    - ◊ **Preoperative RT: Consider if positive margins are likely (19.8–50.4 Gy) followed by individualized postoperative RT.**
    - ◊ **Consider postoperative RT (>70 Gy) for microscopically positive margins/gross positive margins using specialized techniques.**
  - **Unresectable:**
    - ◊ **Consider RT (>70 Gy) using specialized techniques.**

Note: All recommendations are category 2A unless otherwise indicated.

Continued
References

Version 2.2026, 12/19/2025 © 2025 National Comprehensive Cancer Network® (NCCN®), All rights reserved. NCCN Guidelines® and this illustration may not be reproduced in any form without the express written permission of NCCN.

PLEASE NOTE that use of this NCCN Content is governed by the End-User License Agreement, and you MAY NOT distribute this Content or use it with any artificial intelligence model or tool.
Printed by Galya Basol Kochav on 12/28/2025 10:24:40 AM. Copyright © 2025 National Comprehensive Cancer Network, Inc. All Rights Reserved.

PRINCIPLES OF RADIATION THERAPY

General Treatment and Dosing Information - Ewing Sarcoma

Treatment of Primary Tumor/Dosing Prescription Regimen

- Definitive RT
  - Should start by week 12 of VDC/IE chemotherapy or week 18 of VIDE and is given concurrently with chemotherapy, withholding anthracyclines during RT per the Womer Protocol
  - Treatment volumes and doses:
    - ◊ 45 Gy to initial gross tumor volume (GTV1) + 1–1.5 cm for clinical target volume 1 (CTV1) + 0.5–1 cm for planning target volume 1 (PTV1)
      - – GTV1 is defined as pre-treatment extent of bone and soft tissue disease. If the tumor has responded to chemotherapy and normal tissues have returned to their natural position, GTV1 should exclude pre-chemotherapy soft tissue volume that extended into a cavity (eg, tumors indenting lung, intestine, or bladder resume normal position following chemotherapy)
    - ◊ Cone-down (CD) to cover original bony extent to a total of 55.8 Gy to post-chemotherapy soft tissue volume (GTV2) + 1–1.5 cm for CTV2 + 0.5–1 cm for PTV2 (consider dose escalation for select patients)
- Preoperative RT
  - May be considered for marginally resectable tumors and is given concurrently with chemotherapy
  - Treatment volumes and doses:
    - ◊ 36–45 Gy for initial GTV + 2 cm
- Postoperative RT
  - Should begin within 60 days of surgery and is given concurrently with chemotherapy
  - Treatment volumes and doses:
    - ◊ Negative margins: Consider treatment for poor histologic response even if margins are adequate (45 Gy to GTV2 equivalent volume + 1–1.5 cm for CTV1 + 0.5–1 cm for PTV1)
    - ◊ Microscopically positive margins: 45 Gy GTV2 equivalent volume + 1–1.5 cm for CTV1 + 0.5–1 cm for PTV1
    - ◊ Gross positive margins: 45 Gy to GTV2 equivalent volume + 1–1.5 cm for CTV1 + 0.5–1 cm for PTV1 followed by CD to residual disease plus a total of 55.8 Gy to GTV2 + 1–1.5 cm for CTV2 + 0.5–1 cm for PTV2

Hemithorax Irradiation

- Should be considered for chest wall primaries with extensive ipsilateral pleural involvement
- 15–20 Gy (1.5 Gy/fraction) followed by CD to primary site (final dose based on resection margins)

Treatment of Metastatic Disease

- Consider WLI for pulmonary metastases following completion of chemotherapy/metastasectomy (category 3)
  - 15 Gy (1.5 Gy/fraction) for patients <14 years
  - 18 Gy (1.5 Gy/fraction) for patients >14 years
- Current Children's Oncology Group (COG) study stratifies age before or after 6 years (12 vs. 15 Gy)
- Consider use of SRS/SBRT, especially for oligometastases

Note: All recommendations are category 2A unless otherwise indicated.

Continued
References

Version 2.2026, 12/19/2025 © 2025 National Comprehensive Cancer Network® (NCCN®), All rights reserved. NCCN Guidelines® and this illustration may not be reproduced in any form without the express written permission of NCCN.

PLEASE NOTE that use of this NCCN Content is governed by the End-User License Agreement, and you MAY NOT distribute this Content or use it with any artificial intelligence model or tool.
Printed by Galya Basol Kochav on 12/28/2025 10:24:40 AM. Copyright © 2025 National Comprehensive Cancer Network, Inc. All Rights Reserved.

PRINCIPLES OF RADIATION THERAPY

General Treatment and Dosing Information - Giant Cell Tumor of Bone

Treatment of Primary Site or Metastatic Disease/Dosing Prescription Regimen
- **Consider RT (50–60 Gy) for unresectable/progressive/recurrent disease that has not responded to denosumab, serial embolizations, or other treatments.**
- **An increased risk of malignant transformation following RT has been noted in some studies.**

General Treatment and Dosing Information - Osteosarcoma

Treatment of Primary Tumor/Dosing Prescription Regimen
- **Consider RT for microscopically positive margins or gross positive margins or unresectable disease.**
- **Postoperative RT (microscopically and gross positive margins):55 Gy with 9–13 Gy boost to microscopic or gross disease (total dose to high-risk sites 64–68 Gy)**
- **Unresectable disease: 60–70 Gy (total dose will depend on normal tissue tolerance)**

Treatment of Metastatic Disease
- **Consider use of radiopharmaceuticals, including radium-223.**
- **Consider use of SRS/SBRT, especially for oligometastases.**

References

Note: All recommendations are category 2A unless otherwise indicated.

Version 2.2026, 12/19/2025 © 2025 National Comprehensive Cancer Network® (NCCN®), All rights reserved. NCCN Guidelines® and this illustration may not be reproduced in any form without the express written permission of NCCN.

PLEASE NOTE that use of this NCCN Content is governed by the End-User License Agreement, and you MAY NOT distribute this Content or use it with any artificial intelligence model or tool.
Printed by Galya Basol Kochav on 12/28/2025 10:24:40 AM. Copyright © 2025 National Comprehensive Cancer Network, Inc. All Rights Reserved.

PRINCIPLES OF RADIATION THERAPY
REFERENCES

Chondrosarcoma
Amichetti M, Amelio D, Cianchetti M, et al. A systematic review of proton therapy in the treatment of chondrosarcoma of the skull base. Neurosurg Rev 2010;33:155-165.
Goda J, Ferguson P, O'Sullivan B, et al. High-risk extracranial chondrosarcoma: Long-term results of surgery and radiation therapy. Cancer 2011;117:2513-2519.
Indelicato DJ. Rotondo RL, Begosh-Mayne D, et al. A prospective outcomes study of proton therapy for chordomas and chondrosarcomas of the spine. Int J Radiat Oncol Biol Phys 2016;95:297-303.
Rosenberg AE, Nielsen GP, Keel SB, et al. Chondrosarcoma of the base of the skull: a clinicopathologic study of 200 cases with emphasis on its distinction from chordoma. Am J Surg Pathol 1999;23:1370.
Sahgal A, Chan MW, Atenafu EG, et al. Image-guided, intensity-modulated radiation therapy (IG-IMRT) for skull base chordoma and chondrosarcoma: preliminary outcomes. Neuro Oncol 2015;17:889-894.
De Amorim Bernstein K, DeLaney TJ. Chordomas and chondrosarcomas-The role of radiation therapy. J Surg Oncol 2016;114:564-569.
Imai R, Kamada T, Araki N, Working Group for Bone and Soft-Tissue Sarcomas. Clinical efficacy of carbon ion radiotherapy for unresectable chondrosarcomas. Anticancer Res 2017;37:6959-6964.

Chordoma
Amichetti M, Cianchetti M, Amelio D, et al. Proton therapy in chordoma of the base of the skull: a systematic review. Neurosurg Rev 2009;32:403-416.
Boriani S, Bandiera S, Biagini R, et al. Chordoma of the mobile spine: fifty years of experience. Spine (Phila Pa 1976) 2006;31:493-503.
Kabolizadeh P, Chen YL, Liebsch N, et al. Updated outcome and analysis of tumor response in mobile spine and sacral chordoma treated with definitive high-dose photon/proton radiation therapy. Int J Radiat Oncol Biol Phys 2017;97:254-262.
McDonald M, Linton OR, Moore MG, et al. Influence of residual tumor volume and radiation dose coverage in outcomes for clival chordoma. Int J Radiat Oncol Biol Phys 2016;95:304-311.
Park L, Delaney TF, Liebsch NJ, et al. Sacral chordomas: Impact of high-dose proton/photon-beam radiation therapy combined with or without surgery for primary versus recurrent tumor. Int J Radiat Oncol Biol Phys 2006;65:1514-1521.
Pennicooke B, Laufer I, Sahgal A, et al. Safety and local of radiation therapy for chordoma of the spine and sacrum: A systematic review. Spine (Phila PA 1976) 2016;41 Suppl 20:S186-S192.
Rutz HP, Weber DC, Sugahara S, et al. Extracranial chordoma: Outcome in patients treated with function-preserving surgery followed by spot-scanning proton beam irradiation. Int J Radiat Oncol Biol Phys 2007;67:512-520.
Yasuda M, Bresson D, Chibbaro S, et al. Chordomas of the skull base and cervical spine: clinical outcomes associated with a multimodal surgical resection combined with proton-beam radiation in 40 patients. Neurosurg Rev 2012;35:171-182; discussion 182-183.
Sebro R, DeLaney TF, Hornicek F, et al. Frequency and risk factors for additional lesions in the axial spine in subjects with chordoma: Indications for screening. Spine (Phila Pa 1976) 2017;42:E37-E40.

Ewing Sarcoma
Denbo JW, Shannon Orr W, Wu Y, et al. Timing of surgery and the role of adjuvant radiotherapy in Ewing sarcoma of the chest wall: A single-institution experience. Ann Surg Oncol 2012;19:3809-3815.
Donaldson SS. Ewing sarcoma: radiation dose and target volume. Pediatr Blood Cancer 2004;42:471-476.
Dunst J, Schuck A. Role of radiotherapy in Ewing tumors. Pediatr Blood Cancer 2004;42:465-470.
Indelicato DJ, Keole SR, Lagmay JP, et al. Chest wall Ewing sarcoma family of tumors: long-term outcomes. Int J Radiat Oncol Biol Phys 2011;81:158-166.
Paulino AC, Mai WY, Teh BS. Radiotherapy in metastatic Ewing sarcoma. Am J Clin Oncol 2013;36:283-286.
Paulino AC, Nguyen TX, Mai WY, et al. Dose response and local control using radiotherapy in non-metastatic Ewing sarcoma. Pediatr Blood Cancer 2007;49:145-148.
Rombi B, DeLaney TF, MacDonald SM, et al. Proton radiotherapy for pediatric Ewing's sarcoma: initial clinical outcomes. Int J Radiat Oncol Biol Phys 2012;82:1142-1148.
Brown LC, Lester RA, Grams MP, et al. Stereotactic body radiotherapy for metastatic and recurrent ewing sarcoma and osteosarcoma. Sarcoma 2014;418270.
Baumann BC, Nagda SN, Kolker JD, et al. Efficacy and safety of stereotactic body radiation therapy for the treatment of pulmonary metastases from sarcoma: A potential alternative to resection. J Surg Oncol 2016;114:65-69.
Mehta N, Selch M, Wang PC, et al. Safety and efficacy of stereotactic body radiation therapy in the treatment of pulmonary metastases from high grade sarcoma. Sarcoma 2013;360214.

Continued

Note: All recommendations are category 2A unless otherwise indicated.

Version 2.2026, 12/19/2025 © 2025 National Comprehensive Cancer Network® (NCCN®), All rights reserved. NCCN Guidelines® and this illustration may not be reproduced in any form without the express written permission of NCCN.

PLEASE NOTE that use of this NCCN Content is governed by the End-User License Agreement, and you MAY NOT distribute this Content or use it with any artificial intelligence model or tool.
Printed by Galya Basol Kochav on 12/28/2025 10:24:40 AM. Copyright © 2025 National Comprehensive Cancer Network, Inc. All Rights Reserved.

PRINCIPLES OF RADIATION THERAPY
REFERENCES

Ewing Sarcoma (continued)
Womer RB, West DC, Krailo MD, et al. Randomized controlled trial of interval-compressed chemotherapy for the treatment of localized Ewing sarcoma: a report from the Children's Oncology Group. J Clin Oncol 2012;30:4148-4154.
Schuck A, Ahrens S, von Schorlemer I, et al. Radiotherapy in Ewing tumors of the vertebrae: treatment results and local relapse analysis of the CESS 81/86 and EICESS 92 trials. Int J Radiat Oncol Biol Phys 2005;63:1562-1567.
Tanguturi SK, George S, Marcus KJ, et al. Whole lung irradiation in adults with metastatic Ewing sarcoma: Practice patterns and implications for treatment. Sarcoma 2015;2015: 591698.
Yock TI, Krailo M, Fryer CJ, et al. Local control in pelvic Ewing sarcoma: analysis from INT-0091--a report from the Children's Oncology Group. J Clin Oncol 2006;24:3838-3843. Erratum in: J Clin Oncol 2006;24:4947.
Casey DL, Meyers PA, Alektiar KM, et al. Ewing sarcoma in adults treated with modern radiotherapy techniques. Radiother Oncol 2014;113:248-253.
Talleur AC, Navid F, Spunt SL, et al. Limited margin radiation therapy for children and young adults with Ewing sarcoma achieves high rates of local tumor control. Int J Radiat Oncol Biol Phys 2016;96:119-126.
Laskar S, Sinha S, Chatterjee A, et al. Radiation therapy dose escalation in unresectable Ewing sarcoma: Final results of a phase 3 randomized controlled trial. Int J Radiat Oncol Biol Phys 2022;113:996-1002.

Giant Cell Tumor of Bone
Caudell JJ, Ballo MT, Zagars GK, et al. Radiotherapy in the management of giant cell tumor of bone. Int J Radiat Oncol Biol Phys 2003;57:158-165.
Hug EB, Muenter MW, Adams JA, et al. 3-D-conformal radiation therapy for pediatric giant cell tumors of the skull base. Strahlenther Onkol 2002;178:239-244.
Malone S, O'Sullivan B, Catton C, et al. Long-term follow-up of efficacy and safety of megavoltage radiotherapy in high-risk giant cell tumors of bone. Int J Radiat Oncol Biol Phys 1995;33:689-694.
Ruka W, Rutkowski P, Morysinski T, et al. The megavoltage radiation therapy in treatment of patients with advanced or difficult giant cell tumors of bone. Int J Radiat Oncol Biol Phys 2010;78:494-498.

Mixed Histology Reports
DeLaney TF, Liebsch NJ, Pedlow FX, et al. Phase II study of high-dose photon/proton radiotherapy in the management of spine sarcomas. Int J Radiat Oncol Biol Phys 2009;74:732-739.
Jingu K, Tsujii H, Mizoe JE, et al. Organizing Committee for the Working Group for Head-and-Neck Cancer. Carbon ion radiation therapy improves the prognosis of unresectable adult bone and soft-tissue sarcoma of the head and neck. Int J Radiat Oncol Biol Phys 2012;82:2125-2131.
Kamada T, Tsujii H, Yanagi T, et al. Efficacy and safety of carbon ion radiotherapy in bone and soft tissue sarcomas. Working Group for the Bone and Soft Tissue Sarcomas. J Clin Oncol 2002;20:4466-4471.
Wagner TD, Kobayashi W, Dean S, et al. Combination short-course preoperative irradiation, surgical resection, and reduced-field high-dose postoperative irradiation in the treatment of tumors involving the bone. Int J Radiat Oncol Biol Phys 2009;73:259-266.

Osteosarcoma
Ciernik IF, Niemierko A, Harmon DC, et al. Proton-based radiotherapy for unresectable or incompletely resected osteosarcoma. Cancer 2011;117:4522-4530.
DeLaney TF, Park L, Goldberg SI, et al. Radiotherapy for local control of osteosarcoma. Int J Radiat Oncol Biol Phys 2005;61:492-498.
Guadagnolo BA, Zagars GK, Raymond AK, et al. Osteosarcoma of the jaw/craniofacial region: Outcomes after multimodality treatment. Cancer 2009;115:3262-3270.
Mahajan A, Woo SY, Kornguth DG, et al. Multimodality treatment of osteosarcoma: radiation in a high-risk cohort. Pediatr Blood Cancer 2008;50:976-982.
Brown LC, Lester RA, Grams MP, et al. Stereotactic body radiotherapy for metastatic and recurrent ewing sarcoma and osteosarcoma. Sarcoma 2014;418270.
Baumann BC, Nagda SN, Kolker JD, et al. Efficacy and safety of stereotactic body radiation therapy for the treatment of pulmonary metastases from sarcoma: A potential alternative to resection. J Surg Oncol 2016;114:65-69.
Mehta N, Selch M, Wang PC, et al. Safety and efficacy of stereotactic body radiation therapy in the treatment of pulmonary metastases from high grade sarcoma. Sarcoma 2013;360214.

Note: All recommendations are category 2A unless otherwise indicated.

Version 2.2026, 12/19/2025 © 2025 National Comprehensive Cancer Network® (NCCN®), All rights reserved. NCCN Guidelines® and this illustration may not be reproduced in any form without the express written permission of NCCN.

PLEASE NOTE that use of this NCCN Content is governed by the End-User License Agreement, and you MAY NOT distribute this Content or use it with any artificial intelligence model or tool.
Printed by Galya Basol Kochav on 12/28/2025 10:24:40 AM. Copyright © 2025 National Comprehensive Cancer Network, Inc. All Rights Reserved.

PRINCIPLES OF PATHOLOGY

- **Biopsy should provide a specific diagnosis and histologic grade, when appropriate and feasible.**
- **Pathologic evaluation should be performed by an experienced sarcoma pathologist.**
- **Microscopic examination is the gold standard for diagnosis of bone tumors, which should be performed in conjunction with review of radiologic studies. Ancillary techniques should be applied to support the diagnosis of selected sarcoma types, such as Ewing sarcoma (eg, immunohistochemistry, fluorescence in situ hybridization [FISH], and/or molecular genetic testing).**
- **The pathology report for resection specimens should include the following features[1] (synoptic reporting according to the College of American Pathologists protocol is required for accreditation purposes)[2]:**
  - **Neoadjuvant therapy (and type)**
  - **Operative procedure**
  - **Tumor anatomic site**
  - **Tumor size (greatest dimension)**
  - **Tumor location and extent of invasion**
    - **◊ Add "surface" if tumor originates on periosteal surface (especially relevant for osteosarcoma subtypes)**
    - **◊ Add "intracompartmental" or "extracompartmental" (especially relevant for defining atypical cartilaginous tumors)**
  - **Presence of skip metastases (discontinuous tumor)**
  - **Histologic tumor type (WHO Classification)[3]**
  - **Histologic tumor grade**
  - **Presence and extent of necrosis**
  - **Treatment effect and extent**
  - **Margin status**
    - **◊ Distance to and localization of closest margin(s)**
      - **– Necrotic tumor at margin for Ewing sarcoma is considered a negative margin if there is a complete pathologic response.[4]**
  - **Ancillary studies**
    - **◊ Decalcification on a portion of the specimen should optimally be performed with solutions that preserve RNA and DNA; strong acid-based decalcification (other than EDTA or EDTA + formic acid solutions) should therefore be avoided.[1]**
  - **Pathologic stage classification (AJCC 8th Edition)[5]**

References

Note: All recommendations are category 2A unless otherwise indicated.

Version 2.2026, 12/19/2025 © 2025 National Comprehensive Cancer Network® (NCCN®), All rights reserved. NCCN Guidelines® and this illustration may not be reproduced in any form without the express written permission of NCCN.

PLEASE NOTE that use of this NCCN Content is governed by the End-User License Agreement, and you MAY NOT distribute this Content or use it with any artificial intelligence model or tool.
Printed by Galya Basol Kochav on 12/28/2025 10:24:40 AM. Copyright © 2025 National Comprehensive Cancer Network, Inc. All Rights Reserved.

PRINCIPLES OF PATHOLOGY
REFERENCES

[1] Bovée JVMG, Webster F, Amary F, et al. Datasets for the reporting of primary tumour in bone: recommendations from the International Collaboration on Cancer Reporting (ICCR). Histopathology 2023;82:531-540.
[2] College of American Pathologists. Protocol for the Examination of Resection Specimens From Patients With Primary Tumors of Bone. Version: 4.1.1.0. Protocol posting date: July 2021.
[3] WHO Classification of Tumours Editorial Board. Soft Tissue and Bone Tumours. Lyon (France): International Agency for Research on Cancer; 2020. WHO Classification of Tumours Series, 5th Edition.
[4] Lozano-Calderón SA, Albergo JI, Groot OQ, et al. Complete tumor necrosis after neoadjuvant chemotherapy defines good responders in patients with Ewing sarcoma. Cancer 2023;129:60-70.
[5] Amin MB, Greene FL, Edge SB, et al. The Eighth Edition AJCC Cancer Staging Manual: Continuing to build a bridge from a population-based to a more "personalized" approach to cancer staging. CA Cancer J Clin 2017;67:93-99.

Note: All recommendations are category 2A unless otherwise indicated.

Version 2.2026, 12/19/2025 © 2025 National Comprehensive Cancer Network® (NCCN®), All rights reserved. NCCN Guidelines® and this illustration may not be reproduced in any form without the express written permission of NCCN.

PLEASE NOTE that use of this NCCN Content is governed by the End-User License Agreement, and you MAY NOT distribute this Content or use it with any artificial intelligence model or tool.
Printed by Galya Basol Kochav on 12/28/2025 10:24:40 AM. Copyright © 2025 National Comprehensive Cancer Network, Inc. All Rights Reserved.

American Joint Committee on Cancer (AJCC)
TNM Staging System for Bone *(Primary malignant lymphoma and multiple myeloma are not included)*

Table 1. **Definitions for T, N, M**

Appendicular Skeleton, Trunk, Skull, and Facial Bones

T	**Primary Tumor**
TX	Primary tumor cannot be assessed
T0	No evidence of primary tumor
T1	Tumor ≤8 cm in greatest dimension
T2	Tumor >8 cm in greatest dimension
T3	Discontinuous tumors in the primary bone site

Spine

T	**Primary Tumor**
TX	Primary tumor cannot be assessed
T0	No evidence of primary tumor
T1	Tumor confined to one vertebral segment or two adjacent vertebral segments
T2	Tumor confined to three adjacent vertebral segments
T3	Tumor confined to four or more adjacent vertebral segments, or any nonadjacent vertebral segments
T4	Extension into the spinal canal or great vessels
T4a	Extension into the spinal canal
T4b	Evidence of gross vascular invasion or tumor thrombus in the great vessels

Pelvis

T	**Primary Tumor**
TX	Primary tumor cannot be assessed
T0	No evidence of primary tumor
T1	Tumor confined to one pelvic segment with no extraosseous extension
T1a	Tumor ≤8 cm in greatest dimension
T1b	Tumor >8 cm in greatest dimension
T2	Tumor confined to one pelvic segment with extraosseous extension or two segments without extraosseous extension
T2a	Tumor ≤8 cm in greatest dimension
T2b	Tumor >8 cm in greatest dimension
T3	Tumor spanning two pelvic segments with extraosseous extension
T3a	Tumor ≤8 cm in greatest dimension
T3b	Tumor >8 cm in greatest dimension
T4	Tumor spanning three pelvic segments or crossing the sacroiliac joint
T4a	Tumor involves sacroiliac joint and extends medial to the sacral neuroforamen
T4b	Tumor encasement of external iliac vessels or presence of gross tumor thrombus in major pelvic vessels

N	**Regional Lymph Nodes**
NX	Regional lymph nodes cannot be assessed

Because of the rarity of lymph node involvement in bone sarcomas, the designation NX may not be appropriate and cases should be considered N0 unless clinical node involvement is clearly evident.

N0	No regional lymph node metastasis
N1	Regional lymph node metastasis

Used with the permission of the American College of Surgeons, Chicago, Illinois. The original source for this information is the AJCC Cancer Staging Manual, Eighth Edition (2017) published by Springer International Publishing.

Continued

Version 2.2026, 12/19/2025 © 2025 National Comprehensive Cancer Network® (NCCN®), All rights reserved. NCCN Guidelines® and this illustration may not be reproduced in any form without the express written permission of NCCN.

PLEASE NOTE that use of this NCCN Content is governed by the End-User License Agreement, and you MAY NOT distribute this Content or use it with any artificial intelligence model or tool.
Printed by Galya Basol Kochav on 12/28/2025 10:24:40 AM. Copyright © 2025 National Comprehensive Cancer Network, Inc. All Rights Reserved.

American Joint Committee on Cancer (AJCC)
TNM Staging System for Bone *(continued)*

M	**Distant Metastasis**
M0	No distant metastasis
M1	Distant metastasis
M1a	Lung
M1b	Bone or other distant sites

G	**Histologic Grade**
GX	Grade cannot be assessed
G1	Well differentiated — Low Grade
G2	Moderately differentiated — High Grade
G3	Poorly differentiated — High Grade

Table 2. **AJCC Prognostic Groups**

There are no AJCC prognostic stage groupings for spine and pelvis.

	T	N	M	G
Stage IA	T1	N0	M0	G1, GX
Stage IB	T2	N0	M0	G1, GX
	T3	N0	M0	G1, GX
Stage IIA	T1	N0	M0	G2, G3
Stage IIB	T2	N0	M0	G2, G3
Stage III	T3	N0	M0	G2, G3
Stage IVA	Any T	N0	M1a	Any G
Stage IVB	Any T	N1	Any M	Any G
	Any T	Any N	M1b	Any G

Used with the permission of the American College of Surgeons, Chicago, Illinois. The original source for this information is the AJCC Cancer Staging Manual, Eighth Edition (2017) published by Springer International Publishing.

Version 2.2026, 12/19/2025 © 2025 National Comprehensive Cancer Network® (NCCN®), All rights reserved. NCCN Guidelines® and this illustration may not be reproduced in any form without the express written permission of NCCN.

PLEASE NOTE that use of this NCCN Content is governed by the End-User License Agreement, and you MAY NOT distribute this Content or use it with any artificial intelligence model or tool.
Printed by Galya Basol Kochav on 12/28/2025 10:24:40 AM. Copyright © 2025 National Comprehensive Cancer Network, Inc. All Rights Reserved.

ABBREVIATIONS

ALP	alkaline phosphatase
C/A/P	chest/abdomen/pelvis
CBC	complete blood count
CD	cone-down
CMP	comprehensive metabolic panel
COG	Children's Oncology Group
CTV	clinical target volume
dMMR	mismatch repair deficient
FDG	fluorodeoxyglucose
FISH	fluorescence in situ hybridization
G-CSF	granulocyte colony-stimulating factor
GTV	gross tumor volume
IMRT	intensity-modulated radiation therapy
LDH	lactate dehydrogenase
MGPT	multigene panel testing
MMR	mismatch repair
MSI	microsatellite instability
MSI-H	microsatellite instability-high
NGS	next-generation sequencing
PCR	polymerase chain reaction
PSA	prostate-specific antigen
PTV	planning target volume
SBRT	stereotactic body radiation therapy
SPEP	serum protein electrophoresis
SRS	stereotactic radiosurgery
TMB	tumor mutational burden
TMB-H	tumor mutational burden-high
UPS	undifferentiated pleomorphic sarcoma
WLI	whole lung irradiation

Version 2.2026, 12/19/2025 © 2025 National Comprehensive Cancer Network® (NCCN®), All rights reserved. NCCN Guidelines® and this illustration may not be reproduced in any form without the express written permission of NCCN.

PLEASE NOTE that use of this NCCN Content is governed by the End-User License Agreement, and you MAY NOT distribute this Content or use it with any artificial intelligence model or tool.
Printed by Galya Basol Kochav on 12/28/2025 10:24:40 AM. Copyright © 2025 National Comprehensive Cancer Network, Inc. All Rights Reserved.

NCCN Categories of Evidence and Consensus	
Category 1	Based upon high-level evidence (≥1 randomized phase 3 trials or high-quality, robust meta-analyses), there is uniform NCCN consensus (≥85% support of the Panel) that the intervention is appropriate.
Category 2A	Based upon lower-level evidence, there is uniform NCCN consensus (≥85% support of the Panel) that the intervention is appropriate.
Category 2B	Based upon lower-level evidence, there is NCCN consensus (≥50%, but <85% support of the Panel) that the intervention is appropriate.
Category 3	Based upon any level of evidence, there is major NCCN disagreement that the intervention is appropriate.

All recommendations are category 2A unless otherwise indicated.

NCCN Categories of Preference	
Preferred	Interventions that are based on superior efficacy, safety, and evidence; and, when appropriate, affordability.
Other recommended	Other interventions that may be somewhat less efficacious, more toxic, or based on less mature data; or significantly less affordable for similar outcomes.
Useful in certain circumstances	Other interventions that may be used for selected patient populations (defined with recommendation).

All recommendations are considered appropriate.

Version 2.2026, 12/19/2025 © 2025 National Comprehensive Cancer Network® (NCCN®), All rights reserved. NCCN Guidelines® and this illustration may not be reproduced in any form without the express written permission of NCCN.

PLEASE NOTE that use of this NCCN Content is governed by the End-User License Agreement, and you MAY NOT distribute this Content or use it with any artificial intelligence model or tool.
Printed by Galya Basol Kochav on 12/28/2025 10:24:40 AM. Copyright © 2025 National Comprehensive Cancer Network, Inc. All Rights Reserved.

Discussion

This discussion corresponds to the NCCN Guidelines for Bone Cancer. Last updated on December 19, 2025

Table of Contents

Overview MS-2
Guidelines Update Methodology MS-2
Literature Search Criteria MS-3
Sensitive/Inclusive Language Usage MS-3
Staging MS-3
Principles of Bone Cancer Management MS-3
Chondrosarcoma MS-6
- Prognostic Factors MS-7
- Treatment MS-7
- Metastatic Disease MS-10
- Surveillance MS-11
- Relapsed Disease MS-11

Chordoma MS-11
- Workup MS-12
- Treatment MS-12
- Surveillance MS-15
- Relapsed Disease MS-15

Ewing Sarcoma MS-15
- Prognostic Factors MS-16
- Workup MS-17
- Treatment MS-17
- Surveillance MS-21
- Relapsed or Refractory Disease MS-22

Giant Cell Tumor of Bone MS-23
- Workup MS-24
- Treatment MS-24
- Surveillance and Recurrence MS-26

Osteosarcoma MS-26
- Prognostic Factors MS-27
- Workup MS-28
- Treatment MS-28
- Surveillance MS-32
- Relapsed or Refractory Disease MS-32

High-Grade Undifferentiated Pleomorphic Sarcoma of Bone MS-34
Biomarker Testing and Additional Treatment Options MS-34
Summary MS-35
References MS-36

Version 2.2026 © 2025 National Comprehensive Cancer Network© (NCCN©), All rights reserved. NCCN Guidelines® and this illustration may not be reproduced in any form without the express written permission of NCCN.

PLEASE NOTE that use of this NCCN Content is governed by the End-User License Agreement, and you MAY NOT distribute this Content or use it with any artificial intelligence model or tool.
Printed by Galya Basol Kochav on 12/28/2025 10:24:40 AM. Copyright © 2025 National Comprehensive Cancer Network, Inc. All Rights Reserved.

Overview

Primary bone cancers are extremely rare neoplasms accounting for ~0.2% of all cancers, although the true incidence is difficult to determine secondary to the rarity of these tumors.[1] In 2025 an estimated 3770 people will be diagnosed in the United States and 2190 people will die from these diseases.[2]

Primary bone cancers demonstrate wide clinical heterogeneity and may be curable with proper treatment. In adults, chondrosarcoma is the most common primary bone cancer, accounting for >40% of newly diagnosed bone cancers, followed by osteosarcoma (~25%), chordoma (10%), and Ewing sarcoma (8%).[3] Other less common primary bone tumors include giant cell tumor of bone (GCTB) and undifferentiated pleomorphic sarcoma (UPS). In children and adolescents, osteosarcoma and Ewing sarcoma are far more common than chondrosarcoma and chordoma.[3,4] High-grade UPS of bone and GCTB are relatively rare tumors, with each constituting <5% of primary bone tumors.[5] GCTB has both benign and exceptionally rare malignant forms. Various types of bone cancers are named based on their histologic line of differentiation. Chondrosarcomas differentiate toward cartilage, osteosarcomas toward bone, angiosarcoma and epithelioid hemangioendothelioma show endothelial (vascular) differentiation, and chordoma shows notochordal differentiation. Several primary bone cancers, including Ewing sarcoma, are of unknown lineage. Chondrosarcoma is more prevalent in individuals >50 years of age.[6] Osteosarcoma and Ewing sarcoma develop mainly in children and young adults. Chordoma is more common in males, with the peak incidence in the fifth to sixth decade of life.[7-9]

The pathogenesis and etiology of most bone cancers remain unclear. Some evidence suggests that up to 20% of sarcomas may be associated with variations in cancer predisposition genes.[10] Gene rearrangements between the FET (usually *EWSR1*) and ETS (usually *FLI1*) family of genes have been implicated in the pathogenesis of Ewing sarcoma.[11-15] Specific germline mutations have been linked to the development of osteosarcoma.[16] Li-Fraumeni syndrome, characterized by a germline mutation in the *TP53* gene, is associated with a high risk of developing cancer, including osteosarcoma.[17-19] Osteosarcoma is the most common second primary malignancy in patients with a history of retinoblastoma, characterized by a germline mutation in the retinoblastoma gene *RB1*.[20-22] Evidence suggests that the risk of developing osteosarcoma after having had retinoblastoma is 300 to 600 times more likely than the general population. [23] Increased incidences of osteosarcoma have also been associated with other genetic mutations and inherited genetic predisposition syndromes.[22] Osteosarcoma is also the most common radiation-induced bone sarcoma.[24,25]

The development of multiagent chemotherapy regimens for neoadjuvant and adjuvant treatment has markedly improved the prognosis for patients with osteosarcoma and Ewing sarcoma.[26,27] With current multimodality treatment, approximately 60% to 70% of patients diagnosed with osteosarcoma (without clinically evident metastases) are cured, and ~90% of patients diagnosed with osteosarcoma can be treated with limb-sparing approaches.[28-30] Five-year relative survival rates have improved to 82% in patients with localized Ewing sarcoma.[31] In patients with Ewing sarcoma and osteosarcoma, a cure is still achievable in selected patients diagnosed with metastatic disease at presentation.[32,33] The 5-year survival across all types of primary bone cancers is 68%.[1]

The NCCN Clinical Practice Guidelines in Oncology (NCCN Guidelines®) for Bone Cancer focus on chordoma, chondrosarcoma, Ewing sarcoma, and osteosarcoma. The guidelines also provide recommendations for treating GCTB. Although typically benign, GCTB is locally aggressive and can lead to significant bone destruction. Malignant transformation is also possible.

Version 2.2026 © 2025 National Comprehensive Cancer Network© (NCCN©), All rights reserved. NCCN Guidelines® and this illustration may not be reproduced in any form without the express written permission of NCCN.

PLEASE NOTE that use of this NCCN Content is governed by the End-User License Agreement, and you MAY NOT distribute this Content or use it with any artificial intelligence model or tool.
Printed by Galya Basol Kochav on 12/28/2025 10:24:40 AM. Copyright © 2025 National Comprehensive Cancer Network, Inc. All Rights Reserved.

Guidelines Update Methodology

The complete details of the Development and Update of the NCCN Guidelines® are available at www.NCCN.org.

Literature Search Criteria

Prior to the update of this version of the NCCN Guidelines for Bone Cancer, an electronic search of the PubMed database was performed to obtain key literature published in bone cancer since the previous Guidelines update, using the following search terms: chondrosarcoma OR chordoma OR Ewing sarcoma OR giant cell tumor of the bone OR osteosarcoma OR bone sarcoma OR primary bone cancer OR primary bone neoplasm OR primary bone tumor.

The search results were narrowed by selecting studies in humans published in English. Results were confined to the following article types: Clinical Trial, Phase II; Clinical Trial, Phase III; Clinical Trial, Phase IV; Guideline; Practice Guideline; Randomized Controlled Trial; Meta-Analysis; Systematic Reviews; and Validation Studies.

The data from key PubMed articles as well as articles from additional sources deemed as relevant to these guidelines and discussed by the Panel have been included in this version of the Discussion section (eg, e-publications ahead of print, meeting abstracts). Recommendations for which high-level evidence is lacking are based on the Panel's review of lower-level evidence and expert opinion.

Sensitive/Inclusive Language Usage

NCCN Guidelines strive to use language that advances the goals of equity, inclusion, and representation.[34] NCCN Guidelines endeavor to use language that is person-first; not stigmatizing; anti-racist, anti-classist, anti-misogynist, anti-ageist, anti-ableist, and anti-weight-biased; and inclusive of individuals of all sexual orientations and gender identities. NCCN Guidelines incorporate non-gendered language, instead focusing on organ-specific recommendations. This language is both more accurate and more inclusive and can help fully address the needs of individuals of all sexual orientations and gender identities. NCCN Guidelines will continue to use the terms men, women, female, and male when citing statistics, recommendations, or data from organizations or sources that do not use inclusive terms. Most studies do not report how sex and gender data are collected and use these terms interchangeably or inconsistently. If sources do not differentiate gender from sex assigned at birth or organs present, the information is presumed to predominantly represent cisgender individuals. NCCN encourages researchers to collect more specific data in future studies and organizations to use more inclusive and accurate language in their future analyses.

Staging

The eighth edition of the AJCC staging classification (2018) is based on the assessment of histologic grade (G), tumor size (T), and presence of regional (N) and/or distant metastases (M).[35]

The NCCN Panel would like to clarify that although some studies interpret imaging before chemotherapy treatment based on the extent of tumor invasion relative to the periosteum (eg, extraperiosteal, intraperiosteal) for prognostic purposes, these terms do not specifically occur in any validated staging systems and the significance is unknown.

Principles of Bone Cancer Management

Multidisciplinary Team Involvement

Primary bone tumors and selected metastatic tumors should be evaluated and treated by a multidisciplinary team of physicians with demonstrated expertise in the management of these tumors. The core team should include, at minimum, the following: orthopedic oncologist, bone pathologist, medical/pediatric oncologist, radiation oncologist, and

Version 2.2026 © 2025 National Comprehensive Cancer Network© (NCCN©), All rights reserved. NCCN Guidelines® and this illustration may not be reproduced in any form without the express written permission of NCCN.

PLEASE NOTE that use of this NCCN Content is governed by the End-User License Agreement, and you MAY NOT distribute this Content or use it with any artificial intelligence model or tool.
Printed by Galya Basol Kochav on 12/28/2025 10:24:40 AM. Copyright © 2025 National Comprehensive Cancer Network, Inc. All Rights Reserved.

musculoskeletal radiologist. Other specialists who may be critical in certain cases include the following: thoracic surgeon, plastic surgeon, interventional radiologist, physiatrist, vascular/general surgeon, neurosurgeon/orthopedic spine surgeon, and palliative care physician. Additional surgical subspecialties may be included as clinically indicated.

Long-term surveillance and follow-up are necessary when considering the risk of recurrence and comorbidities associated with systemic therapy and radiation therapy (RT). Life-long follow-up is recommended for surveillance and treatment of late effects of surgery, RT, and systemic therapy in long-term survivors. Patients should be given a survivorship prescription to schedule follow-up with a multidisciplinary team.

Fertility issues should be discussed with appropriate patients.[36] For further details and recommendations, including information on disease- and survivorship-related issues for adolescent and young adult (AYA) patients, please refer to the NCCN Guidelines for Adolescent and Young Adult (AYA) Oncology, available at www.NCCN.org.

Finally, select patients with a history of osteosarcoma or chondrosarcoma may benefit from genetic consultation and testing based on family history with a genetic predisposition to bone sarcomas.

Diagnostic Workup

Suspicion of a malignant bone tumor in a patient with a symptomatic lesion often begins when a poorly marginated lesion is seen on a plain radiograph.

In patients <40 years, an aggressive, symptomatic bone lesion has a significant risk of being a malignant primary bone tumor. Referral to an orthopedic oncologist should be considered prior to further workup.

In patients ≥40 years of age, workup for potential bone metastasis is recommended as indicated. This would include history and physical (H&P), bone scan, chest x-ray, and computed tomography (CT) of the chest/abdomen/pelvis (C/A/P) with intravenous contrast. Additional testing, such as serum protein electrophoresis (SPEP), complete blood count (CBC), comprehensive metabolic panel (CMP), prostate-specific antigen (PSA) test, or mammogram may also be included.[37] Other imaging studies such as 18F-fluorodeoxyglucose (FDG)-PET/CT (category 2B) and/or skeletal survey (if multiple myeloma is suspected) may be performed.[37-39]

Prior to biopsy, all patients with suspected bone sarcoma should undergo complete staging as well as consultation with an oncologist regarding pre-biopsy imaging.

Depending on the suspected type of primary bone cancer, the standard staging workup can include H&P, x-ray, cross-sectional imaging of the primary site (eg, contrast-enhanced MRI of the entire bone, and/or CT scan if MRI contraindicated), screening MRI of spinal axis, and CT C/A/P with contrast.[40] FDG-PET/CT and/or bone scan can be considered if clinically indicated.

Fertility consultation should be offered to individuals of child-bearing potential if cytotoxic chemotherapy will be given. The American Society for Reproductive Medicine (ASRM) recommends that conversations concerning fertility be undertaken by an interdisciplinary medical team comprised of oncologists, reproductive endocrinologists and urologists, and reproductive surgeons trained in fertility preservation methods and that fertility preservation programs be affiliated with an experienced assisted reproductive technology (ART) program.[41,42]

Laboratory studies, such as CBC, CMP with calcium to assess hypercalcemia, lactate dehydrogenase (LDH), and alkaline phosphatase

Version 2.2026 © 2025 National Comprehensive Cancer Network© (NCCN©), All rights reserved. NCCN Guidelines® and this illustration may not be reproduced in any form without the express written permission of NCCN.

PLEASE NOTE that use of this NCCN Content is governed by the End-User License Agreement, and you MAY NOT distribute this Content or use it with any artificial intelligence model or tool.
Printed by Galya Basol Kochav on 12/28/2025 10:24:40 AM. Copyright © 2025 National Comprehensive Cancer Network, Inc. All Rights Reserved.

(ALP) should be done prior to definitive treatment and periodically during treatment and surveillance. Molecular studies can be considered to delineate potential therapeutic options.

Biopsy

Percutaneous biopsy (core needle) or incisional (open) biopsy are the two techniques historically used in the diagnosis of musculoskeletal lesions.[43,44]

Open biopsy is the most accurate method because of larger sample size, which is useful for performing additional studies such as immunohistochemistry or cytogenetics.[45] However, open biopsy requires general or regional anesthesia and operating room facilities; moreover, it can lead to contamination of surrounding tissues. Core biopsy can be performed under moderate sedation. Core needle biopsy is also highly diagnostic, with accuracy rates ranging from 88% to 96% when adequate samples are obtained.[46-49] Core biopsy is associated with a low complication rate and cost savings may be realized when needle biopsy is employed in selected patients.[46,49,50] Advances in imaging techniques have contributed to the increasing use of image-guided percutaneous biopsy for the diagnosis of primary and secondary bone tumors.[51] Furthermore, rates of complications, particularly altered treatment and outcomes, are considerably higher with open biopsy.[44,52] Although no randomized controlled trials have compared core needle biopsy with open biopsy, the higher complication rate and cost of open biopsy have resulted in a shift to the use of primarily core biopsy for diagnosis.

The guidelines recommend core needle or open biopsy to confirm the diagnosis of primary bone tumor prior to any surgical procedure or fixation of primary site. Biopsy is optimally performed at a center that will provide definitive treatment for patients with a suspected primary malignant bone tumor. At the time of biopsy, careful consideration should be given to appropriate measures to protect against impending pathologic fracture. The placement of biopsy is critical to the planning of limb-sparing surgery. A multidisciplinary approach including the radiologist and orthopedic oncologic surgeon should be taken to follow appropriate biopsy procedures and decrease risk of adverse patient outcomes.[53,54] In a multicenter review of 597 patients with musculoskeletal tumors, alteration of the treatment plan (complex resection or the use of adjunctive treatment) was encountered in 19% of patients and unnecessary amputation was performed in 18 patients.[52]

Both core needle and open biopsy techniques are associated with risk of local tumor recurrence, either by tumor spillage or tumor seeding along the biopsy tract, if the scar is not removed en bloc during the tumor resection. The risk of tumor seeding is less with core needle biopsy.[55-57] Nevertheless, the same principles should be applied for core needle and open biopsy. Appropriate communication between the surgeon, musculoskeletal or interventional radiologist, and bone pathologist is critical in planning the biopsy route. In the case of children, consultation with a pediatric oncologist is recommended. It is essential to select the biopsy route in collaboration with the surgeon to ensure that the biopsy tract lies within the planned resection bed so that it can be resected with the same wide margins as the primary tumor during surgery. Although the risk of tumor seeding is not significant with FNA biopsy, it is not suitable for the diagnosis of primary lesions since the diagnostic accuracy of FNA is less than that of core needle biopsy.[58]

Surgery

Surgical margins should be negative for most sarcomas, wide enough to minimize potential local recurrence, and narrow enough to maximize function. Wide excision implies histologically negative surgical margins, which are necessary to optimize local control. Local control may be achieved either by limb-sparing surgery or amputation. In selected

Version 2.2026 © 2025 National Comprehensive Cancer Network© (NCCN©), All rights reserved. NCCN Guidelines® and this illustration may not be reproduced in any form without the express written permission of NCCN.

PLEASE NOTE that use of this NCCN Content is governed by the End-User License Agreement, and you MAY NOT distribute this Content or use it with any artificial intelligence model or tool.
Printed by Galya Basol Kochav on 12/28/2025 10:24:40 AM. Copyright © 2025 National Comprehensive Cancer Network, Inc. All Rights Reserved.

cases, amputation may be the most appropriate option to achieve this goal. However, limb-sparing surgery is preferred if reasonable functional outcomes can be achieved. Final pathologic evaluation should include assessment of surgical margins and size/dimensions of tumor. Fresh tissue may be needed for molecular studies and tissue banking. The response to preoperative therapy should be evaluated utilizing pathologic mapping. Consultation with a physiatrist may assist with mobility training and prescribing an appropriate rehabilitation program.

Radiation Therapy

RT is used either as an adjuvant to surgery for patients with resectable tumors or as definitive therapy in patients with tumors not amenable to surgery. Specialized techniques such as intensity-modulated RT (IMRT); particle beam RT with protons, carbon ions, or other heavy ions; or stereotactic radiosurgery (SRS)/stereotactic RT (SRT) should be considered as clinically indicated in order to deliver high radiation doses while maximizing normal tissue sparing.[59,60] RT should be administered at the same specialized center that is providing surgical and systemic interventions. See *Principles of Radiation Therapy* in the algorithm for treatment volumes and radiation doses specific to each subtype.

Chondrosarcoma

Chondrosarcomas characteristically produce cartilage matrices from neoplastic tissue devoid of osteoid and may occur at any age, but they are more common in older adults.[61,62] They may be classified according to the location from which they arise, with the pelvis and the proximal femur being the most common primary sites of origin. They may also be distinguished by their location along the bone as follows: 1) primary or central lesions (arising normally from the medullary cavity) originating from previously normal-appearing bone preformed from cartilage; or 2) secondary or peripheral tumors (arising from the periosteum) that develop from preexisting benign cartilage lesions, such as enchondromas, or from the cartilaginous portion of an osteochondroma.[61,63,64] Conventional chondrosarcoma (CCS) of the bone constitutes approximately nearly 90% of all chondrosarcomas, and, of these, 90% are low to intermediate grade.[65]

Low-grade (grade 1) tumors in the appendicular skeleton are currently classified by the World Health Organization (WHO) as atypical cartilaginous tumors, and are sometimes also referred to as low-grade intracompartmental appendicular tumors, while those that occur in the axial skeleton are considered grade 1 chondrosarcomas.[5]

Malignant transformation has been reported in patients with Ollier disease (enchondromatosis) and Maffucci syndrome (enchondromatosis associated with soft tissue hemangioma).[66] The peripheral or secondary tumors are usually low grade with infrequent metastasis.[67] Nearly 65% of chondrosarcoma cases and nearly all cases of Ollier disease and Maffucci syndrome are related to isocitrate dehydrogenase (*IDH1* or *IDH2*) mutations.[65,68-70] Other implicated genetic aberrations include inactivating mutations of *CDKN2A* and *COL2A1*.[64] In addition to CCS, there are several non-conventional subtypes constituting about 10% to 15% of all chondrosarcomas.[61] These include clear cell, juxtacortical, dedifferentiated, myxoid, and mesenchymal forms of chondrosarcoma.[61,71,72] Primary skeletal myxoid chondrosarcoma (myxoid chondrosarcoma of bone) is an extremely rare neoplasm that has not been fully characterized as a distinct clinicopathologic entity.[73,74] It is considered to be a myxoid variant of intermediate- or high-grade chondrosarcoma and is commonly located in the bones around the hip joint.[61,74] An epidemiologic study of mesenchymal chondrosarcomas using the SEER database found that 40% of these were skeletal and 60% were extraskeletal.[75] Research suggests that alterations in the retinoblastoma pathway are present in a significant majority of clear cell, dedifferentiated, and mesenchymal chondrosarcomas.[71]

Version 2.2026 © 2025 National Comprehensive Cancer Network© (NCCN©), All rights reserved. NCCN Guidelines® and this illustration may not be reproduced in any form without the express written permission of NCCN.

PLEASE NOTE that use of this NCCN Content is governed by the End-User License Agreement, and you MAY NOT distribute this Content or use it with any artificial intelligence model or tool.
Printed by Galya Basol Kochav on 12/28/2025 10:24:40 AM. Copyright © 2025 National Comprehensive Cancer Network, Inc. All Rights Reserved.

Extraskeletal myxoid chondrosarcoma, on the other hand, is a rare soft tissue sarcoma that is characterized by chromosomal translocations t(9;22)(q22;q11-12) or t(9;17)(q22;q11), generating the fusion genes *EWS::CHN (EWSR1::NR4A3)* or *RBP56::CHN (TAF2N::NR4A3)*, respectively.[76,77] In addition, two other variant chromosomal translocations, t(9;15)(q22;q21) and t(3;9)(q12;q22), resulting in fusion genes *TCF12::NR4A3* and *TFG::NR4A3*, respectively, have also been identified in case reports.[78] A retrospective study demonstrated prolonged overall survival (OS) in patients with extraskeletal myxoid chondrosarcoma despite high rates of local and distant recurrence.[79] The data also revealed a significant pattern of decreased event-free survival (EFS) with increasing tumor size. For recommendations on the treatment of extraskeletal myxoid chondrosarcoma, see the NCCN Guidelines for Soft Tissue Sarcoma, available at www.NCCN.org.

Symptoms of chondrosarcoma are usually mild and depend on tumor size and location. Patients with pelvic or axial lesions typically present later in the disease course, as the associated pain has a more insidious onset and often occurs when the tumor has reached a significant size.[80-82] Central chondrosarcomas demonstrate cortical destruction and loss of medullary bone trabeculations on radiographs, as well as calcification and destruction.[81] MRI will show the intramedullary involvement as well as extraosseous extension of the tumor. Secondary lesions arise from preexisting lesions. Serial radiographs will demonstrate a slow increase in size of the osteochondroma or enchondroma. A cartilage “cap” measuring >2 cm on a pre-existing lesion or documented growth after skeletal maturity should raise the suspicion of sarcomatous transformation.[83]

Prognostic Factors

Whether the lesion is primary or secondary, central or peripheral, the anatomic location, histologic grade, and size of the lesion are essential prognostic features.[75,80,84-88] In an analysis of 2890 patients with chondrosarcoma from the SEER database, female sex, a low histologic grade, and local surgical stage were associated with a significant disease-specific survival benefit in the univariate analysis, whereas only grade and stage had significant association with disease-specific survival on multivariate analysis.[89] An epidemiologic study examined the impact of demographic and tumor characteristics on OS.[75] No differences in OS were observed between skeletal and extraskeletal mesenchymal chondrosarcoma, with a 5- and 10-year OS of 51% and 43%, respectively. Anatomic tumor location was a significant prognostic factor, with poorer OS observed among patients with axial versus cranial or appendicular tumor locations. Cranial tumors had different clinical behavior compared with axial and appendicular locations, with data suggesting better OS for younger patients. Prognostic factors were also examined in a retrospective, multi-institutional analysis of 225 patients with low-grade chondrosarcoma.[90] Metastasis-free survival (MFS) probability was 95% at 5 years and 92% at 10 years. A low histologic grade and no recurrence had a significant MFS benefit, but tumor size at diagnosis and surgical margin width had no effect on MFS. In a SEER database analysis, differences in the presence of metastasis were noted among the various chondrosarcoma subtypes.[72] Dedifferentiated (19.8%) followed by mesenchymal (10.6%) chondrosarcoma were most associated with the presence of metastasis on presentation, whereas juxtacortical chondrosarcoma was least associated (2.1%) with the presence of metastasis on presentation.[72] Similarly, median survival was found to be lowest with the dedifferentiated subtype (11 months) and highest with the juxtacortical subtype (97 months).[72]

Treatment

Surgery

Wide excision with negative margins is the preferred primary treatment for patients with large tumors and pelvic localization, irrespective of the grade.[86,91-93] Wide resection with adequate surgical margins is associated

Version 2.2026 © 2025 National Comprehensive Cancer Network© (NCCN©), All rights reserved. NCCN Guidelines® and this illustration may not be reproduced in any form without the express written permission of NCCN.

PLEASE NOTE that use of this NCCN Content is governed by the End-User License Agreement, and you MAY NOT distribute this Content or use it with any artificial intelligence model or tool.
Printed by Galya Basol Kochav on 12/28/2025 10:24:40 AM. Copyright © 2025 National Comprehensive Cancer Network, Inc. All Rights Reserved.

with higher EFS and OS rates in patients with chondrosarcoma of axial skeleton and pelvic girdle. The 10-year OS and EFS rates were 61% and 44%, respectively, for patients who underwent resection with adequate surgical margins compared to the corresponding survival rates of 17% and 0% for those who underwent resection with inadequate surgical margins.[94] Intralesional curettage with adjuvant cryosurgery has been shown to be associated with low rates of recurrence in patients with atypical cartilaginous tumors (formerly known as grade I intracompartmental chondrosarcomas).[95-97] In selected patients with low-grade and less radiographically aggressive, non-pelvic chondrosarcomas, intralesional excision can be used as an alternative to wide excision without compromising outcomes.[98-101] This approach should be restricted to extremity tumors.[102] Intralesional excision is considered the standard treatment for extremity chondrosarcoma tumors. In a meta-analysis comparing outcome in patients with central, atypical cartilaginous tumor of the long bones following either intralesional excision or wide resection, there was little difference in the recurrence-free survival between both groups after 24 months. The rate of major complications was found to be higher following wide resection of the lesion (230 per 1000 vs. 40 per 1000 for intralesional curettage).[103]

Radiation Therapy

Clinical data demonstrate that RT also has a role in the treatment of chondrosarcoma.[61,62] A systematic review of the role of postoperative radiation in skull-base chondrosarcomas compared progression-free survival (PFS) after 3, 5, and 10 years in 1388 patients, of which 186 received surgery only.[104] At 5 years, PFS rates varied from 60% to 92.9% versus 57.1% to 100% for the surgery-only approach compared to the postoperative radiotherapy group, respectively. Recurrence rates ranged from 5.3% to 39.0% in the surgery-only group to 1.5% to 42.9% in the postoperative radiation group. A prospective outcomes study of patients with chondrosarcomas (n = 17) of the sacrum, cervical spine, and thoracolumbar spine found that high-dose external proton beam RT had a 4-year OS rate of 72% and more than half of patients (58%) had local control of disease. Treating patients with RT at the time of diagnosis is suggested to reduce the likelihood of local progression.[105]

Proton beam RT alone or in combination with photon beam RT has been associated with an excellent local tumor control and long-term survival in the treatment of patients with low-grade skull base and cervical spine chondrosarcomas.[106-114] In two separate studies, proton beam RT resulted in local control rates of 92% and 94% in patients with skull base chondrosarcoma.[106,110] Noel and colleagues reported a 3-year local control rate of 92% in 26 patients with chondrosarcoma of the skull base and upper cervical spine treated with surgical resection followed by a combination of proton and photon beam RT.[109] In a larger series involving 229 patients with skull base chondrosarcoma the combination of proton and photon beam RT resulted in 10-year local control rates of 94%.[107] Carbon ion RT has also been reported to result in high local control rates in patients with skull base chondrosarcoma[115,116] and patients with other unresectable chondrosarcomas.[117] SRS has also been evaluated for adjuvant treatment of skull base chondrosarcoma.[118]

Systemic Therapy

Chemotherapy is generally not effective in chondrosarcoma, particularly for the conventional and dedifferentiated subtypes.[119] Mitchell and colleagues reported that adjuvant chemotherapy with cisplatin and doxorubicin was associated with improved survival in patients with dedifferentiated chondrosarcoma.[120] However, this finding could not be confirmed in other studies.[121-124] For example, a SEER database analysis of 185 patients with dedifferentiated chondrosarcoma reported no OS benefit associated with perioperative chemotherapy.[124]

Furthermore, a review of outcomes for 113 patients with mesenchymal chondrosarcoma reported that the addition of chemotherapy was

Version 2.2026 © 2025 National Comprehensive Cancer Network© (NCCN©), All rights reserved. NCCN Guidelines® and this illustration may not be reproduced in any form without the express written permission of NCCN.

PLEASE NOTE that use of this NCCN Content is governed by the End-User License Agreement, and you MAY NOT distribute this Content or use it with any artificial intelligence model or tool.
Printed by Galya Basol Kochav on 12/28/2025 10:24:40 AM. Copyright © 2025 National Comprehensive Cancer Network, Inc. All Rights Reserved.

associated with reduced risk of recurrence and death.[125] A retrospective review of 163 evaluable patients with chondrosarcoma showed the highest objective response rate from chemotherapy was in those with mesenchymal subtype.[126] A single-institution retrospective review of 12 patients with mesenchymal chondrosarcoma who received adjuvant chemotherapy (most commonly ifosfamide/doxorubicin) and/or radiation showed 5-year disease-free survival (DFS) and OS at 68.2% and 88.9%, respectively.[127] Another report from the German study group confirmed that the outcome was better in younger patients with mesenchymal chondrosarcoma who received chemotherapy.[128] However, in the absence of data from prospective randomized trials, the role of chemotherapy in the treatment of chondrosarcomas remains undefined.[129,130]

A multicenter, phase 2, single-arm study in patients with advanced sarcoma evaluated dasatinib, the small-molecule inhibitor of kinases (including SRC family, *BCR::ABL*, c-KIT, and platelet-derived growth factor receptors [PDGFRs] α and β). The Sarcoma Alliance for Research through Collaboration (SARC) coordinated this study, known as SARC009, which included three parallel trials focused on different rare sarcoma histologic types: aggressive sarcoma subtypes, indolent sarcoma subtypes, and gastrointestinal stromal tumors. The indolent substudy included patients with unresectable, recurrent, or metastatic soft tissue or bone sarcoma, which included 33 patients with grade 1 or 2 chondrosarcoma.[131] The primary endpoint was PFS at 6 months using the Choi criteria, which for patients with chondrosarcoma was 47%, just below the 50% cutoff for an active agent. Six patients had objective tumor response and four patients (12%) had stable disease for >1 year, suggesting some tumor control. An editorial published in the same issue of *Cancer* compared results of this and other trials using different chemotherapies for chondrosarcoma and found improved PFS at 6 months with dasatinib.[132]

Similarly, pazopanib is an oral, multikinase inhibitor with antiangiogenic activity. A single-arm, multicenter, phase 2 study evaluated the safety and efficacy of pazopanib in 42 patients with unresectable or metastatic CCS. The primary endpoint of the study was disease control rate (DCR) at week 16 and the secondary endpoints included PFS and OS. Overall, treatment with pazopanib resulted in a DCR of 43% at 16 weeks, a median PFS of 7.9 months, and a median OS of 17.6 months. Prior reports of the antitumor activity of pazopanib (including a case report and a small cohort study) in unresectable or metastatic chondrosarcoma are also favorable.[65]

A multicenter, open-label, dose-escalation and -expansion phase 1 trial in patients with *IDH1*-mutant advanced solid tumors, including 21 patients with advanced chondrosarcoma, evaluated the response to ivosidenib, a selective IDH1 inhibitor. Median PFS was 5.6 months (95% CI, 1.9–7.4 months), PFS at 6 months was 39.5%, and 52% of patients had stable disease. All patients demonstrated decreased plasma 2-hydroxyglutarate (2-HG) levels following treatment.[133]

The multicenter, single-arm, phase 2 IMMUNOSARC trial evaluated the efficacy of the tyrosine kinase inhibitor (TKI) sunitinib in combination with nivolumab in adult patients with advanced bone sarcomas.[134] The primary endpoint was PFS at 6 months and was evaluated based on radiologic review. Secondary endpoints included OS and overall response rate (ORR). Of the 38 evaluable patients, 14 (35%) had chondrosarcoma (10 CCS, four dedifferentiated [DDCS]). Median PFS was 9.5 months (95% CI, 0–19.3) for those with CCS and 1.8 months (95% CI, NA) for individuals with DDCS. Median OS and ORR by RECIST criteria (among all histologies) were 11.9 months and 5%, respectively. One individual with DDCS had a complete response (>4 years) and of the two individuals with partial responses, one had DDCS.

One study found that 41% of dedifferentiated chondrosarcomas were positive for programmed death ligand 1 (PD-L1) expression;[135] however,

Version 2.2026 © 2025 National Comprehensive Cancer Network© (NCCN©), All rights reserved. NCCN Guidelines® and this illustration may not be reproduced in any form without the express written permission of NCCN.

PLEASE NOTE that use of this NCCN Content is governed by the End-User License Agreement, and you MAY NOT distribute this Content or use it with any artificial intelligence model or tool.
Printed by Galya Basol Kochav on 12/28/2025 10:24:40 AM. Copyright © 2025 National Comprehensive Cancer Network, Inc. All Rights Reserved.

the efficacy data supporting the use of programmed cell death protein 1 (PD-1)/PD-L1 inhibitors as monotherapy in the management of these tumors are limited. The activity and safety of pembrolizumab was evaluated in a two-cohort, single-arm, open-label, phase 2 study that included 40 patients with advanced bone sarcomas.[136] At median follow-up (17.8 months) one of the five patients with chondrosarcoma (dedifferentiated) had a partial response. Similarly, a retrospective review of patients with relapsed metastatic/unresectable soft tissue or bone sarcomas (n = 28) also showed a partial response to nivolumab in one patient with dedifferentiated chondrosarcoma.[137]

NCCN Recommendations

The histologic grade and tumor locations are the most important variables that determine the choice of primary treatment for chondrosarcoma. Radiologic features and size should also be considered when determining local treatment.

Intralesional excision with or without a surgical adjuvant is the primary treatment option for patients with atypical cartilaginous lesions; observation is also an option.[99,100]

High-grade (grade II, III), clear cell, extracompartmental, grade I axial tumors or low-grade extracompartmental appendicular lesions, if resectable, should be treated with wide excision obtaining negative surgical margins. Wide excision should provide negative surgical margins and may be achieved by either limb-sparing surgery or amputation.

Postoperative treatment with proton and/or photon beam RT may be useful for patients with tumors in an unfavorable location not amenable to resection, especially in chondrosarcomas of the skull base and axial skeleton.[61,62] RT can be considered for patients with borderline resectable or unresectable tumors as a primary treatment option. However, since there are not enough data to support the use of RT in patients with chondrosarcoma, the Panel has included this option as a category 2B recommendation.

Patients with mesenchymal chondrosarcomas may be treated with systemic therapy regimens used for Ewing sarcoma (category 2B), doxorubicin monotherapy, or doxorubicin/ifosfamide/mesna.

Providers may consider treating those with dedifferentiated chondrosarcomas as osteosarcoma (category 2B). Regimens used to treat osteosarcoma can be considered as preferred systemic therapy options. Single-agent pazopanib, sunitinib, pembrolizumab, or nivolumab have been included as options for dedifferentiated chondrosarcomas, in addition to sunitinib and nivolumab combination therapy.

There are no standard chemotherapy options for CCS grades 1–3 that are recommended by the NCCN Panel. However, ivosidenib can be considered as an option for certain patients with chondrosarcoma with *IDH1* mutations. Next-generation sequencing (NGS) or targeted exon sequencing can be used to detect *IDH1* mutations and other potential targeted therapy opportunities. See the *Biomarker Testing and Additional Treatment Options* section.

Metastatic Disease

Metastatic chondrosarcoma that is not dedifferentiated or mesenchymal either after recurrence or at presentation can be classified as oligometastatic or widespread disease. In general, patients with oligometastatic disease are amenable to local control (potentially rendering it disease free), such as with surgical excision or RT, or treated as part of a clinical trial (goal is disease free/cure; more likely to proceed with surgery or radiation).

For oligometastatic disease that is resectable, NCCN recommends surgical excision of all sites of disease, if possible. For oligometastatic

Version 2.2026 © 2025 National Comprehensive Cancer Network© (NCCN©), All rights reserved. NCCN Guidelines® and this illustration may not be reproduced in any form without the express written permission of NCCN.

PLEASE NOTE that use of this NCCN Content is governed by the End-User License Agreement, and you MAY NOT distribute this Content or use it with any artificial intelligence model or tool.
Printed by Galya Basol Kochav on 12/28/2025 10:24:40 AM. Copyright © 2025 National Comprehensive Cancer Network, Inc. All Rights Reserved.

disease that is unresectable, consider RT that may include ablative therapy. For widespread disease, NCCN recommends considering RT, surgery, and/or ablative therapies for symptomatic sites, systemic therapy, or clinical trial. Dasatinib and pazopanib are included as category 2A treatment options for patients with metastatic or widespread chondrosarcoma. NCCN recommends that multigene panel testing (MGPT) with a validated and/or FDA-approved assay should be considered for patients with metastatic chondrosarcoma to identify potential targeted therapy opportunities. In addition, testing for tumor mutational burden (TMB) and mismatch repair (MMR)/microsatellite instability (MSI) as determined by a validated and/or FDA-approved assay should be considered. See *Biomarker Testing and Additional Treatment Options* below.

Surveillance

Surveillance for atypical cartilaginous tumors consists of a physical exam and imaging. Imaging with radiographs of the primary site, and/or cross-sectional imaging (CT with contrast or MRI with and without contrast) are recommended every 6 to 12 months for 2 years and then yearly as clinically indicated.

Surveillance for high-grade (grade II, III), clear cell, extracompartmental, grade I axial tumors or low-grade extracompartmental appendicular lesions consists of a physical exam, radiographs of the primary site, and/or cross-sectional imaging (CT with contrast or MRI with and without contrast) as clinically indicated as well as chest imaging based on physician's concern for risk of recurrence. Chest imaging should occur every 3 to 6 months (may include CT with or without contrast at least biannually) for the first 5 years and yearly thereafter for a minimum of 10 years as clinically indicated, as late metastases and recurrences after 5 years are more common with chondrosarcoma than with other sarcomas.[85] Functional assessment should be performed at every visit.

Relapsed Disease

For local recurrence of atypical cartilaginous tumors, workup including imaging of primary site, chest imaging, and biopsy to confirm diagnosis should be performed. Bone scans are optional. If there is malignant transformation, treat as described below.

For high-grade (grade II, III), clear cell, extracompartmental, grade I axial tumors or low-grade extracompartmental appendicular lesions, local recurrence should be treated with wide excision if the lesions are resectable. If there are positive margins, RT (category 2B) or re-excision to achieve negative surgical margins should be considered. If there are negative surgical margins, observation is recommended. Unresectable recurrences are treated with RT (category 2B). A study in 25 patients demonstrated effective local control and low acute toxicity with carbon ion RT in patients with recurrent skull base chordoma or chondrosarcoma.[138] Patients with systemic recurrence should follow the recommendations described above for *Metastatic Disease*.

Chordoma

Chordomas arise from the embryonic remnants of the notochord and are more commonly diagnosed in adults aged 40 to 75 years.[139] Chordomas predominantly arise in the axial skeleton, with the sacrum (50%–60%), skull base (25%–35%), and spine (15%) being the most common primary sites.[8,9,140] Chordomas are traditionally classified by the WHO into three histologic variants: conventional, chondroid, and dedifferentiated. Conventional chordomas are the most common histologic subtype characterized by the absence of cartilaginous or mesenchymal components. Chondroid chordomas present with histologic features of chordoma and cartilage elements, accounting for 5% to 15% of all chordomas. Dedifferentiated chordomas constitute about 2% to 8% of all chordomas and have features of high-grade pleomorphic spindle cell soft tissue sarcoma and an aggressive clinical course.[140] An additional subset

Version 2.2026 © 2025 National Comprehensive Cancer Network© (NCCN©), All rights reserved. NCCN Guidelines® and this illustration may not be reproduced in any form without the express written permission of NCCN.

PLEASE NOTE that use of this NCCN Content is governed by the End-User License Agreement, and you MAY NOT distribute this Content or use it with any artificial intelligence model or tool.
Printed by Galya Basol Kochav on 12/28/2025 10:24:40 AM. Copyright © 2025 National Comprehensive Cancer Network, Inc. All Rights Reserved.

of chordoma has been identified in children. Poorly differentiated chordoma is characterized molecularly by the absence of *SMARCB1* expression. The protein encoded by *SMARCB1* is a chromatin remodeling agent and its absence is also implicated in the pathogenesis of some sarcomas, including but not limited to epithelioid sarcoma, malignant rhabdoid tumor, and epithelioid malignant peripheral nerve sheath tumor (MPNST). It is reported that poorly differentiated chordoma may be more common in the pediatric population and show a predilection for occurrence in the skull base and cervical spine. Although further research is warranted, poorly differentiated chordoma is considered to be more aggressive than either the conventional or chondroid variants with a poorer OS.[141,142] Chordomas of the spine and sacrum present with localized deep pain or radiculopathies, whereas cervical chordomas can cause airway obstruction or dysphagia and might present as an oropharyngeal mass. Neurologic deficit is more often associated with chordomas of the skull base and mobile spine than chordomas of sacrococcygeal region.[8,143] A review of 47 patients with skull base chordomas suggested that male sex was associated with worse PFS and OS.[144]

Workup

Initial workup should include H&P examination with adequate cross-sectional imaging of primary site (eg, MRI, CT), screening MRI of spinal axis, and C/A/P CT with contrast. Skull base to mid-thigh FDG-PET/CT or bone scan (if FDG-PET/CT is negative) can be considered for unusual cases. Benign notochordal cell tumors (BNCTs) are considered precursors to chordomas and do not require surgical management.[145-147] CT and MRI may be useful in distinguishing BNCTs from chordomas.[148,149]

For skull base chordomas, CT is useful to delineate bone destruction and the presence of calcifications, whereas MRI is the modality of choice to define the tumor margin from brain, characterize the position and extension of tumors into the adjacent soft tissue structures, and visualize blood vessels.[150-152] For sacrococcygeal chordomas, CT and MRI are useful to assess the soft tissue involvement, calcifications, and epidural extension.[153-155] MRI provides more precise and superior contrast with surrounding soft tissues compared with CT and is helpful to assess recurrent or metastatic lesions.[153,154] CT is also of particular importance to assess bony involvement, calcifications, and soft tissue and epidural extension of spinal chordomas, whereas MRI is the best imaging modality to detect tumor extension, cord compression, local recurrence, and residual tumor in the surgical scar tissue after surgical resection.[156,157] CT is also useful in planning the reconstruction of the resistant osseous defect in tumors of the proximal sacrum.

Treatment

Surgery

Wide excision with adequate margins is the preferred primary treatment for patients with resectable chordoma of the sacrococcygeal and mobile spine.[158,159] Data from two retrospective cohort studies suggest that surgery is associated with improved OS in patients with chordoma.[159,160] Several other reports have confirmed the prognostic significance of wide surgical margins, in terms of relapse-free survival (RFS) and OS, in patients with chordomas of the sacrum,[161-164] skull base,[165-171] and spine.[163,172,173] Among patients with chordoma of the mobile spine, only margin-free en bloc resection was associated with continuous DFS with a follow-up of >5 years; 12 of 18 patients were continuously disease-free at an average of 8 years after en bloc resection, whereas all patients who were treated with intralesional excision experienced recurrences in <2 years.[172] Following en-bloc resection a local recurrence rate of 14.8% and distant disease recurrence rate of 7.4% in 27 patients with chordomas of the sacrum were reported based on a single-center retrospective study.[174] Positive or <2 mm resection margins were associated with disease progression in 40.7% of patients. In a meta-analysis of 33 noncomparative studies evaluating the management of sacrococcygeal chordomas, the

Version 2.2026 © 2025 National Comprehensive Cancer Network© (NCCN©), All rights reserved. NCCN Guidelines® and this illustration may not be reproduced in any form without the express written permission of NCCN.

PLEASE NOTE that use of this NCCN Content is governed by the End-User License Agreement, and you MAY NOT distribute this Content or use it with any artificial intelligence model or tool.
Printed by Galya Basol Kochav on 12/28/2025 10:24:40 AM. Copyright © 2025 National Comprehensive Cancer Network, Inc. All Rights Reserved.

overall mortality rate was found to be lowest with surgical resection followed by adjuvant RT (16%) when compared to either surgical resection (28%) or RT (43%) alone. Additionally, the PFS at 60-month follow-up was higher after surgical resection with adjuvant RT (74%) than when compared to only surgery (55%) or only RT (36%).[175]

For individuals with resectable skull base/clival chordomas, intralesional excision (with maximal safe excision) is recommended.[143] One study found that aggressive microsurgical resection is associated with long-term, tumor-free survival with good functional outcome in patients with cranial base chordomas; gross total removal was achieved in 72% of patients resulting in local control rates of 50%.[166] In a 10-year meta-analysis that included 802 patients with skull base chordoma, patients with incomplete resection were 3.83 times more likely to experience a recurrence at 5 years than patients with complete resection.[169,170]

Radiation Therapy

RT (preoperative, postoperative, or intraoperative) is used in combination with surgery to improve local control and DFS for patients with resectable chordomas. Various retrospective studies and case series have demonstrated improved local control and DFS with combined surgical/RT approaches for treating spinal/sacral[105,112,176-180] and clival/skull base chordomas.[165,178,181-185]

A retrospective review analyzed the role of RT following surgical resection in 1478 patients with skull base, sacral, and mobile spine chordomas.[186] In those with positive surgical margins, the 5-year survival rate was significantly higher among those who received adjuvant RT than the patients who received surgery alone (82.3% vs. 70.6%; $P = .03$). In contrast, adjuvant RT following surgery did not improve the survival rate among patients with negative surgical margins. A retrospective review evaluated outcomes in 37 patients with craniospinal chordoma who underwent subtotal resection (STR) (n = 23), gross total resection (GTR) (n = 12), or biopsy (n = 2) with or without adjuvant RT.[143] Results showed the best long-term survival outcomes among individuals who underwent GTR. Adjuvant RT following STR improved long-term survival; however, it had no effect on patients who underwent GTR.

Particle beam RT (either alone or in combination with photon beam RT) with high-energy protons[106-109,112,177,184,187-193] or carbon ions[115,116,193-198] resulted in local control rates ranging from 46% to 92% in patients with skull base as well as extracranial chordomas involving the spine and sacrum. Carbon ion RT also resulted in favorable outcomes for individuals with skull-base chordomas regarding local control, OS, and toxicity profile.[199] The 5- and 10-year local control rates were 80% and 56%, respectively.

A prospective trial of high-dose photon/proton RT in 50 patients with bone sarcomas of the spine (n = 29 chordoma, 14 chondrosarcoma, 7 other histologies) resulted in 5- and 8-year actuarial local control rates of 94% and 85% for primary tumors and 81% and 74% for primary and locally recurrent tumors. The 8-year actuarial risk of grades 3–4 RT toxicity was 13%.[112] A subsequent retrospective review of 126 patients with spinal/sacral chordoma who received high-dose proton therapy revealed 5-year OS and local control rates of 81% and 62%, respectively.[177] A retrospective analysis of 40 patients with unresected chordoma treated with photon/proton RT showed a 5-year local control rate and OS of 85.4% and 81.9%, respectively.[200] Similarly, a phase I/phase II trial with 20 patients confirmed to have non-metastatic chordoma or chondrosarcoma treated with proton RT also reported favorable results with a 3-year local control rate of 86% and a PFS of 81%.[201] A meta-analysis of 25 studies evaluating the 3-, 5-, and 10-year OS rates of conformal RT (CRT), SRT, proton therapy, and carbon ion therapy found that the OS rates were higher for SRT, proton therapy, and carbon ion therapy when compared to CRT.[202] Specialized techniques such as IMRT and SRS/SRT have also

Version 2.2026 © 2025 National Comprehensive Cancer Network© (NCCN©), All rights reserved. NCCN Guidelines® and this illustration may not be reproduced in any form without the express written permission of NCCN.

PLEASE NOTE that use of this NCCN Content is governed by the End-User License Agreement, and you MAY NOT distribute this Content or use it with any artificial intelligence model or tool.
Printed by Galya Basol Kochav on 12/28/2025 10:24:40 AM. Copyright © 2025 National Comprehensive Cancer Network, Inc. All Rights Reserved.

been associated with good local control rates in cranial as well as extracranial chordomas.[113,203-207]

Systemic Therapy

Chordomas are typically not sensitive to conventional cytotoxic chemotherapy.[208] Several signal transduction pathways including PDGFR, epidermal growth factor receptor (EGFR), and mammalian target of rapamycin (mTOR) have been implicated in the pathogenesis of chordomas, leading to the development of targeted therapies.[209-211]

In a phase II trial of 56 patients with advanced chordoma treated with imatinib, a TKI, 70% of patients had stable disease. The clinical benefit rate (CBR) as determined by RECIST criteria (complete response + partial response and stable disease ≥6 months) was 64%, and the median PFS in the intention-to-treat population was 9 months.[212] Imatinib in combination with cisplatin or sirolimus has also been effective in a small series of patients with advanced chordoma resistant to prior imatinib therapy.[213,214] A retrospective study of imatinib in advanced, progressive, and inoperable chordoma achieved stable disease in 74% of patients, with a median PFS of 9.9 months.[215]

The efficacy of EGFR inhibitors such as erlotinib and lapatinib has also been demonstrated in patients with advanced chordoma resistant to imatinib.[216-218] In a phase II study of 18 patients with locally advanced and metastatic chordoma, lapatinib induced partial response in 33% of patients and 39% of patients had stable disease, based on Choi response criteria, whereas all patients had stable disease based on RECIST criteria.[218] The median PFS was 6 months and 8 months (with a CBR of 22%) based on Choi and RECIST criteria, respectively.

The multikinase inhibitor sorafenib is included as a systemic therapy option based on data from a phase II trial in 27 patients with advanced/metastatic chordoma. In this trial, the intent-to-treat best objective response was 1/27 (3.7%; 95% CI, 0.1%–19.0%), 9-month PFS was 73.0% (95% CI, 46.1–88.0), and 12-month OS was 86.5% (95% CI, 55.8–96.5).[219,220]

Dasatinib is also included as a systemic therapy option based on data from the SARC009 indolent substudy that included 32 patients with unresectable, recurrent, or metastatic chordoma.[131] The primary endpoint was PFS at 6 months using the Choi criteria, which for patients with chordoma was 54%. For patients with chordoma, the median PFS was 6.3 months, and the 5-year OS was 18%. The authors also compared reported patient outcomes in selected phase 2 studies in patients with chordomas and no substantial differences in ORR, median PFS, or 6-month PFS compared with imatinib or lapatinib treatment. The inclusion of sunitinib in the guidelines is based on data from a phase II study in which 44% (4/9) of patients with advanced chordoma treated with sunitinib achieved stable disease for at least 16 weeks.[221]

The Panel included pembrolizumab as a systemic therapy option based on data from the non-randomized, open-label, phase II basket trial that evaluated the efficacy of pembrolizumab in 97 patients with rare and ultra-rare sarcomas refractory or resistant to standard therapy.[222] Of the 34 patients with chordoma, an objective response was reported in 4 individuals at week 12 and the median PFS was 6.1 months (95% CI, 4.6–11.5).

NCCN Recommendations

Tumor location is the most important variable in determining the choice of primary treatment for patients with conventional (including chondroid) chordomas. Dedifferentiated and poorly differentiated chordomas are usually managed as described in the NCCN Guidelines for Soft Tissue Sarcoma, available at www.NCCN.org.

Version 2.2026 © 2025 National Comprehensive Cancer Network© (NCCN©), All rights reserved. NCCN Guidelines® and this illustration may not be reproduced in any form without the express written permission of NCCN.

PLEASE NOTE that use of this NCCN Content is governed by the End-User License Agreement, and you MAY NOT distribute this Content or use it with any artificial intelligence model or tool.
Printed by Galya Basol Kochav on 12/28/2025 10:24:40 AM. Copyright © 2025 National Comprehensive Cancer Network, Inc. All Rights Reserved.

Wide excision with or without adjuvant RT is a primary treatment option for patients with resectable conventional (including chondroid) chordomas of the sacrum and mobile spine.[158,159] Intralesional excision with or without adjuvant RT (followed by contrast-enhanced MRI to assess the adequacy of resection) is the treatment of choice for patients with resectable skull base/clival tumors of conventional or chondroid histology.[143] Maximal safe excision is recommended when appropriate.[168] Adjuvant treatment with RT can be considered for large extracompartmental tumors or for positive surgical margins following resection. Postoperative RT has been associated with improved local control and DFS following surgery with macroscopic surgical margins or intralesional excision.[176,178,183,223,224] Re-excision, if necessary, can be considered for skull base tumors with positive surgical margins.

Definitive RT is the primary treatment option for patients with unresectable chordomas, irrespective of the location of the tumor.

Surveillance

Surveillance consists of a physical exam, imaging (ie, x-ray, MRI with or without contrast ± CT with contrast) of the primary site (timing and modality as clinically indicated) for up to 10 years, and chest imaging (every 6 months for 5 years and annually thereafter; may include CT annually; chest CT may be done with or without contrast as clinically indicated).

Relapsed Disease

Chordomas are characterized by a high rate of local recurrence, and distant metastases to lungs, bone, soft tissue, lymph nodes, liver, and skin have been reported in up to 40% of patients with local recurrence.[161,187,225-227] Among patients with recurrent chordomas of skull base and spine, Fagundes and colleagues reported a higher 2-year actuarial OS rate for patients treated with STR than those who received supportive care only (63% and 21%, respectively; $P = .001$).[187] However, some studies have reported that surgery and RT are associated with lower local control rates for recurrent tumors than for primary tumors in patients with sacral chordomas.[189,205] A study of 25 patients demonstrated effective local control and low acute toxicity with carbon ion RT in patients with recurrent skull base chordoma or chondrosarcoma.[138]

Patients with recurrent disease can be treated with surgery and/or RT[228] and/or systemic therapy and/or ablation (local recurrence only). The guidelines include imatinib (with or without cisplatin or sirolimus), dasatinib, pembrolizumab, sunitinib, erlotinib, lapatinib (for patients with EGFR-positive disease), and sorafenib as systemic therapy options for patients with recurrent tumors. Enrollment in a clinical trial is included as an option for recurrent (local or metastatic) disease and/or best supportive care for metastatic recurrence only. MGPT with a validated and/or FDA-approved assay should be considered for patients with recurrent chordoma to determine targeted therapy opportunities. See *Biomarker Testing and Additional Treatment Options* below.

Ewing Sarcoma

Ewing sarcoma is characterized by the fusion of the *EWS* gene (*EWSR1*) on chromosome 22q12 with various members of the ETS gene family (*FLI1*, *ERG*, *ETV1*, *ETV4,* and *FEV*).[12,13] The *EWSR1::FLI1* fusion transcript resulting from the fusion of *EWSR1* and *FLI1* on chromosome 11 and the corresponding chromosomal translocation, t(11;22)(q24;q12), is identified in about 85% of patients with Ewing sarcoma.[12,15] In 5% to 10% of cases, *EWSR1* is fused with other members of the ETS gene family. In rare cases, *FUS* can substitute for *EWSR1* resulting in fusion transcripts with no *EWSR1* rearrangement [*FUS*::*ERG* fusion transcript resulting from the translocation t(16;21)(p11;q24) or *FUS*::*FEV* fusion transcript resulting from the translocation t(2;16)(q35;p11)].[229,230] Overall, 90% of Ewing sarcomas will have one of four cytogenetic translocations.

Version 2.2026 © 2025 National Comprehensive Cancer Network© (NCCN©), All rights reserved. NCCN Guidelines® and this illustration may not be reproduced in any form without the express written permission of NCCN.

PLEASE NOTE that use of this NCCN Content is governed by the End-User License Agreement, and you MAY NOT distribute this Content or use it with any artificial intelligence model or tool.
Printed by Galya Basol Kochav on 12/28/2025 10:24:40 AM. Copyright © 2025 National Comprehensive Cancer Network, Inc. All Rights Reserved.

Ewing sarcoma is also characterized by the strong expression of cell surface glycoprotein MIC2 (CD99).[231,232] The expression of CD99 may be useful in the differential diagnosis of Ewing sarcoma from other small round-cell neoplasms, although it is not exclusively specific to these tumors.[233] Similar in morphology with various molecular signatures, other primary round cell sarcomas of bone, previously referred to as Ewing-like sarcomas, are a heterogenous group of tumors that primarily affect the pediatric and adolescent population.[234] These tumors include: *CIC*-rearranged sarcomas (eg, *CIC::DUX4*), *BCOR*-rearranged sarcomas, and round cell sarcomas with *EWSR1* fusions with non-ETS genes.[235]

Typically, Ewing sarcoma occurs in AYAs, with an incidence of 1 case per 1.5 million.[236] The most common primary sites are the pelvic bones, femur, and the bones of the chest wall, although any bone may be affected.[26] However, in approximately 20% of cases, these tumors emerge from extraosseous tissue.[236] When arising in a long bone, the diaphysis is the most frequently affected site.[26] On imaging, the bone appears mottled. Periosteal reaction is classic and is referred to as “onion skin” by radiologists.

Patients with Ewing sarcoma, as with most patients with bone sarcomas, seek attention because of localized pain or swelling. Unlike other bone sarcomas, constitutional symptoms such as fever, weight loss, and fatigue are occasionally noted at presentation. Abnormal laboratory studies may include elevated serum LDH and leukocytosis.

Prognostic Factors

The important indicators of favorable prognosis include a distal/peripheral site of primary disease, tumor volume <100 mL, normal LDH level at presentation, and the absence of metastatic disease at the time of presentation.[237-244] Ewing sarcoma in the spine and sacrum is associated with significantly worse outcome and prognosis than primary Ewing sarcoma in other sites.[245] In a systematic review, Bosma and colleagues also reported tumor size (diameter >8 cm) and histologic response to initial systemic treatment (≥90% necrosis) to be important prognostic variables.[246] Nevertheless, metastatic disease at presentation is the most significant adverse prognostic factor observed in those with Ewing sarcoma, as it is for other bone sarcomas.[32,241,247] The lungs, bone, and bone marrow are the most common sites of metastasis. In a retrospective analysis of 975 patients from the EICESS Study Group, 5-year RFS was 22% for patients with metastatic disease at diagnosis compared with 55% for patients without metastases at diagnosis.[32] Among patients with metastases, there was a trend for better survival for those with lung metastases compared to those with bone metastases or a combination of lung and bone metastases.[32,248] Metastases to uncommon sites (ie, brain, liver, spleen) were associated with a worse prognosis in a retrospective study of 30 patients.[249] Poor histologic/radiologic response to chemotherapy has also been identified as an adverse prognostic factor in patients with localized non-metastatic disease,[240,244,250,251] even when chemotherapy was followed by complete resection.[252]

The results of the Intergroup Ewing’s Sarcoma Study (IESS) analyzing the clinicopathologic features of 303 cases of Ewing sarcoma showed that patients with primary tumors in pelvic bones have lower survival rates compared with patients with lesions in distal bones of the extremities.[253] In an analysis of 53 patients (24 adult and 29 pediatric) with Ewing sarcoma treated with chemotherapy, Gupta and colleagues identified pelvic disease and time to local therapy as significant prognostic factors associated with EFS in a multivariate analysis.[254] In another retrospective analysis of patients with Ewing sarcoma from a large population-based cancer registry, Lee and colleagues determined

Version 2.2026 © 2025 National Comprehensive Cancer Network© (NCCN©), All rights reserved. NCCN Guidelines® and this illustration may not be reproduced in any form without the express written permission of NCCN.

PLEASE NOTE that use of this NCCN Content is governed by the End-User License Agreement, and you MAY NOT distribute this Content or use it with any artificial intelligence model or tool.
Printed by Galya Basol Kochav on 12/28/2025 10:24:40 AM. Copyright © 2025 National Comprehensive Cancer Network, Inc. All Rights Reserved.

that adult age, Hispanic ancestry, metastatic disease, large tumor size, and low socioeconomic status are poor prognostic factors for OS.[255]

Workup

If Ewing sarcoma is suspected as a diagnosis, the patient should undergo complete staging prior to biopsy. This should include CT of the chest with or without contrast as clinically indicated (non-contrast CT is recommended for restaging); contrast-enhanced; MRI with or without CT of the primary site; whole body FDG-PET/CT (preferred) and/or bone scan; and possibly bone marrow biopsy and/or screening MRI with or without contrast of the spine and pelvis. In a systematic review and meta-analysis, Treglia and colleagues reported that the combination of FDG-PET/CT with conventional imaging is a valuable tool for the staging and restaging of Ewing sarcoma, with 96% sensitivity and 92% specificity.[256] Another systematic review indicated that FDG-PET without bone marrow biopsy may be considered for staging in newly diagnosed Ewing sarcoma patients, as FDG-PET demonstrated 100% sensitivity and 96% specificity based on pooled patient data from four studies.[257] Results from ACRIN 6660, a multicenter prospective cohort study conducted by the American College of Radiology Imaging Network (ACRIN) comparing whole-body MRI and conventional imaging in pediatric patients with common malignant tumors (including Ewing sarcoma), found that the noninferior accuracy for diagnosis of distant metastasis was not established for the use of whole-body MRI compared with conventional imaging.[258] However, the accuracy of whole-body MRI was higher for patients with solid tumors compared to those with lymphomas (P = .006).

Cytogenetic and/or biomarker testing of the biopsy specimen should be performed to evaluate t(11;22) or other less common translocations. MGPT has also been used to identify potentially actionable translocations in patients with sarcoma.[259,260] In the case that pathologic workup of targeted polymerase chain reaction (PCR), fluorescence in situ hybridization (FISH), or cytogenetics is negative, MGPT or other fusion panels for Ewing sarcoma should be considered to identify translocations, including atypical translocations.

Preliminary reports suggest that *EWSR1::FLI1* translocation is associated with a better prognosis than other variants.[261-263] However, reports from the EURO-EWING 99 study and the Children's Oncology Group study suggest that with currently available effective therapies, patients with Ewing sarcoma have similar outcomes, regardless of fusion subtype in contrast to previous reports.[264,265] In addition to *EWSR1, FUS* should be considered as a fusion gene partner in the molecular diagnosis to identify the rare cases of Ewing sarcoma with *FUS*::*ERG* or *FUS*::*FEV* fusion transcripts.[229,230] Since serum LDH has been shown to have prognostic value as a tumor marker, the guidelines have included this test as part of initial evaluation. Since serum LDH has been shown to have prognostic value as a tumor marker, the guidelines have included this test as part of initial evaluation.

Fertility consultation should be offered. See the *Diagnostic Workup* section above.

Treatment

Chemotherapy

Multiagent chemotherapy regimens including VDC (vincristine, doxorubicin, and cyclophosphamide) alternating with IE (ifosfamide and etoposide) have been shown to be effective in patients with localized Ewing sarcoma in single- as well as multi-institution collaborative trials in the United States and Europe. Multiagent chemotherapy for at least 9 weeks is recommended prior to surgery to downstage the tumor and increase the probability of achieving a complete resection with microscopically negative margins. Data support the use of adjuvant

Version 2.2026 © 2025 National Comprehensive Cancer Network© (NCCN©), All rights reserved. NCCN Guidelines® and this illustration may not be reproduced in any form without the express written permission of NCCN.

PLEASE NOTE that use of this NCCN Content is governed by the End-User License Agreement, and you MAY NOT distribute this Content or use it with any artificial intelligence model or tool.
Printed by Galya Basol Kochav on 12/28/2025 10:24:40 AM. Copyright © 2025 National Comprehensive Cancer Network, Inc. All Rights Reserved.

chemotherapy following surgical resection, resulting in improved RFS and OS.[266-270] Surgical resection with or without RT is used for local control following chemotherapy.

The addition of ifosfamide, alone or in combination with etoposide to standard chemotherapy, was evaluated in patients with newly diagnosed, non-metastatic Ewing sarcoma.[268,271-275] In the Pediatric Oncology Group-Children's Cancer Group (POG-CCG) study (INT-0091), 398 patients with non-metastatic Ewing sarcoma were randomized to receive chemotherapy with VACD (vincristine, dactinomycin, cyclophosphamide, and doxorubicin) alone or VACD-IE (VACD alternating with ifosfamide and etoposide) for a total of 17 cycles.[268] The 5-year EFS rate was significantly higher in the VACD-IE group than in the VACD alone group (69% and 54%, respectively; $P = .005$). The 5-year OS rate was also significantly better among patients in the VACD-IE group (72% and 61%, respectively; $P = .01$). VACD-IE also was associated with lower incidences of local disease progression (11%) compared with VACD (30%) irrespective of the type of local control therapy; 5-year cumulative incidences of local disease progression were 30% in the VACD arm compared with 11% in the VACD-IE arm.[276]

While dose escalation of alkylating agents in the VDC-IE regimen did not improve the outcome for patients with localized disease,[277] chemotherapy intensification through interval compression improved outcome in patients with localized disease.[278] In a randomized trial for patients <50 years with localized Ewing sarcoma (n = 568), Womer and colleagues reported that VDC-IE given on an every-2-week schedule was found to be more effective than VDC-IE given on an every-3-week schedule, with no increase in toxicity; median 5-year EFS was 73% and 65%, respectively.[278]

The EURO EWING 2012 (EE2012) was a randomized analysis conducted to compare the induction and consolidation regimens for newly diagnosed Ewing sarcoma in both the United States and Europe.[279] Six hundred forty patients between the ages of 2 and 49 years were randomized to two treatment arms. Treatment arm A received the European regimen: VIDE (vincristine, ifosfamide, doxorubicin, and etoposide) induction therapy followed by vincristine, actinomycin D, with ifosfamide or cyclophosphamide, or busulfan and melphalan consolidation. Treatment arm B received the U.S. regimen: compressed VDC-IE induction followed by VC (vincristine and cyclophosphamide) or vincristine, actinomycin D, and ifosfamide, with busulfan and melphalan consolidation. The primary endpoint of the study was EFS while the secondary endpoints were OS and toxicity. EFS at 3 years was 61% and 67% for treatment arms A and B, respectively (adjusted hazard ratio [HR] 0.71 [95% credible interval 0.55–0.92 in favor of treatment arm A]). Grade 3–5 febrile neutropenia occurred in 74% of participants in treatment arm A and in 58% of participants in treatment arm B. More participants in treatment arm A required at least one platelet transfusion; however, more participants in treatment arm B required more blood transfusions. The VDC-IE regimen proved superior to the European regimen in terms of EFS and OS with similar toxicity profiles.

IESS-I and IESS-II showed that RT plus adjuvant chemotherapy with VACD was superior to VAC in patients with localized non-metastatic disease.[267] The 5-year RFS rates were 60% and 24% for VACD and VAC, respectively ($P < .001$). The corresponding OS rates were 65% and 28% ($P < .001$).

In the INT-0091 study, which included 120 patients with metastatic disease, there was no significant difference in the EFS and OS rates between the VACD-IE and VACD regimens.[268] The 5-year EFS rate was 22% for both regimens and the 5-year OS rate was 34% and 35% for the VACD-IE and VACD groups, respectively. In a study of 68 patients (44 patients with locoregional disease and 24 patients with distant

Version 2.2026 © 2025 National Comprehensive Cancer Network© (NCCN©), All rights reserved. NCCN Guidelines® and this illustration may not be reproduced in any form without the express written permission of NCCN.

PLEASE NOTE that use of this NCCN Content is governed by the End-User License Agreement, and you MAY NOT distribute this Content or use it with any artificial intelligence model or tool.
Printed by Galya Basol Kochav on 12/28/2025 10:24:40 AM. Copyright © 2025 National Comprehensive Cancer Network, Inc. All Rights Reserved.

metastases), Kolb and colleagues reported 4-year EFS and OS rates of 82% and 89%, respectively, for patients with locoregional disease treated with intensive chemotherapy (doxorubicin and vincristine with or without high-dose cyclophosphamide) followed by ifosfamide and etoposide.[273] In patients with distant metastases the corresponding survival rates were 12% and 18%, respectively. Miser and colleagues also reported similar findings in patients with Ewing sarcoma with metastases at diagnosis.[280]

The EICESS-92 study investigated whether cyclophosphamide has efficacy similar to ifosfamide in patients with standard-risk Ewing sarcoma (small localized tumors) and whether the addition of etoposide to a regimen already containing ifosfamide improves survival in patients with high-risk disease (large tumors or metastatic disease at diagnosis).[281] Patients with standard-risk disease were randomly assigned to VAID (vincristine, dactinomycin, ifosfamide, and doxorubicin; n = 76) followed by either VAID or VACD (n = 79).[281] The 3-year EFS rates were 73% and 74%, respectively, for VACD and VAID, suggesting that cyclophosphamide has the same efficacy as ifosfamide in this group of patients. Patients with high-risk disease were randomly assigned to VAID or EVAID (VAID plus etoposide). The 3-year EFS rate was not significantly different between the two treatment groups (52% and 47%, respectively, for EVAID and VAID).[281]

As a follow-up to the EICESS-92 study, the Euro-EWING99-R1 trial evaluated cyclophosphamide as a replacement for ifosfamide as part of consolidation therapy that also included vincristine and dactinomycin (VAC vs. VAI) after VIDE induction chemotherapy in 856 patients with standard-risk Ewing sarcoma. VAC was statistically not inferior to VAI but was associated with a slight increase in events (2.8% decrease in 3-year EFS). The proportion of patients experiencing severe hematologic toxicity was slightly higher in the VAC arm, but renal tubular function impairment was more significant for patients receiving VAI.[282]

High-Dose Therapy Followed by Hematopoietic Cell Transplant

High-dose therapy followed by hematopoietic cell transplant (HDT/HCT) has been evaluated in patients with localized as well as metastatic disease. HDT/HCT has been associated with potential survival benefit in patients with non-metastatic disease.[283,284] However, studies that have evaluated HDT/HCT in patients with primary metastatic disease have shown conflicting results.[285-291]

The EURO-EWING 99 study was the first large randomized trial designed to evaluate the efficacy and safety of multiagent induction chemotherapy with six courses of VIDE, local treatment (surgery and/or RT), and HDT/HCT in 281 patients with Ewing sarcoma with primary disseminated disease.[286] After a median follow-up of 3.8 years, the EFS and OS rates at 3 years for the entire study cohort were 27% and 34%, respectively.[290] The EFS rates were 57% and 25%, respectively, for patients with complete and partial response after HDT/HCT. Patients' age, tumor volume, and extent of metastatic spread were identified as relevant risk factors. The outcome of patients with and without HDT/HCT was not performed because of the bias introduced early in the non-transplant group (82% of patients without HDT/HCT died after a median time of 1 year).

The EURO-EWING 99 and Ewing-2008 randomized trial asked whether consolidation high-dose chemotherapy improved survival in patients with localized Ewing sarcoma.[291] Two hundred forty patients at high risk were randomly assigned to receive seven VAI courses (n = 118) or one course of BuMel (busulfan and melphalan) HDT with autologous HCT (n = 122), after a VIDE six-course induction plus one VAI consolidation course. Patients were followed for 15 years; median follow-up time was 7.8 years. Patients treated with BuMel had greater improvement in 3-year

Version 2.2026 © 2025 National Comprehensive Cancer Network© (NCCN©), All rights reserved. NCCN Guidelines® and this illustration may not be reproduced in any form without the express written permission of NCCN.

PLEASE NOTE that use of this NCCN Content is governed by the End-User License Agreement, and you MAY NOT distribute this Content or use it with any artificial intelligence model or tool.
Printed by Galya Basol Kochav on 12/28/2025 10:24:40 AM. Copyright © 2025 National Comprehensive Cancer Network, Inc. All Rights Reserved.

EFS (69.0% vs. 56.7%) and 8-year EFS (60.7% vs. 47.1%) compared to VAI-treated patients. There were three treatment-related deaths: two due to BuMel toxicity and one due to VAI toxicity. More patients experienced severe acute toxicities related to the BuMel versus the VAI course.

Local Control Therapy

Surgery and RT are the local control treatment modalities used for patients with localized disease, but no randomized trials have compared these approaches head-to-head.

In patients with localized Ewing sarcoma treated in cooperative intergroup studies there was no significant effect of local control modality (surgery, RT, or surgery plus RT) on OS or EFS rates.[276,292] In the CESS 86 trial, although radical surgery and resection plus RT resulted in better local control rates (100% and 95%, respectively) than definitive RT (86%), there was no improvement in RFS or OS because of higher frequency of metastases after surgery.[292] In the INT-0091 study, the incidences of local disease progression were similar for patients treated with surgery or RT alone (25%), but surgery plus RT resulted in lower incidences of local disease progression (10.5%).[276] The 5-year EFS rate was also not significantly different between the groups (42%, 52%, and 47% for patients treated with surgery, RT, and surgery plus RT, respectively).

Data from other retrospective analyses suggest that surgery (with or without postoperative RT) affords better local control than RT alone in patients with localized disease.[293,294] The combined analysis of 1058 patients treated in the CESS 81, CESS 86, and EICESS 92 trials showed that the rate of local progression was significantly lower after surgery (with or without postoperative RT) than after definitive RT (7.5% vs. 26.3%, respectively; $P = .001$), whereas the local control rate with preoperative RT was comparable to that of the surgery group (5.3%).[293] A retrospective analysis of sequential studies (INT-0091, INT-0154, or AEWS0031) performed by the Children's Oncology Group also demonstrated that definitive RT was associated with a higher risk of local disease progression than surgery plus RT at 25.0% and 6.3%, respectively, but there was no effect on distant disease progression. [295]

Definitive RT could be an effective treatment option for patients with tumors in anatomical locations not amenable to achieve surgery with wider resection margins.[296,297] In a retrospective analysis of patients with Ewing sarcoma of vertebrae treated in the CESS 81/86 and EICESS 92 studies, definitive RT resulted in a local control rate of 22.6%, which was comparable to those of other tumor sites treated with definitive RT; EFS and OS at 5 years were 47% and 58%, respectively.[296] Tumor size and RT dose have been shown to be predictive of local control rates in patients with non-metastatic Ewing sarcoma treated with chemotherapy and definitive RT.[298,299] Local control therapy has also been associated with improved outcomes in patients with primary metastatic disease.[300-302] In the EURO-EWING 99 trial, the 3-year EFS was significantly lower in patients with primary metastatic disease who did not receive any local control therapy compared to those treated with local therapy for primary tumor.[300] Retrospective analysis of 198 patients from EURO-EWING 99 showed no improvement of 5-year EFS associated with adjuvant RT in the setting of completely resected disease of the chest wall.[303]

NCCN Recommendations

All patients with Ewing sarcoma should be treated with the following protocol: primary treatment followed by local control therapy and adjuvant treatment. Primary treatment consists of multiagent chemotherapy along with appropriate growth factor support for at least 9 weeks (category 1). Longer duration could be considered for patients with metastatic disease based on response. VDC-IE is the preferred regimen for patients with localized disease and is a category 1 recommendation. See *Bone Cancer Systemic Therapy Agents* in the algorithm for a list of other chemotherapy

Version 2.2026 © 2025 National Comprehensive Cancer Network© (NCCN©), All rights reserved. NCCN Guidelines® and this illustration may not be reproduced in any form without the express written permission of NCCN.

PLEASE NOTE that use of this NCCN Content is governed by the End-User License Agreement, and you MAY NOT distribute this Content or use it with any artificial intelligence model or tool.
Printed by Galya Basol Kochav on 12/28/2025 10:24:40 AM. Copyright © 2025 National Comprehensive Cancer Network, Inc. All Rights Reserved.

regimens that are recommended for patients with localized and metastatic disease. Of note, patients with other primary round cell sarcoma of bone can be treated like Ewing sarcoma.

Disease should be restaged with imaging following primary treatment. Chest imaging (specifically non-contrast CT) is recommended for restaging. Additionally, primary site imaging should include contrast-enhanced MRI with or without CT and plain radiograph. Head-to-toe FDG-PET/CT or bone scan can be used for restaging depending on the imaging technique that was used in the initial workup.

Patients with stable or improved disease after primary treatment should be treated with local control therapy. Local control options include wide excision, definitive RT with chemotherapy, or amputation in selected cases.[293,296,298,300] The choice of local control therapy should be individualized and is dependent on tumor location, size, response to chemotherapy, patient age, anticipated morbidity, and patient preference.[276]

Adjuvant chemotherapy following wide excision or amputation is recommended for all patients regardless of surgical margins. The Panel strongly recommends that the duration of chemotherapy following wide excision or amputation should be between 28 and 49 weeks depending on the type of regimen and the dosing schedule (category 1).[266-268] The addition of postoperative RT to chemotherapy is recommended for patients with positive or very close surgical margins.[293] Denbo and colleagues reported that in patients with smaller tumor size (<8 cm) and negative margins, postoperative RT can be omitted without any decrement in OS.[304] The 15-year estimated OS for patients who received adjuvant RT was 80% compared to 100% for those who did not. The guidelines have included adjuvant chemotherapy alone for patients treated with wide excision and negative margins.

In the setting of widely metastatic disease, palliative therapies may be considered. For metastatic disease that may be amenable to local therapy, local control modalities, in the form of wide excision or definitive RT with adjuvant chemotherapy, are recommended. Regardless of postoperative margin status, chemotherapy for at least 28 to 49 weeks is to be administered (category 1). RT, in addition to chemotherapy, may be considered for positive surgical margins. Following adjuvant treatment, metastases may be managed according to the location. In the case of oligometastatic disease, excision or RT is recommended. SRS/stereotactic body RT (SBRT) can be considered, especially for oligometastases.[305-307] For pulmonary metastases, dependent on the response, resection and/or whole lung irradiation (WLI) may be considered.[308] Based on the EORTC-SIOP phase III study published in 1988, which concluded there to be no survival benefit of WLI over adjuvant chemotherapy for patients with osteosarcoma, a systematic review of both prophylactic as well as curative WLI in patients with osteosarcoma and Ewing sarcoma was conducted.[309,310] Only two studies compared the results of chemotherapy alone and chemotherapy and curative WLI in patients with metastatic Ewing sarcoma. In both trials, patients experienced some benefit with WLI and chemotherapy when compared to chemotherapy alone. For instance, in the EICESS-92 trial, patients who also received WLI showed a 12% improvement in 5-year OS.[310,311] Ultimately, it was concluded that the decision to use WLI should be based on the patient's risk of pulmonary metastases and any coexisting respiratory diseases.[310] Progressive disease following primary treatment is best managed with RT and/or surgery to primary site followed by chemotherapy or best supportive care.

Surveillance

Surveillance of patients with Ewing sarcoma should include a physical exam, CBC and other laboratory studies (as indicated), contrast-enhanced MRI with or without CT, and plain radiographs of the primary

Version 2.2026 © 2025 National Comprehensive Cancer Network© (NCCN©), All rights reserved. NCCN Guidelines® and this illustration may not be reproduced in any form without the express written permission of NCCN.

PLEASE NOTE that use of this NCCN Content is governed by the End-User License Agreement, and you MAY NOT distribute this Content or use it with any artificial intelligence model or tool.
Printed by Galya Basol Kochav on 12/28/2025 10:24:40 AM. Copyright © 2025 National Comprehensive Cancer Network, Inc. All Rights Reserved.

site. Chest imaging (x-ray or CT) is recommended every 3 months. Head-to-toe FDG-PET/CT or bone scan can be considered as appropriate. Surveillance intervals should be increased after 2 years. Long-term surveillance should be performed annually after 5 years, and as clinically indicated (indefinitely) (category 2B).[312]

Relapsed or Refractory Disease

Approximately 30% to 40% of patients with localized Ewing sarcoma at presentation and 60% to 80% with metastatic disease at presentation experience recurrence (local and/or distant) and have a very poor prognosis.[313] Patients with a longer time to first recurrence have a better chance of survival following recurrence. Late relapse (≥2 years from the time of original diagnosis), lung-only metastases, local recurrence that can be treated with radical surgery, and intensive chemotherapy are the most favorable prognostic factors, whereas early relapse (<2 years from the time of original diagnosis) with metastases in lungs and/or other sites, recurrence at local and distant sites, elevated LDH at initial diagnosis, and initial recurrence are considered adverse prognostic factors.[314-317] In a retrospective analysis, site of first relapse and time to first relapse were significant prognostic factors for adult patients with localized Ewing sarcoma.[318] The probability of 5-year post-relapse survival was 55% and 22%, respectively, for patients with local and distant relapse. The probability of 5-year post-relapse survival was also significantly higher for patients with late relapse than for those with early relapse.[32,313,318] Overall, it is reported that close to 70% of relapses are early relapses, of which two-thirds occur at distant sites (in the lungs and/or bones). Patients who initially presented with widespread disease are more likely to relapse at distant sites, whereas those individuals who presented with localized disease are more likely to develop local relapse.[319]

Topoisomerase I inhibitors (topotecan and irinotecan) in combination with cyclophosphamide and temozolomide have been associated with favorable response rates in patients with relapsed or refractory bone sarcomas.[320-326] In a series of 54 patients with relapsed or refractory Ewing sarcoma, cyclophosphamide and topotecan induced responses in 44% of patients (35% of patients had a complete response and 9% had a partial response).[321] After a median follow-up of 23 months, 26% of patients were in continuous remission. In a retrospective analysis of patients with recurrent or progressive Ewing sarcoma, irinotecan and temozolomide resulted in an overall objective response rate of 63%. The median time to progression (TTP) for all the evaluable patients (n = 20) was 8.3 months (16.2 months for the subset of patients with recurrent disease).[324] Patients who were in a 2-year first remission and those with primary localized disease had better median TTP compared to those who relapsed within 2 years from diagnosis and patients with metastatic disease at diagnosis.

Combination therapy with vincristine, irinotecan, and temozolomide also appears to be active and well-tolerated in patients with relapsed or refractory Ewing sarcoma, with an ORR of 68%.[327] A review of 107 patients with relapsed or refractory Ewing sarcoma examined the combination of etoposide with a platinum agent (ie, cisplatin or carboplatin), suggesting that further study of etoposide and carboplatin may be warranted.[328] HDT/HCT has been associated with improved long-term survival in patients with relapsed or progressive Ewing sarcoma in small, single-institution studies.[329-331] The role of this approach is yet to be determined in prospective randomized studies.

The CABONE trial, a multicenter, single-arm phase 2 trial, evaluated the activity of cabozantinib in patients with advanced Ewing sarcoma and osteosarcoma.[332] Currently approved for renal carcinoma, hepatocellular carcinoma, and medullary thyroid cancer, cabozantinib is a vascular

Version 2.2026 © 2025 National Comprehensive Cancer Network© (NCCN©), All rights reserved. NCCN Guidelines® and this illustration may not be reproduced in any form without the express written permission of NCCN.

PLEASE NOTE that use of this NCCN Content is governed by the End-User License Agreement, and you MAY NOT distribute this Content or use it with any artificial intelligence model or tool.
Printed by Galya Basol Kochav on 12/28/2025 10:24:40 AM. Copyright © 2025 National Comprehensive Cancer Network, Inc. All Rights Reserved.

endothelial growth factor receptor-2 (VEGFR2) TKI with inhibitory activity against the MET receptor. For Ewing sarcoma, the primary endpoint in this study was a 6-month objective response, while the secondary endpoints included safety, 6-month non-progression, best overall response, 1-year and 2-year PFS and OS, and metabolic response (evaluated by FDG-PET/CT 28 days after the first dose). The primary endpoint was achieved with a 6-month objective response of 26% (95% CI, 13–42) among 39 patients with Ewing sarcoma. Additionally, the median OS was reported to be 10.2 months with a median PFS of 4.4 months. OS was noted to be 84% at 6 months, 48% at 12 months, and finally 14% at 24 months. Forty-two percent (95% CI, 25–61) of patients exhibited a metabolic tumor response. Cabozantinib was well-tolerated among patients with the most common grade 3 or 4 adverse effects being hypophosphatemia, elevated aspartate aminotransferase (AST), palmar-plantar syndrome, pneumothorax, and neutropenia.[332]

The efficacy of regorafenib has been evaluated in the phase II SARC024 trial in 30 patients with metastatic Ewing sarcoma whose disease progressed following at least 1 line of therapy. The 8-week progression-free rate was 63% and the median OS was 53 weeks.[333]

The phase III rEECur trial compared the efficacy of IFOS (high-dose ifosfamide) (n = 73) against topotecan and cyclophosphamide (TC) (n = 73) in patients with relapsed or refractory Ewing sarcoma.[334] The median EFS was 3.7 months and 5.7 months for TC and IFOS, respectively, and the median OS was 10.4 months and 16.8 months for TC and IFOS, respectively. Greater survival for EFS and OS was also seen in individuals aged <14 years.

A retrospective study evaluated docetaxel in combination with gemcitabine in 22 children and young adults with refractory bone sarcomas.[335] The median duration of response was 4.8 months and the objective response rate was 29%.

The combination of ifosfamide, carboplatin, and etoposide has also been evaluated in three Children's Cancer Group phase I/II trials in 97 patients with relapsed or refractory bone sarcomas.[336] The ORR was 51%.

A single-arm phase II study evaluated the efficacy and safety of lurbinectedin in a cohort of 28 adult patients with relapsed Ewing sarcoma.[337] Treatment with lurbinectedin resulted in an ORR of 14.3% and a median duration of response of 4.2 months.

In a study evaluating 26 patients treated for local recurrence of Ewing sarcoma, surgical treatment was associated with better survival ($P < .001$).[338] In addition to chemotherapy, surgery may be a treatment option for some patients who experience relapsed disease.

NCCN Recommendations

Treatment options for patients with relapsed or refractory disease include participation in a clinical trial and chemotherapy (with or without RT or with or without surgery). See *Bone Cancer Systemic Therapy Agents* in the algorithm for a list of other systemic therapy regimens recommended for patients with relapsed or refractory Ewing sarcoma.

All patients with recurrent and metastatic disease should be considered for clinical trials investigating new treatment approaches.

Giant Cell Tumor of Bone

GCTB is a rare benign primary tumor of the bone accounting for about 3% to 5% of all primary bone tumors, with a strong tendency for local recurrence and that may metastasize to the lungs.[339,340] GCTB usually occurs between 20 and 40 years of age. The meta-epiphyseal regions of the distal femur and proximal tibia are the most common primary sites.[341] Malignant transformation to high-grade osteosarcoma has been observed in rare cases and is associated with a poor prognosis.[342,343]

Version 2.2026 © 2025 National Comprehensive Cancer Network© (NCCN©), All rights reserved. NCCN Guidelines® and this illustration may not be reproduced in any form without the express written permission of NCCN.

PLEASE NOTE that use of this NCCN Content is governed by the End-User License Agreement, and you MAY NOT distribute this Content or use it with any artificial intelligence model or tool.
Printed by Galya Basol Kochav on 12/28/2025 10:24:40 AM. Copyright © 2025 National Comprehensive Cancer Network, Inc. All Rights Reserved.

Workup

Initial workup should include H&P examination with imaging (eg, x-ray, MRI with and without contrast ± CT) of the primary site as clinically indicated, in addition to chest imaging. CT is useful to define the extent of cortical destruction, whereas MRI is the preferred imaging modality to assess the extension of tumors into the adjacent soft tissue and neurovascular structures.[344,345] Chest imaging is essential to identify the presence of metastatic disease. Bone scan can be considered for unusual cases. Biopsy is essential to confirm the diagnosis. Brown tumor of hyperparathyroidism should be considered as a differential diagnosis; routine evaluation of serum calcium, phosphate, and parathyroid hormone levels can help exclude this diagnosis.[346] If there is malignant transformation, treat as osteosarcoma.

Treatment

Surgery

Wide excision and intralesional curettage are the two surgical treatment options for patients with resectable tumors.[347-353] Wide excision is associated with a lower risk of local recurrence than intralesional curettage, with the local recurrence rates ranging from 0% to 12% for wide excision and 12% to 65% for intralesional curettage. In some studies, the extent of intralesional excision and the tumor stage have been identified as prognostic indicators for risk of recurrence.[354-356] Blackley and colleagues reported a local recurrence rate of 12% in 59 patients who were treated with curettage with high-speed burr and bone grafting, which was similar to that observed with the use of adjuvants; the majority of the patients had grade II or III tumors.[355] In another retrospective analysis of 137 patients, Prosser and colleagues reported local recurrences in 19% of patients following curettage as a primary treatment; local recurrence rate was only 7% for patients with grade I and II tumors confined to the bone compared with 29% for those with grade III tumors with extraosseous extension.[356]

Surgical adjuvants have been used in conjunction with intralesional curettage to improve local control rates. However, the findings from studies that have evaluated intralesional curettage, with and without adjuvant in the same cohort of patients with primary or recurrent GCTB, are inconsistent, with some reporting decreased local recurrence rates with the use of adjuvants.[351,357-360] Others, however, have reported no significant difference in local recurrence rates with and without adjuvants.[162,361,362]

Wide excision is also associated with poor functional outcome and greater surgical complications.[363-368] Therefore, intralesional curettage is considered the treatment of choice in a majority of patients with stage I or II tumors. Wide excision is usually reserved for more aggressive stage III tumors with extraosseous extension or otherwise unresectable tumors.[356,369-372]

Radiation Therapy

RT has been used either as a primary treatment or in combination with surgery to improve local control and DFS for patients with marginally resected, unresectable, progressive, or recurrent disease.[373-384] In a retrospective analysis of 58 patients with GCTB (45 patients with primary tumor and 13 patients with recurrent tumor) treated with RT, the 5-year local control and OS rates were 85% and 94%, respectively.[383] Median follow-up was 8 years. In this analysis, patient age was the only prognostic factor with local control rates (96% for patients ≤30.8 years vs. 73% for patients >30.8 years) as well as OS (100% vs. 87%) and DFS rates (96% vs. 65%). Other studies have identified tumor size >4 cm, recurrent tumors, and RT doses of ≤40 Gy as negative prognostic factors for local control.[379-381,384]

Specialized techniques such as 3D-CRT and IMRT have also been associated with good local control rates in patients with GCTB in locations that are not amenable to complete surgical resection.[385,386]

Version 2.2026 © 2025 National Comprehensive Cancer Network© (NCCN©), All rights reserved. NCCN Guidelines® and this illustration may not be reproduced in any form without the express written permission of NCCN.

PLEASE NOTE that use of this NCCN Content is governed by the End-User License Agreement, and you MAY NOT distribute this Content or use it with any artificial intelligence model or tool.
Printed by Galya Basol Kochav on 12/28/2025 10:24:40 AM. Copyright © 2025 National Comprehensive Cancer Network, Inc. All Rights Reserved.

Adverse side effects have occurred as a result of RT. As GCTB is a benign growth, radiation use should be considered riskier than for malignant tumors. [387,388] Therefore, the Panel recommends that RT should be considered if no other treatment options are available, if possible.

Systemic Therapy

Denosumab (a fully humanized monoclonal antibody against the RANK ligand) has demonstrated activity in patients with unresectable or recurrent GCTB.[389-396] In June 2013, denosumab was approved by the FDA for the treatment of adults and skeletally mature adolescents with GCTB that is unresectable or where surgical resection is likely to result in severe morbidity. It is a preferred option in resectable localized disease with unacceptable morbidity and/or with unresectable axial lesions, or unresectable metastatic disease at presentation.

Several phase II trials have examined the efficacy of denosumab for treating primary and recurrent GCTB. In an open-label, phase II study (n = 37), denosumab induced tumor response (defined as the elimination of ≥90% of giant cells or no radiologic progression of the target lesion for ≤25 weeks) in 86% (30 of 35 evaluable patients) of patients with unresectable or recurrent GCTB.[389] An open-label, parallel-group, phase II study divided patients with GCTB into three cohorts: those with unresectable GCTB (cohort 1), those with resectable GCTB associated with severe surgical morbidity (cohort 2), and those transferred from a previous study of denosumab for GCTB (cohort 3).[391,397,398] After a median follow-up of 58.1 months, TTP or recurrence in 253 patients in cohort 1 had not been reached.[398] Clinically significant reductions in pain were reported by over half of the study patients within 2 months.[399] Final analysis of outcomes from cohort 2 (n = 222) showed that denosumab enabled 48% of patients to delay/avoid surgery and 38% to undergo less morbid resections.

The risk of local recurrence has been reported to be higher when denosumab is used prior to curettage. In a retrospective analysis of 408 patients treated for GCTB using either intralesional curettage or wide excision, the local recurrence rate for patients treated with curettage and denosumab was 60%, compared to 16% for those individuals treated with curettage alone.[400] Additionally, the joint preservation rate of patients treated with curettage and denosumab was 80% compared to 94% for those treated with curettage alone. Although denosumab usage was reported to be the only independent factor associated with increased recurrence, it is likely that such an association may also stem from selection bias.[400] Use of denosumab before surgery, however, may aid in defining a peripheral rim around the tumor.[401,402]

Phase II trial data have also suggested that sequential FDG-PET imaging appears to be a sensitive tool for early detection of tumor response to denosumab treatment.[403]

There have been reports of increased risk of developing osteosarcoma associated with denosumab therapy in recurrent GCTB.[404-406] The data are limited to determine the cause of the increased risk, but the NCCN Panel identifies some possibilities, such as spontaneous conversion to a secondary sarcoma, or a diagnostic and/or sampling error that erroneously categorizes a tumor as GCTB.

In prior versions of the guidelines, interferon (IFN) was recommended as a treatment option, based on case reports that reported the efficacy of IFN in the management of GCTB.[407-410] However, since IFN is no longer available in the United States, it is no longer included as a treatment option in the guidelines.

NCCN Recommendations

Localized Disease

Intralesional excision with an effective adjuvant may be an adequate primary treatment for resectable tumors.[162,361,362]

Version 2.2026 © 2025 National Comprehensive Cancer Network© (NCCN©), All rights reserved. NCCN Guidelines® and this illustration may not be reproduced in any form without the express written permission of NCCN.

PLEASE NOTE that use of this NCCN Content is governed by the End-User License Agreement, and you MAY NOT distribute this Content or use it with any artificial intelligence model or tool.
Printed by Galya Basol Kochav on 12/28/2025 10:24:40 AM. Copyright © 2025 National Comprehensive Cancer Network, Inc. All Rights Reserved.

Serial arterial embolizations have been shown to be effective in the comprehensive care of patients with giant cell tumors of the extremities, especially for tumors with large cortical defects or joint involvement and for those with large giant cell tumors of the sacrum.[411-414]

For patients with lesions that are resectable with unacceptable morbidity and/or unresectable axial lesions, the guidelines have included denosumab and/or serial embolization as preferred options. Consultation with a dentist should be considered prior to initiating denosumab therapy.[415,416] RT is another recommended option, although it may be associated with an increased risk of malignant transformation. Imaging should be used to assess treatment response and should include plain radiographs as well as contrast-enhanced CT with or without MRI.

Following primary treatment, patients with stable/improved disease can be observed. For patients with stable/improved disease with incomplete healing following primary treatment, excision is recommended if the lesion has become resectable. Long-term denosumab use may be associated with increased risk of local recurrence.

Patients whose disease remains unresectable should be retreated with denosumab, serial embolization, and/or RT. Denosumab may be continued until disease progression, in responding disease.

Metastatic Disease

For patients presenting with resectable metastases, the guidelines recommend that the primary tumor be managed as described above for localized disease.[339,340,417,418] Intralesional excision may also be used for resectable metastatic sites. Denosumab (preferred), observation, and RT are options for patients with unresectable metastases.

Surveillance and Recurrence

Surveillance should include a physical exam, imaging (eg, x-ray, contrast-enhanced CT and/or MRI) of the surgical site as clinically indicated, and chest imaging. As the average time to metastasis ranges from approximately 2 to 4 years,[417-419] chest imaging should be performed every 6 to 12 months for 4 years, then annually thereafter, as clinically indicated.

Recurrent disease (local or metastatic) should be managed as per primary treatment for localized disease or metastatic disease at presentation. For patients with local recurrence and resectable disease, chest imaging and denosumab can be considered prior to surgery. However, the risk of local recurrence is increased when denosumab is used prior to curettage. Denosumab may be beneficial to define peripheral tumor extent when planning wide resection.

Osteosarcoma

Osteosarcoma is the most common primary malignant bone tumor in children and young adults. With bimodal age distribution, incidences first peak among patients aged 10 to 14 years, and again in patients >65 years.[420] In adults >65 years, osteosarcoma may develop as a secondary malignancy related to Paget disease of the bone.[20] Osteosarcoma is broadly classified into three histologic subtypes (intramedullary, surface, and extraskeletal).[421]

High-grade intramedullary osteosarcoma is the classic or conventional form, comprising nearly 80% of osteosarcomas.[421] It is a spindle cell or pleomorphic tumor that produces osteoid or immature bone. The most frequent sites include the metaphysis of the distal femur or proximal tibia, which correspond to the physes of maximum growth in normal skeletal development. Low-grade intramedullary osteosarcoma comprise <2% of all osteosarcomas; the most common sites are similar to that of conventional osteosarcoma.[422]

Version 2.2026 © 2025 National Comprehensive Cancer Network© (NCCN©), All rights reserved. NCCN Guidelines® and this illustration may not be reproduced in any form without the express written permission of NCCN.

PLEASE NOTE that use of this NCCN Content is governed by the End-User License Agreement, and you MAY NOT distribute this Content or use it with any artificial intelligence model or tool.
Printed by Galya Basol Kochav on 12/28/2025 10:24:40 AM. Copyright © 2025 National Comprehensive Cancer Network, Inc. All Rights Reserved.

Parosteal and periosteal osteosarcomas are juxtacortical or surface variants. Parosteal osteosarcomas are low-grade lesions accounting for up to 5% of all osteosarcomas.[422] The most common site is the posterior distal femur. This variant is associated with very low metastatic potential. Transformation of low-grade parosteal osteosarcoma into high-grade osteosarcoma has been documented in 24% to 43% of cases.[423,424] Periosteal osteosarcomas are intermediate-grade lesions, showing partial cartilaginous differentiation, and most often involve the femur, followed by the tibia.[422] High-grade surface osteosarcomas are very rare, accounting for 10% of all juxtacortical osteosarcomas.[425,426]

Pain and swelling are the most frequent early symptoms. Pain is often intermittent in the beginning, and a thorough workup sometimes is delayed because symptoms may be confused with growing pains or confounded by musculoskeletal injury. Osteosarcoma spreads hematogenously, with the lung being the most common metastatic site, though “skip lesions” in the same bone can also occur.

For treating extraskeletal osteosarcomas, please see the NCCN Guidelines for Soft Tissue Sarcoma, available at www.NCCN.org.

Prognostic Factors

Tumor site and size, patient age, presence and location of metastases, histologic response to chemotherapy, and type of surgery and surgical margins are significant prognostic factors for patients with osteosarcoma of the extremities and trunk.[427-435] A meta-analysis and systematic review of 18,126 participants showed that patient sex, tumor site (extremity versus non-extremity), tumor size, response to chemotherapy, and surgery (amputation versus limb-sparing) were identified as prognostic factors in osteosarcoma.[436] In patients with extremity osteosarcomas, in addition to these variables, size and location within the limb at the time of diagnosis also had significant influence on outcome.[436] All factors except age were significant in multivariate testing, with surgical remission and histologic response to chemotherapy emerging as the key prognostic factors. In a meta-analysis of data from prospective neoadjuvant chemotherapy trials in 4838 patients with osteosarcoma, female sex was associated with increased chemotherapy-induced tumor necrosis and greater OS, and children had better outcomes than adolescents and adults.[437] In a report of the combined analysis of three European Osteosarcoma Intergroup randomized controlled trials, Whelan and colleagues reported that good histologic response to preoperative chemotherapy, distal location (other than proximal humerus/femur), and female gender were associated with improved survival.[432] However, high body mass index (BMI) in patients with osteosarcoma was associated with lower OS compared with patients with normal BMI.[438]

In patients with proven primary metastatic osteosarcoma, the number of metastases at diagnosis and the completeness of surgical resection of all clinically detected tumor sites are of independent prognostic value.[33] Patients with one or a few resectable pulmonary metastases have a survival rate that approaches that of patients without metastatic disease.[439,440]

Elevated serum ALP and LDH levels have also been identified as prognostic indicators in patients with osteosarcoma.[428,430,431,441,442] In a cohort of 1421 patients with osteosarcoma of the extremity, Bacci and colleagues reported significantly higher serum LDH levels in patients with metastatic disease at presentation than in patients with localized disease (36.6% vs. 18.8%; $P < .0001$).[430] The 5-year DFS correlated with serum LDH levels (39.5% for patients with high LDH levels and 60% for those with normal values). In another retrospective analysis of 789 patients with osteosarcoma of the extremity, it was reported that serum ALP level was a significant prognostic factor of EFS in patients with osteosarcoma of the extremity; the 5-year EFS rate was 24% for patients with a serum

Version 2.2026 © 2025 National Comprehensive Cancer Network© (NCCN©), All rights reserved. NCCN Guidelines® and this illustration may not be reproduced in any form without the express written permission of NCCN.

PLEASE NOTE that use of this NCCN Content is governed by the End-User License Agreement, and you MAY NOT distribute this Content or use it with any artificial intelligence model or tool.
Printed by Galya Basol Kochav on 12/28/2025 10:24:40 AM. Copyright © 2025 National Comprehensive Cancer Network, Inc. All Rights Reserved.

ALP value of more than four times higher than the normal value and 46% for patients with high values below this limit ($P < .001$).[431] However, in multivariate analyses, these markers did not retain their prognostic significance when compared to tumor volume, age, and histologic response to chemotherapy.[428,430]

Workup

Osteosarcomas present both a local control problem and a concern for distant metastasis. Initial workup should include imaging of the primary site (contrast-enhanced MRI with or without CT), chest imaging including chest CT, and head-to-toe FDG-PET/CT and/or bone scan. More detailed imaging (MRI with and without contrast or CT) of skeletal metastatic sites to identify abnormalities identified on primary imaging is required for suspected metastatic disease.

Plain x-rays of osteosarcomas show cortical destruction and irregular reactive bone formation. Bone scan, while uniformly abnormal at the lesion, may be useful to identify additional synchronous lesions. MRI provides excellent soft tissue contrast and may be essential for operative planning. MRI is the best imaging modality to define the extent of the lesion within the bone as well as within the soft tissues, to detect “skip” metastases and to evaluate anatomic relationships with the surrounding structures. In addition, ALP and LDH are frequently elevated in patients with osteosarcoma. Serum LDH was significantly higher in patients with metastatic disease at presentation than in patients with localized disease.[430]

Given that osteosarcoma is most common among children and AYAs, the effect of cancer and its treatment on fertility must be discussed with patients. Fertility preservation methods and alternatives should be discussed with patients as appropriate. See the *Diagnostic Workup* section above.

Finally, a number of genetic aberrations may underly osteosarcoma.[443] For instance, it is reported that nearly 70% of patients with osteosarcoma may exhibit mutations in the tumor suppressor retinoblastoma gene, *RB1*.[443] Genetic cancer syndromes that exhibit a predisposition for osteosarcoma include: Li-Fraumeni syndrome, hereditary retinoblastoma, Rothmund-Thomson syndrome type 2, Bloom syndrome, Werner syndrome, RAPADILINO syndrome, and Diamond-Blackfan anemia. Thus, the NCCN Panel recommends that genetic consultation and testing be considered for patients diagnosed with chondrosarcoma or osteosarcoma who possess a family or personal history of bone sarcomas.[22]

Treatment

Surgery

Surgery (limb-sparing surgery or amputation) remains an essential part of comprehensive care for patients with osteosarcoma.[444] Studies that have compared limb-sparing surgery and amputation in patients with high-grade, non-metastatic osteosarcoma have not shown any significant difference in survival and local recurrence rates between these procedures.[445-447] However, limb-sparing surgery is associated with better functional outcomes.[448] In patients with high-grade osteosarcomas with good histologic response to neoadjuvant chemotherapy, limb-sparing surgery is considered the preferred surgical modality if wide surgical margins can be achieved.[445,449] Amputation is generally reserved for patients with tumors in unfavorable anatomical locations not amenable to limb-sparing surgery with adequate surgical margins and for management of local relapse when limb-sparing procedures are not practical.[444,449]

Chemotherapy

The addition of adjuvant and neoadjuvant chemotherapy regimens to surgery has revolutionized outcomes in patients with localized osteosarcoma.[450] Early trials used chemotherapy regimens including at least three or more of the following drugs: doxorubicin, cisplatin,

Version 2.2026 © 2025 National Comprehensive Cancer Network© (NCCN©), All rights reserved. NCCN Guidelines® and this illustration may not be reproduced in any form without the express written permission of NCCN.

PLEASE NOTE that use of this NCCN Content is governed by the End-User License Agreement, and you MAY NOT distribute this Content or use it with any artificial intelligence model or tool.
Printed by Galya Basol Kochav on 12/28/2025 10:24:40 AM. Copyright © 2025 National Comprehensive Cancer Network, Inc. All Rights Reserved.

bleomycin, cyclophosphamide or ifosfamide, dactinomycin, and high-dose methotrexate.[451-456] Subsequent clinical trials have demonstrated that short, intensive chemotherapy regimens including cisplatin and doxorubicin with or without high-dose methotrexate and ifosfamide produce excellent long-term results, similar to those achieved with standard-dose multiagent chemotherapy.[457-466] Cisplatin and doxorubicin and MAP (high-dose methotrexate, cisplatin, and doxorubicin) are included as category 1 recommended regimens for first-line therapy. MAP is preferred in patients <40 years with excellent performance status. In the event a patient receiving high-dose methotrexate experiences delayed elimination due to renal impairment, glucarpidase is strongly recommended.

In a randomized trial conducted by the European Osteosarcoma Group, the combination of doxorubicin and cisplatin was better tolerated compared to a multi-drug regimen with no difference in survival between the groups in patients with operable, non-metastatic osteosarcoma.[458] The 3-year and 5-year OS rates were 65% and 55%, respectively, in both groups. The 5-year PFS rate was 44% in both groups. In the INT-0133 study, which compared the 3-drug regimen (cisplatin, doxorubicin, and methotrexate) with the 4-drug regimen (cisplatin, doxorubicin, methotrexate, and ifosfamide) for the treatment of patients with non-metastatic resectable osteosarcoma, there was no difference in the 6-year EFS (63% and 64%, respectively) and OS (74% and 70%, respectively) between the two groups.[464]

Chemotherapy regimens without doxorubicin or cisplatin have also been evaluated in patients with localized osteosarcoma with the aim of minimizing long-term cardiotoxicity and ototoxicity.[467,468] In a randomized multicenter trial (SFOP-OS94), the combination of ifosfamide and etoposide resulted in a higher histologic response rate than the regimen containing high-dose methotrexate and doxorubicin (56% and 39%, respectively). However, the 5-year OS was similar in both arms and there was no significant difference in 5-year EFS rates.[468]

Good histopathologic response (>90% necrosis) to neoadjuvant chemotherapy is associated with improved survival regardless of the type of chemotherapy administered after surgery.[312,469,470] In an analysis of 881 patients with non-metastatic osteosarcoma of the extremities treated with neoadjuvant chemotherapy and surgery at the Rizzoli Orthopaedic Institute, Bacci and colleagues showed that the 5-year DFS and OS correlated significantly with histologic response to chemotherapy.[471] The 5-year DFS and OS in patients with good and poor response to chemotherapy were 67.9% versus 51.3% ($P < .0001$) and 78.4% versus 63.7% ($P < .0001$), respectively. A report from the Children's Oncology Group also confirmed these findings; the 8-year postoperative EFS and OS rates were 81% and 87%, respectively, in patients with good response.[469] The corresponding survival rates were 46% and 52%, respectively, in patients with poorly responding disease. For individuals with poorly responding disease, completion of chemotherapy is still warranted, as outcomes are still better than for those who do not complete chemotherapy.

NCCN Recommendations

Localized Disease

The guidelines recommend wide excision as the primary treatment for patients with low-grade (intramedullary and surface) osteosarcomas and periosteal lesions. If pathologic high-grade disease is discovered after wide excision, adjuvant chemotherapy is a category 1 recommendation. Long-term results (>25 years of follow-up) from patients with high-grade, localized osteosarcoma reveal significant benefits of adjuvant chemotherapy on DFS and OS.[470] Chemotherapy prior to wide excision could be considered for patients with periosteal lesions. Although chemotherapy (neoadjuvant or adjuvant) has been used in the treatment

Version 2.2026 © 2025 National Comprehensive Cancer Network© (NCCN©), All rights reserved. NCCN Guidelines® and this illustration may not be reproduced in any form without the express written permission of NCCN.

PLEASE NOTE that use of this NCCN Content is governed by the End-User License Agreement, and you MAY NOT distribute this Content or use it with any artificial intelligence model or tool.
Printed by Galya Basol Kochav on 12/28/2025 10:24:40 AM. Copyright © 2025 National Comprehensive Cancer Network, Inc. All Rights Reserved.

of patients with periosteal osteosarcoma, there are no data to support that the addition of chemotherapy to wide excision improves outcome in patients with periosteal osteosarcoma.[472-474] In a review of 119 patients with periosteal sarcoma published by the European Musculo-Skeletal Oncology Society, the use of neoadjuvant chemotherapy was not a prognostic factor, although it was used in the majority of the patients.[473] Cesari and colleagues also reported similar findings; the 10-year OS rate was 86% and 83%, respectively, for patients who received adjuvant chemotherapy with surgery and for those who underwent surgery alone (P = .73).[472] A systematic review of 13 studies, including 291 patients with periosteal osteosarcoma, found no statistically significant improvement in mortality rates among those who received surgery and (neo-) adjuvant chemotherapy and those who received surgery alone. [474]

Neoadjuvant chemotherapy prior to wide excision is preferred for those with high-grade osteosarcoma (category 1).[439,457-459,462-464,467,468,475] Repeat imaging using pretreatment imaging modalities should be used to reassess the tumor for resectability. Selected older patients may benefit from immediate surgery.

Following wide excision, patients whose disease has a good histologic response (amount of viable tumor is <10% of the tumor area) should continue to receive several more cycles of the same chemotherapy. Surgical re-excision with or without RT can be considered for positive surgical margins. In a study of 119 patients with osteosarcoma of the head and neck, combined modality treatment with surgery and RT (vs. surgery alone) improved local control and OS for patients with positive or uncertain surgical margins.[476] Combined photon/proton or proton beam RT has been shown to be effective for local control in some patients with unresectable or incompletely resected osteosarcoma.[477,478]

Patients whose disease has a poor response (viable tumor is ≥10% of the tumor area) can continue with the preoperative regimen or be considered for chemotherapy with a different regimen (category 3). However, attempts to improve the outcome of those with poor response by modifying the adjuvant chemotherapy remain unsuccessful.[465,479-482]

In individuals whose sarcoma remains unresectable following preoperative chemotherapy, RT or adjuvant chemotherapy is recommended. A randomized phase III trial of the European and American Osteosarcoma Study (EURAMOS) Group evaluated treatment strategies for resectable osteosarcoma based on histologic response to preoperative chemotherapy.[479,483] The EURAMOS-1 trial included cohorts that received maintenance therapy with MAP; MAP with IFN-α-2b therapy; or MAPIE (MAP with ifosfamide and etoposide). The addition of maintenance IFN-α-2b therapy to MAP in the adjuvant setting did not improve outcomes for individuals whose disease had a good response to preoperative chemotherapy.[483] However, the authors note that a significant portion of patients assigned to the IFN arm (n = 357) did not receive the intended dose of IFN-α-2b due to patient declination to initiate therapy (n = 86; 24%) or premature termination of therapy (n = 105; 39%). Additionally, adding ifosfamide and etoposide to MAP (ie, MAPIE) did not improve outcomes for individuals whose disease responded poorly to preoperative chemotherapy.[479] Of the 307 EFS events reported, data showed that restricted mean survival time (RMST) was 43.3 months (95% CI, 40.1–46.4) for individuals who received MAP (n = 153) and 44.1 months (41.1–47.1) for individuals assigned to the MAPIE (n = 154) cohort. No difference in EFS between cohorts was reported.

Chemotherapy should include appropriate growth factor support. See the NCCN Guidelines for Hematopoietic Growth Factors (available at www.NCCN.org) for growth factor support. See *Bone Cancer Systemic Therapy Agents* in the algorithm for a list of specific chemotherapy regimens. Additional treatment options for patients whose disease has

Version 2.2026 © 2025 National Comprehensive Cancer Network© (NCCN©), All rights reserved. NCCN Guidelines® and this illustration may not be reproduced in any form without the express written permission of NCCN.

PLEASE NOTE that use of this NCCN Content is governed by the End-User License Agreement, and you MAY NOT distribute this Content or use it with any artificial intelligence model or tool.
Printed by Galya Basol Kochav on 12/28/2025 10:24:40 AM. Copyright © 2025 National Comprehensive Cancer Network, Inc. All Rights Reserved.

positive margins and poor response may include additional local therapy such as re-excision with or without RT.

Metastatic Disease at Presentation

Approximately 10% to 20% of patients present with metastatic disease at diagnosis.[33,484,485] The number of metastases at diagnosis and complete surgical resection of all clinically detected tumor sites are of independent prognostic value in patients with primary metastatic disease at presentation.[33] Unilateral metastases and lower number of lung nodules were associated with improved outcomes with chemotherapy in patients with synchronous lung metastases.[439,440] The 2-year DFS rate was significantly higher for patients with only one or two metastatic lesions than for patients with three or more lesions (78% and 28%, respectively).[439]

Although chemotherapy is associated with improved outcomes in patients with non-metastatic, high-grade, localized osteosarcoma, the results were significantly poorer in patients with metastatic disease at presentation.[484,486-488] In a study of 57 patients with metastatic disease at presentation treated with cisplatin, doxorubicin, and a high dose of methotrexate and ifosfamide, the 2-year EFS and OS rates were 21% and 55%, respectively, compared to 75% and 94% in patients with non-metastatic disease at presentation, treated with the same chemotherapy protocol.[487] High-dose ifosfamide plus etoposide was examined in a phase II/III trial of 43 patients with newly diagnosed metastatic osteosarcoma, revealing an ORR of 59% ± 8%, but considerable toxicity.[489]

Among patients with primary metastases treated in cooperative osteosarcoma trials, long-term survival rates were higher for patients whose metastases were excised following chemotherapy and surgery of the primary tumor compared to those patients whose metastases could not be removed (48% and 5%, respectively).[490] The combination of aggressive chemotherapy with simultaneous resection of primary and metastatic lesions has also resulted in improved outcomes in patients with osteosarcoma of the extremity with lung metastases at presentation.[491]

For patients with resectable metastases (pulmonary, visceral, or skeletal) at presentation, the guidelines recommend preoperative chemotherapy followed by wide excision of the primary tumor. Chemotherapy, metastasectomy, and SRT are included as options for the management of resectable metastatic disease. In the event that pulmonary metastasectomy is not feasible, ablation procedures may be considered. A retrospective review of 83 patients with high-grade osteosarcoma and widespread metastases who underwent complete resection of the primary tumor and surgical removal of all detectable metastases followed by chemotherapy analyzed tumor characteristics, treatment regimens, and their impact on survival.[492] Nine (10.8%) patients had an initial complete remission, of which one patient remained 12.7 years later. Sixty-three of the remaining 74 patients died secondary to their disease, and 2 died from other causes. Actuarial EFS and OS after 5 years was 1.4 ± 1.4%, and 8.7 ± 3.3%, respectively. Data showed that complete microscopic resection of the primary tumor and macroscopic complete resection of metastases (and local treatment), in addition to good response to first-line chemotherapy, resulted in better outcomes when compared to individuals whose disease progressed during first-line treatment. Patients who presented with pleural effusion and metastasis at distant bones also had poorer outcomes.

In a study conducted by University of California, Los Angeles (UCLA), 16 patients (who had received either prior chemotherapy or surgery) with lung metastases from high-grade sarcomas were treated with SBRT.[306] In total, 25 lesions were identified and treated with a median SBRT dose of 54 Gy (range 36–54 Gy) in 3 to 4 fractions.[306] OS at 4 years was

Version 2.2026 © 2025 National Comprehensive Cancer Network© (NCCN©), All rights reserved. NCCN Guidelines® and this illustration may not be reproduced in any form without the express written permission of NCCN.

PLEASE NOTE that use of this NCCN Content is governed by the End-User License Agreement, and you MAY NOT distribute this Content or use it with any artificial intelligence model or tool.
Printed by Galya Basol Kochav on 12/28/2025 10:24:40 AM. Copyright © 2025 National Comprehensive Cancer Network, Inc. All Rights Reserved.

reported to be 78%.[306] In another study, 30 patients with sarcoma with pulmonary metastases received SBRT at a median dose of 50 Gy in 4 to 5 fractions.[305] Patients had received prior chemotherapy, surgery, or thoracic RT. Local control at 12 and 24 months was reported to be 94% and 86%, respectively, while OS was 76% and 43%.[305] These reports suggest that SBRT may prove to be a promising alternative to surgery for oligometastatic disease. Unresectable metastatic disease should be managed with chemotherapy and/or RT followed by reassessment of the primary site for local control.

Surveillance

Once treatment is completed, surveillance should occur every 3 months for years 1 and 2, then every 4 months for year 3, then every 6 months for years 4 and 5, and annually thereafter, as clinically indicated. Surveillance should include a complete physical exam and imaging of the primary site and chest as performed during initial disease workup. Head-to-toe FDG-PET/CT and/or bone scan (category 2B) may also be considered. Functional reassessment should be performed at every visit. CBC and other laboratory studies can be performed as clinically indicated.

Relapsed or Refractory Disease

Approximately 30% to 40% of patients with localized disease and 80% of patients presenting with metastatic disease will relapse.[493,494] The presence of solitary metastases, time to first relapse, and complete resectability of the disease at first recurrence have been reported to be the most important prognostic indicators for improved survival, whereas patients not amenable to surgery and those with a second or third recurrence have a poor prognosis.[493-498] In patients with primary non-metastatic osteosarcoma, a longer relapse-free interval to pulmonary metastases was significantly associated with better survival.[497] The prognostic significance of surgical clearance among patients with second and subsequent recurrences was also confirmed in a report of survival estimates derived from large cohorts of unselected patients treated at the COSS group trials.[499]

The combination of etoposide with cyclophosphamide or ifosfamide has been evaluated in clinical trials.[500-502] In a phase II trial of the French Society of Pediatric Oncology, high-dose ifosfamide and etoposide resulted in a response rate of 48% in patients with relapsed or refractory osteosarcoma.[501] In another phase II trial, cyclophosphamide and etoposide resulted in a 19% response rate and 35% rate of stable disease in patients with relapsed high-risk osteosarcoma.[500] PFS at 4 months was 42%.

In a non-comparative, double-blind, placebo-controlled, phase II trial (REGOBONE), the efficacy and safety of regorafenib, a multikinase inhibitor, was evaluated among patients with progressive metastatic osteosarcoma (who underwent 1–2 previous lines of chemotherapy and had a performance status of ECOG 0–1).[503] It was found that 65% of patients in the regorafenib arm exhibited non-progressive disease at 8 weeks compared to no patients in the placebo arm. In view of confirmed disease progression, 10 patients in the placebo arm were permitted to cross over to the regorafenib arm to receive treatment. The most commonly noted adverse effects associated with regorafenib included hypertension and hand-foot skin reaction. It was concluded that regorafenib displayed antitumor activity in progressive metastatic osteosarcoma, delaying disease progression. Similarly, in another randomized, double-blind phase II study (SARC024), the activity of regorafenib was again evaluated in patients with progressive metastatic osteosarcoma.[504] The study met its primary endpoint with a median PFS of 3.6 months in the regorafenib arm versus 1.7 months in the placebo arm (CI, 0.21–0.85; P = .017; HR, 0.42). The NCCN Panel has included

Version 2.2026 © 2025 National Comprehensive Cancer Network© (NCCN©), All rights reserved. NCCN Guidelines® and this illustration may not be reproduced in any form without the express written permission of NCCN.

PLEASE NOTE that use of this NCCN Content is governed by the End-User License Agreement, and you MAY NOT distribute this Content or use it with any artificial intelligence model or tool.
Printed by Galya Basol Kochav on 12/28/2025 10:24:40 AM. Copyright © 2025 National Comprehensive Cancer Network, Inc. All Rights Reserved.

regorafenib under second-line therapy for osteosarcoma (relapsed, refractory, or metastatic disease) with a category 1 recommendation.

Similar to its activity in patients with advanced Ewing sarcoma, cabozantinib, as aforementioned, also exhibited activity in patients with advanced osteosarcoma. In the CABONE trial, the primary endpoint for patients with osteosarcoma included 6-month objective response as well as 6-month non-progression.[332] Secondary endpoints included safety, best overall response, 1-year and 2-year PFS and OS, and metabolic response (evaluated by FDG-PET/CT 28 days after the first dose). Similar to that of Ewing sarcoma, the primary endpoints for patients with osteosarcoma were reached as 12% of patients showed an objective response and 33% were progression-free at 6 months. Seventeen percent of patients exhibited partial response and 62% of patients showed stable disease as their best overall response. Of those with stable disease, 33% of individuals displayed tumor shrinkage. Cabozantinib has thus been included in the guideline as a second-line treatment option for patients with relapsed, refractory, or metastatic osteosarcoma.

Single-agent gemcitabine and combination regimens such as docetaxel and gemcitabine; cyclophosphamide and topotecan; high-dose methotrexate with or without etoposide and ifosfamide; or ifosfamide, carboplatin, and etoposide have also been effective in the treatment of patients with relapsed or refractory bone sarcomas.[323,335,336,468,505-509]

Radium 223 dichloride is an alpha-emitting, bone-targeting radiopharmaceutical, and was studied in a phase I trial in 18 patients with recurrent or metastatic osteosarcoma. [510] A metabolic response was observed in 1 patient, while mixed responses were observed in 4 patients. A response in brain metastases was observed in 1 patient. The median OS time was 25 weeks.

Samarium-153 ethylene diamine tetramethylene phosphonate (Sm-153-EDTMP) is a beta-particle–emitting, bone-seeking radiopharmaceutical that was previously recommended as a second-line treatment option in the guidelines based on data in patients with locally recurrent or metastatic osteosarcoma or skeletal metastases.[511,512] However, NCCN no longer recommends Sm-153-EDTMP in the guidelines as it is no longer available in the United States.

Targeted inhibition of a variety of molecular pathways such as mTOR, SRC family of kinases, and VEGFRs are being evaluated in clinical trials to improve outcomes in patients with relapsed or refractory osteosarcoma. In a phase II trial of the Italian Sarcoma Group (n = 30), sorafenib (VEGFR inhibitor) demonstrated activity in patients with relapsed and unresectable high-grade osteosarcoma after progression of disease on standard multimodal therapy.[513] The PFS at 4 months (primary endpoint) was 46%. Median PFS and OS were 4 months and 7 months, respectively. The CBR (defined as no progression at 6 months) was 29%. Partial response and stable disease were seen in 8% and 34% of patients, respectively, and were durable for ≥6 months in 17% of patients. Sorafenib is a preferred second-line therapy option for osteosarcoma in the guidelines.

To extend the duration of activity, a study examined sorafenib combined with everolimus for patients with unresectable or relapsed high-grade osteosarcoma (n = 38).[514] Data suggested that this regimen is active in the second-line setting, but toxicity required dose reductions and/or treatment interruptions in 66% of patients. Therefore, under second-line options for patients with osteosarcoma, sorafenib in combination with everolimus is categorized under “Other Recommended” (category 2B recommendation).

The safety and efficacy of HDT/HCT in patients with locally advanced, metastatic, or relapsed osteosarcoma have also been evaluated.[515,516] In

Version 2.2026 © 2025 National Comprehensive Cancer Network© (NCCN©), All rights reserved. NCCN Guidelines® and this illustration may not be reproduced in any form without the express written permission of NCCN.

PLEASE NOTE that use of this NCCN Content is governed by the End-User License Agreement, and you MAY NOT distribute this Content or use it with any artificial intelligence model or tool.
Printed by Galya Basol Kochav on 12/28/2025 10:24:40 AM. Copyright © 2025 National Comprehensive Cancer Network, Inc. All Rights Reserved.

the Italian Sarcoma Group study, treatment with carboplatin and etoposide was followed by stem cell rescue, combined with surgery-induced complete response in chemosensitive disease.[516] Transplant-related mortality was 3.1%. The 3-year OS and DFS rates were 20% and 12%, respectively. The efficacy of this approach in patients with high-risk disease is yet to be determined in prospective randomized studies.

The optimal treatment strategy for patients with relapsed or refractory disease has yet to be defined. If relapse occurs, the patient should receive second-line chemotherapy and/or surgical resection when feasible, followed by imaging to assess treatment response. See the *Bone Cancer Systemic Therapy Agents* in the algorithm for a complete list of second-line chemotherapy regimens. Surveillance is recommended for patients with disease that responds to second-line therapy.

Patients with disease progression or relapse after second-line therapy could be treated with resection, RT[517] (that may include radiopharmaceuticals, including radium-223), embolization/ablation, or best supportive care. Participation in a clinical trial is strongly encouraged.

High-Grade Undifferentiated Pleomorphic Sarcoma of Bone

High-grade UPS of the bone most frequently arises in the appendicular skeleton and is associated with both a high rate of local recurrence and local nodal and distal metastases.[518] The addition of chemotherapy to surgery has been shown to improve clinical outcomes in patients with non-metastatic malignant fibrous histiocytoma (MFH).[519-521] In the European Osteosarcoma Intergroup study, adjuvant or neoadjuvant chemotherapy with doxorubicin and cisplatin resulted in good pathologic response rates and survival (quite comparable with those for osteosarcoma) in patients with non-metastatic MFH.[521] Median survival time was 63 months, and the 5-year PFS and OS rates were 56% and 59%, respectively. The guidelines recommend that patients with high-grade UPS of bone should be treated with regimens listed for osteosarcoma (category 2B).

Biomarker Testing and Additional Treatment Options

NCCN defines MGPT as sequencing tests that assess mutations in multiple cancer-associated genes, such as NGS.[522,523] Due to the availability of new targeted therapies, patients with bone cancer may benefit from MGPT.

In a single-center chart review study of 102 patients with advanced sarcoma (including 11% with osteosarcoma, 4% with chondrosarcoma, 3% with chordoma, and 3% with Ewing sarcoma), 93% had at least one genomic alteration and 61% had a potentially actionable alteration based on CGP. Out of the 16% of patients who received targeted therapy based on the CGP results, 50% achieved at least stable disease.[524] A multicenter prospective study of 357 patients with bone tumors including 227 with osteosarcoma, 43 with chondrosarcoma, 14 with chordoma, and 25 with GCTB (including malignant GCTB) underwent NGS to identify genomic alterations.[525] One hundred forty-five actionable targeted mutations were detected in 122 patients. Just over 66% (n = 81) of the actionable targeted mutations were identified in the osteosarcoma subgroup. Actionable targeted mutations were also reported in 17 patients with chondrosarcomas and six patients with chordomas. MGPT or another fusion panel should be considered for Ewing sarcoma to identify translocations if pathologic workup of targeted PCR, FISH, or cytogenetics is negative. NCCN also recommends that MGPT with a validated and/or FDA-approved assay should be considered to determine targeted therapy opportunities for patients with metastatic chondrosarcoma, recurrent chordoma, metastatic Ewing sarcoma, and metastatic osteosarcoma.

Version 2.2026 © 2025 National Comprehensive Cancer Network© (NCCN©), All rights reserved. NCCN Guidelines® and this illustration may not be reproduced in any form without the express written permission of NCCN.

PLEASE NOTE that use of this NCCN Content is governed by the End-User License Agreement, and you MAY NOT distribute this Content or use it with any artificial intelligence model or tool.
Printed by Galya Basol Kochav on 12/28/2025 10:24:40 AM. Copyright © 2025 National Comprehensive Cancer Network, Inc. All Rights Reserved.

Treatment Options Based on Biomarker Testing Results

Data have demonstrated that tumors with TMB-high (TMB-H) or MSI-high (MSI-H)/MMR deficiency (dMMR) may respond to certain immunotherapy agents (ie, checkpoint inhibitors).

The single-arm, open-label, phase II KEYNOTE-158 study evaluated 233 patients with advanced MSI-H/dMMR noncolorectal cancers whose disease progressed following prior therapy.[526] Twenty-seven tumor types (including sarcomas) were represented in this trial. The ORR was 30.8% and the median duration of response was 47.5 months.

KEYNOTE-158 also evaluated whether TMB status was associated with outcomes in patients with previously treated advanced solid tumors who were treated with pembrolizumab.[527] Patients were evaluated for tissue TMB (tTMB) status by NGS and those with TMB-H status (defined as ≥10 mutations/megabase) exhibited clinical improvement with an ORR of 29% compared to 6% among the non–tTMB-H group. [527]

The PD-1 inhibitor nivolumab in combination with the CTLA-4 inhibitor ipilimumab was evaluated in CheckMate 848, a randomized, open-label, phase II study in patients with advanced or metastatic solid TMB-H tumors.[528] The ORR rate with nivolumab/ipilimumab was 35.3% for those with tTMB-H in an interim analysis, and 22.5% in those with high blood TMB (bTMB-H) in a final analysis.

Based on these data, the Guidelines state that testing for TMB and MMR/MSI as determined by a validated and/or FDA-approved assay can be considered for select patients with metastatic chondrosarcoma, recurrent chordoma, metastatic Ewing sarcoma, or unresectable metastatic osteosarcoma.

Pembrolizumab and nivolumab/ipilimumab are recommended as options under Useful in Certain Circumstances for those with unresectable or metastatic TMB-H (≥10 mutations/megabase) tumors whose disease progressed following prior treatment and who have no satisfactory alternative treatment options. Pembrolizumab is also included as a preferred treatment option for patients with unresectable or metastatic TMB-H (≥10 mutations/megabase) whose disease progressed following prior treatment and who have no satisfactory alternative treatment options.

The Panel does not recommend pembrolizumab or nivolumab/ipilimumab as treatment options for GCTB, which is not technically a malignant tumor.

Other molecular-guided therapy options included in the guidelines are ivosidenib for chondrosarcoma with susceptible *IDH1* mutations [133] and lapatinib for *EGFR*-positive chordomas.[218,529]

Summary

The NCCN Guidelines for Bone Cancer provide recommendations for the treatment of chondrosarcoma, osteosarcoma, chordoma, Ewing sarcoma, and GCTB. Depending on the subtype, recommended treatment modalities for bone cancer may include surgery, RT, and systemic therapy. Evaluation by a multidisciplinary team with expertise in the management of bone cancer is highly recommended prior to initiation of therapy to ensure that patients receive the most appropriate treatments. The NCCN Guidelines for Bone Cancer will continue to be updated at least once a year by the NCCN Bone Cancer Panel based on consensus and clinical evidence.

Version 2.2026 © 2025 National Comprehensive Cancer Network© (NCCN©), All rights reserved. NCCN Guidelines® and this illustration may not be reproduced in any form without the express written permission of NCCN.

PLEASE NOTE that use of this NCCN Content is governed by the End-User License Agreement, and you MAY NOT distribute this Content or use it with any artificial intelligence model or tool.
Printed by Galya Basol Kochav on 12/28/2025 10:24:40 AM. Copyright © 2025 National Comprehensive Cancer Network, Inc. All Rights Reserved.

References

1. SEER cancer statistics fact sheets: bone and joint cancer. Bethesda, MD: National Cancer Institute; 2024. Available at: https://seer.cancer.gov/statfacts/html/bones.html. Accessed July 10, 2024.

2. Siegel RL, Kratzer TB, Giaquinto AN, et al. Cancer statistics, 2025. CA Cancer J Clin 2025;n/a. Available at: https://www.ncbi.nlm.nih.gov/pubmed/39817679.

3. MD Anderson Cancer Center; Available at: https://www.mdanderson.org/cancer-types/bone-cancer.html#:~:text=In%20the%20United%20States%2C%20more,all%20cancers%20in%20this%20country. Accessed 1/16/25.

4. Primary bone cancer. National Institutes of Health; 2018. Available at: https://www.cancer.gov/types/bone/bone-fact-sheet. Accessed 1/16/25.

5. WHO Classification of Tumours Editorial board. WHO classification of tumours soft tissue and bone tumours. Vol. 3 (ed 5th): IARC Press; 2020.

6. Chondrosarcoma. In: StatPearls [Internet]: StatPearls Publishing; 2023. Available at: https://www.ncbi.nlm.nih.gov/books/NBK538132/. Accessed

7. McMaster ML, Goldstein AM, Bromley CM, et al. Chordoma: incidence and survival patterns in the United States, 1973-1995. Cancer Causes Control 2001;12:1–11. Available at: https://www.ncbi.nlm.nih.gov/pubmed/11227920.

8. Walcott BP, Nahed BV, Mohyeldin A, et al. Chordoma: current concepts, management, and future directions. Lancet Oncol 2012;13:e69–76. Available at: https://www.ncbi.nlm.nih.gov/pubmed/22300861.

9. Wedekind MF, Widemann BC, Cote G. Chordoma: Current status, problems, and future directions. Curr Probl Cancer 2021;45:100771. Available at: https://www.ncbi.nlm.nih.gov/pubmed/34266694.

10. Connolly EA, Boye K, Bonvalot S, et al. Genetic predisposition in sarcomas: clinical implications and management. EClinicalMedicine 2025;83:103203. Available at: https://www.ncbi.nlm.nih.gov/pubmed/40291347.

11. de Alava E, Gerald WL. Molecular biology of the Ewing's sarcoma/primitive neuroectodermal tumor family. J Clin Oncol 2000;18:204–213. Available at: https://www.ncbi.nlm.nih.gov/pubmed/10623711.

12. Delattre O, Zucman J, Melot T, et al. The Ewing family of tumors--a subgroup of small-round-cell tumors defined by specific chimeric transcripts. N Engl J Med 1994;331:294–299. Available at: https://www.ncbi.nlm.nih.gov/pubmed/8022439.

13. Denny CT. Gene rearrangements in Ewing's sarcoma. Cancer Invest 1996;14:83–88. Available at: https://www.ncbi.nlm.nih.gov/pubmed/8597892.

14. Burchill SA. Molecular abnormalities in Ewing's sarcoma. Expert Rev Anticancer Ther 2008;8:1675–1687. Available at: https://www.ncbi.nlm.nih.gov/pubmed/18925858.

15. Apfelbaum AA, Wrenn ED, Lawlor ER. The importance of fusion protein activity in Ewing sarcoma and the cell intrinsic and extrinsic factors that regulate it: A review. Front Oncol 2022;12:1044707. Available at: https://www.ncbi.nlm.nih.gov/pubmed/36505823.

16. Mirabello L, Zhu B, Koster R, et al. Frequency of pathogenic germline variants in cancer-susceptibility genes in patients with osteosarcoma. JAMA Oncol 2020;6:724–734. Available at: https://www.ncbi.nlm.nih.gov/pubmed/32191290.

17. Malkin D, Li FP, Strong LC, et al. Germ line p53 mutations in a familial syndrome of breast cancer, sarcomas, and other neoplasms. Science 1990;250:1233–1238. Available at: https://www.ncbi.nlm.nih.gov/pubmed/1978757.

18. McIntyre JF, Smith-Sorensen B, Friend SH, et al. Germline mutations of the p53 tumor suppressor gene in children with osteosarcoma. J Clin

Version 2.2026 © 2025 National Comprehensive Cancer Network© (NCCN©), All rights reserved. NCCN Guidelines® and this illustration may not be reproduced in any form without the express written permission of NCCN.

PLEASE NOTE that use of this NCCN Content is governed by the End-User License Agreement, and you MAY NOT distribute this Content or use it with any artificial intelligence model or tool.
Printed by Galya Basol Kochav on 12/28/2025 10:24:40 AM. Copyright © 2025 National Comprehensive Cancer Network, Inc. All Rights Reserved.

Oncol 1994;12:925–930. Available at: https://www.ncbi.nlm.nih.gov/pubmed/8164043.

19. Ognjanovic S, Olivier M, Bergemann TL, Hainaut P. Sarcomas in TP53 germline mutation carriers: a review of the IARC TP53 database. Cancer 2012;118:1387–1396. Available at: https://www.ncbi.nlm.nih.gov/pubmed/21837677.

20. Ottaviani G, Jaffe N. The etiology of osteosarcoma. Cancer Treat Res 2009;152:15–32. Available at: https://www.ncbi.nlm.nih.gov/pubmed/20213384.

21. MacCarthy A, Bayne AM, Draper GJ, et al. Non-ocular tumours following retinoblastoma in Great Britain 1951 to 2004. Br J Ophthalmol 2009;93:1159–1162. Available at: https://www.ncbi.nlm.nih.gov/pubmed/19704040.

22. Calvert GT, Randall RL, Jones KB, et al. At-risk populations for osteosarcoma: the syndromes and beyond. Sarcoma 2012;2012:152382. Available at: https://www.ncbi.nlm.nih.gov/pubmed/22550413.

23. Bielack SS, Baumhoer D, Hecker-Nolting S, et al. Osteosarcomas in retinoblastoma-survivors. A report of 28 affected patients from the Cooperative Osteosarcoma Study Group (COSS). EJC Paediatric Oncology 2024;3:100158. Available at: https://www.sciencedirect.com/science/article/pii/S2772610X24000175.

24. Kalra S, Grimer RJ, Spooner D, et al. Radiation-induced sarcomas of bone: factors that affect outcome. J Bone Joint Surg Br 2007;89:808–813. Available at: https://www.ncbi.nlm.nih.gov/pubmed/17613509.

25. Mavrogenis AF, Pala E, Guerra G, Ruggieri P. Post-radiation sarcomas. Clinical outcome of 52 Patients. J Surg Oncol 2012;105:570–576. Available at: https://www.ncbi.nlm.nih.gov/pubmed/22012601.

26. Bernstein M, Kovar H, Paulussen M, et al. Ewing's sarcoma family of tumors: current management. Oncologist 2006;11:503–519. Available at: https://www.ncbi.nlm.nih.gov/pubmed/16720851.

27. Subbiah V, Anderson P, Lazar AJ, et al. Ewing's sarcoma: standard and experimental treatment options. Curr Treat Options Oncol 2009;10:126–140. Available at: https://www.ncbi.nlm.nih.gov/pubmed/19533369.

28. Rathore R, Van Tine BA. Pathogenesis and Current Treatment of Osteosarcoma: Perspectives for Future Therapies. J Clin Med 2021;10. Available at: https://www.ncbi.nlm.nih.gov/pubmed/33809018.

29. Federman N, Bernthal N, Eilber FC, Tap WD. The multidisciplinary management of osteosarcoma. Curr Treat Options Oncol 2009;10:82–93. Available at: https://www.ncbi.nlm.nih.gov/pubmed/19238553.

30. Xu M, Wang Z, Yu XC, et al. Guideline for limb-salvage treatment of osteosarcoma. Orthop Surg 2020;12:1021–1029. Available at: https://www.ncbi.nlm.nih.gov/pubmed/32633103.

31. Early detection, diagnosis, and staging

of Ewing tumors. cancer.org: 2021. Available at: https://www.cancer.org/content/dam/CRC/PDF/Public/8621.00.pdf. Accessed July 18, 2024.

32. Cotterill SJ, Ahrens S, Paulussen M, et al. Prognostic factors in Ewing's tumor of bone: analysis of 975 patients from the European Intergroup Cooperative Ewing's Sarcoma Study Group. J Clin Oncol 2000;18:3108–3114. Available at: https://www.ncbi.nlm.nih.gov/pubmed/10963639.

33. Kager L, Zoubek A, Potschger U, et al. Primary metastatic osteosarcoma: presentation and outcome of patients treated on neoadjuvant Cooperative Osteosarcoma Study Group protocols. J Clin Oncol 2003;21:2011–2018. Available at: https://www.ncbi.nlm.nih.gov/pubmed/12743156.

34. Freedman-Cass DA, Fischer T, Alpert AB, et al. The value and process of inclusion: using sensitive, respectful, and inclusive language and images in NCCN content. J Natl Compr Canc Netw 2023;21:434–441. Available at: https://www.ncbi.nlm.nih.gov/pubmed/37156485.

Version 2.2026 © 2025 National Comprehensive Cancer Network© (NCCN©), All rights reserved. NCCN Guidelines® and this illustration may not be reproduced in any form without the express written permission of NCCN.

PLEASE NOTE that use of this NCCN Content is governed by the End-User License Agreement, and you MAY NOT distribute this Content or use it with any artificial intelligence model or tool.
Printed by Galya Basol Kochav on 12/28/2025 10:24:40 AM. Copyright © 2025 National Comprehensive Cancer Network, Inc. All Rights Reserved.

35. Amin MB, Edge SB, Greene FL, et al. AJCC Cancer Staging Manual, 8th edition. New York: Springer; 2017.

36. Lee SJ, Schover LR, Partridge AH, et al. American Society of Clinical Oncology recommendations on fertility preservation in cancer patients. J Clin Oncol 2006;24:2917–2931. Available at: https://www.ncbi.nlm.nih.gov/pubmed/16651642.

37. Rougraff BT, Kneisl JS, Simon MA. Skeletal metastases of unknown origin. A prospective study of a diagnostic strategy. J Bone Joint Surg Am 1993;75:1276–1281. Available at: https://www.ncbi.nlm.nih.gov/pubmed/8408149.

38. Schuetze SM. Utility of positron emission tomography in sarcomas. Curr Opin Oncol 2006;18:369–373. Available at: https://www.ncbi.nlm.nih.gov/pubmed/16721133.

39. Volker T, Denecke T, Steffen I, et al. Positron emission tomography for staging of pediatric sarcoma patients: results of a prospective multicenter trial. J Clin Oncol 2007;25:5435–5441. Available at: https://www.ncbi.nlm.nih.gov/pubmed/18048826.

40. Heck RK, Jr., Peabody TD, Simon MA. Staging of primary malignancies of bone. CA Cancer J Clin 2006;56:366–375. Available at: https://www.ncbi.nlm.nih.gov/pubmed/17135693.

41. Lambertini M, Del Mastro L, Pescio MC, et al. Cancer and fertility preservation: international recommendations from an expert meeting. BMC Med 2016;14:1. Available at: https://www.ncbi.nlm.nih.gov/pubmed/26728489.

42. Practice Committee of the American Society for Reproductive Medicine. Electronic address aao. Fertility preservation in patients undergoing gonadotoxic therapy or gonadectomy: a committee opinion. Fertil Steril 2019;112:1022–1033. Available at: https://www.ncbi.nlm.nih.gov/pubmed/31843073.

43. Chambers M, O'Hern K, Kerr DA. Fine-needle aspiration biopsy for the diagnosis of bone and soft tissue lesions: a systematic review and meta-analysis. J Am Soc Cytopathol 2020;9:429–441. Available at: https://www.ncbi.nlm.nih.gov/pubmed/32622858.

44. Dirks M, Ewerbeck NK, Ballhause TM, et al. The diagnostic accuracy of 332 incisional biopsies in patients with malignant tumors in the musculoskeletal system. World J Surg Oncol 2023;21:4. Available at: https://www.ncbi.nlm.nih.gov/pubmed/36624456.

45. Ashford RU, McCarthy SW, Scolyer RA, et al. Surgical biopsy with intra-operative frozen section. An accurate and cost-effective method for diagnosis of musculoskeletal sarcomas. J Bone Joint Surg Br 2006;88:1207–1211. Available at: https://www.ncbi.nlm.nih.gov/pubmed/16943474.

46. Skrzynski MC, Biermann JS, Montag A, Simon MA. Diagnostic accuracy and charge-savings of outpatient core needle biopsy compared with open biopsy of musculoskeletal tumors. J Bone Joint Surg Am 1996;78:644–649. Available at: https://www.ncbi.nlm.nih.gov/pubmed/8642019.

47. Welker JA, Henshaw RM, Jelinek J, et al. The percutaneous needle biopsy is safe and recommended in the diagnosis of musculoskeletal masses. Cancer 2000;89:2677–2686. Available at: https://www.ncbi.nlm.nih.gov/pubmed/11135231.

48. Mitsuyoshi G, Naito N, Kawai A, et al. Accurate diagnosis of musculoskeletal lesions by core needle biopsy. J Surg Oncol 2006;94:21–27. Available at: https://www.ncbi.nlm.nih.gov/pubmed/16788939.

49. Adams SC, Potter BK, Pitcher DJ, Temple HT. Office-based core needle biopsy of bone and soft tissue malignancies: an accurate alternative to open biopsy with infrequent complications. Clin Orthop Relat Res 2010;468:2774–2780. Available at: https://www.ncbi.nlm.nih.gov/pubmed/20582496.

50. Rimondi E, Rossi G, Bartalena T, et al. Percutaneous CT-guided biopsy of the musculoskeletal system: results of 2027 cases. Eur J Radiol 2011;77:34–42. Available at: https://www.ncbi.nlm.nih.gov/pubmed/20832220.

Version 2.2026 © 2025 National Comprehensive Cancer Network© (NCCN©), All rights reserved. NCCN Guidelines® and this illustration may not be reproduced in any form without the express written permission of NCCN.

PLEASE NOTE that use of this NCCN Content is governed by the End-User License Agreement, and you MAY NOT distribute this Content or use it with any artificial intelligence model or tool.
Printed by Galya Basol Kochav on 12/28/2025 10:24:40 AM. Copyright © 2025 National Comprehensive Cancer Network, Inc. All Rights Reserved.

51. Gogna A, Peh WC, Munk PL. Image-guided musculoskeletal biopsy. Radiol Clin North Am 2008;46:455–473, v. Available at: https://www.ncbi.nlm.nih.gov/pubmed/18707957.

52. Mankin HJ, Mankin CJ, Simon MA. The hazards of the biopsy, revisited. Members of the Musculoskeletal Tumor Society. J Bone Joint Surg Am 1996;78:656–663. Available at: https://www.ncbi.nlm.nih.gov/pubmed/8642021.

53. Liu PT, Valadez SD, Chivers FS, et al. Anatomically based guidelines for core needle biopsy of bone tumors: implications for limb-sparing surgery. Radiographics 2007;27:189–205; discussion 206. Available at: https://www.ncbi.nlm.nih.gov/pubmed/17235007.

54. Huang AJ, Kattapuram SV. Musculoskeletal neoplasms: biopsy and intervention. Radiol Clin North Am 2011;49:1287–1305, vii. Available at: https://www.ncbi.nlm.nih.gov/pubmed/22024299.

55. Davies NM, Livesley PJ, Cannon SR. Recurrence of an osteosarcoma in a needle biopsy track. J Bone Joint Surg Br 1993;75:977–978. Available at: https://www.ncbi.nlm.nih.gov/pubmed/8245097.

56. Saghieh S, Masrouha KZ, Musallam KM, et al. The risk of local recurrence along the core-needle biopsy tract in patients with bone sarcomas. Iowa Orthop J 2010;30:80–83. Available at: https://www.ncbi.nlm.nih.gov/pubmed/21045976.

57. Seeger LL. Revisiting tract seeding and compartmental anatomy for percutaneous image-guided musculoskeletal biopsies. Skeletal Radiol 2019;48:499–501. Available at: https://www.ncbi.nlm.nih.gov/pubmed/30613932.

58. Yang YJ, Damron TA. Comparison of needle core biopsy and fine-needle aspiration for diagnostic accuracy in musculoskeletal lesions. Arch Pathol Lab Med 2004;128:759–764. Available at: https://www.ncbi.nlm.nih.gov/pubmed/15214827.

59. Patel S, DeLaney TF. Advanced-technology radiation therapy for bone sarcomas. Cancer Control 2008;15:21–37. Available at: https://www.ncbi.nlm.nih.gov/pubmed/18094658.

60. McGovern SL, Mahajan A. Progress in radiotherapy for pediatric sarcomas. Curr Oncol Rep 2012;14:320–326. Available at: https://www.ncbi.nlm.nih.gov/pubmed/22532264.

61. Gelderblom H, Hogendoorn PC, Dijkstra SD, et al. The clinical approach towards chondrosarcoma. Oncologist 2008;13:320–329. Available at: https://www.ncbi.nlm.nih.gov/pubmed/18378543.

62. Riedel RF, Larrier N, Dodd L, et al. The clinical management of chondrosarcoma. Curr Treat Options Oncol 2009;10:94–106. Available at: https://www.ncbi.nlm.nih.gov/pubmed/19238552.

63. Mankin HJ, Cantley KP, Schiller AL, Lippiello L. The biology of human chondrosarcoma. II. Variation in chemical composition among types and subtypes of benign and malignant cartilage tumors. J Bone Joint Surg Am 1980;62:176–188. Available at: https://www.ncbi.nlm.nih.gov/pubmed/7358749.

64. Nicolle R, Ayadi M, Gomez-Brouchet A, et al. Integrated molecular characterization of chondrosarcoma reveals critical determinants of disease progression. Nat Commun 2019;10:4622. Available at: https://www.ncbi.nlm.nih.gov/pubmed/31604924.

65. Chow W, Frankel P, Ruel C, et al. Results of a prospective phase 2 study of pazopanib in patients with surgically unresectable or metastatic chondrosarcoma. Cancer 2020;126:105–111. Available at: https://www.ncbi.nlm.nih.gov/pubmed/31509242.

66. Verdegaal SH, Bovee JV, Pansuriya TC, et al. Incidence, predictive factors, and prognosis of chondrosarcoma in patients with Ollier disease and Maffucci syndrome: an international multicenter study of 161 patients. Oncologist 2011;16:1771–1779. Available at: https://www.ncbi.nlm.nih.gov/pubmed/22147000.

Version 2.2026 © 2025 National Comprehensive Cancer Network© (NCCN©), All rights reserved. NCCN Guidelines® and this illustration may not be reproduced in any form without the express written permission of NCCN.

PLEASE NOTE that use of this NCCN Content is governed by the End-User License Agreement, and you MAY NOT distribute this Content or use it with any artificial intelligence model or tool.
Printed by Galya Basol Kochav on 12/28/2025 10:24:40 AM. Copyright © 2025 National Comprehensive Cancer Network, Inc. All Rights Reserved.

67. Ahmed AR, Tan TS, Unni KK, et al. Secondary chondrosarcoma in osteochondroma: report of 107 patients. Clin Orthop Relat Res 2003:193–206. Available at: https://www.ncbi.nlm.nih.gov/pubmed/12782876.

68. Amary MF, Damato S, Halai D, et al. Ollier disease and Maffucci syndrome are caused by somatic mosaic mutations of IDH1 and IDH2. Nat Genet 2011;43:1262–1265. Available at: https://www.ncbi.nlm.nih.gov/pubmed/22057236.

69. Pansuriya TC, van Eijk R, d'Adamo P, et al. Somatic mosaic IDH1 and IDH2 mutations are associated with enchondroma and spindle cell hemangioma in Ollier disease and Maffucci syndrome. Nat Genet 2011;43:1256–1261. Available at: https://www.ncbi.nlm.nih.gov/pubmed/22057234.

70. Amary MF, Bacsi K, Maggiani F, et al. IDH1 and IDH2 mutations are frequent events in central chondrosarcoma and central and periosteal chondromas but not in other mesenchymal tumours. J Pathol 2011;224:334–343. Available at: https://www.ncbi.nlm.nih.gov/pubmed/21598255.

71. Meijer D, de Jong D, Pansuriya TC, et al. Genetic characterization of mesenchymal, clear cell, and dedifferentiated chondrosarcoma. Genes Chromosomes Cancer 2012;51:899–909. Available at: https://www.ncbi.nlm.nih.gov/pubmed/22674453.

72. Amer KM, Munn M, Congiusta D, et al. Survival and Prognosis of Chondrosarcoma Subtypes: SEER Database Analysis. J Orthop Res 2020;38:311–319. Available at: https://www.ncbi.nlm.nih.gov/pubmed/31498474.

73. Kilpatrick SE, Inwards CY, Fletcher CD, et al. Myxoid chondrosarcoma (chordoid sarcoma) of bone: a report of two cases and review of the literature. Cancer 1997;79:1903–1910. Available at: https://www.ncbi.nlm.nih.gov/pubmed/9149016.

74. Antonescu CR, Argani P, Erlandson RA, et al. Skeletal and extraskeletal myxoid chondrosarcoma: a comparative clinicopathologic, ultrastructural, and molecular study. Cancer 1998;83:1504–1521. Available at: https://www.ncbi.nlm.nih.gov/pubmed/9781944.

75. Schneiderman BA, Kliethermes SA, Nystrom LM. Survival in Mesenchymal Chondrosarcoma Varies Based on Age and Tumor Location: A Survival Analysis of the SEER Database. Clin Orthop Relat Res 2017;475:799–805. Available at: https://www.ncbi.nlm.nih.gov/pubmed/26975384.

76. Hirabayashi Y, Ishida T, Yoshida MA, et al. Translocation (9;22)(q22;q12). A recurrent chromosome abnormality in extraskeletal myxoid chondrosarcoma. Cancer Genet Cytogenet 1995;81:33–37. Available at: https://www.ncbi.nlm.nih.gov/pubmed/7773957.

77. Panagopoulos I, Mertens F, Isaksson M, et al. Molecular genetic characterization of the EWS/CHN and RBP56/CHN fusion genes in extraskeletal myxoid chondrosarcoma. Genes Chromosomes Cancer 2002;35:340–352. Available at: https://www.ncbi.nlm.nih.gov/pubmed/12378528.

78. Nishio J, Iwasaki H, Nabeshima K, Naito M. Cytogenetics and molecular genetics of myxoid soft-tissue sarcomas. Genet Res Int 2011;2011:497148. Available at: https://www.ncbi.nlm.nih.gov/pubmed/22567356.

79. Paioli A, Gronchi A, Palmerini E, et al. Extraskeletal myxoid chondrosarcoma: A retrospective analysis of 69 patients with localized disease and molecularly confirmed diagnosis [abstract]. ASCO Meeting Abstracts 2014;32:10589. Available at: http://ascopubs.org/doi/abs/10.1200/jco.2014.32.15_suppl.10589.

80. Bruns J, Elbracht M, Niggemeyer O. Chondrosarcoma of bone: an oncological and functional follow-up study. Ann Oncol 2001;12:859–864. Available at: https://www.ncbi.nlm.nih.gov/pubmed/11484965.

81. Bergh P, Gunterberg B, Meis-Kindblom JM, Kindblom LG. Prognostic factors and outcome of pelvic, sacral, and spinal chondrosarcomas: a center-based study of 69 cases. Cancer 2001;91:1201–1212. Available at: https://www.ncbi.nlm.nih.gov/pubmed/11283918.

Version 2.2026 © 2025 National Comprehensive Cancer Network© (NCCN©), All rights reserved. NCCN Guidelines® and this illustration may not be reproduced in any form without the express written permission of NCCN.

PLEASE NOTE that use of this NCCN Content is governed by the End-User License Agreement, and you MAY NOT distribute this Content or use it with any artificial intelligence model or tool.
Printed by Galya Basol Kochav on 12/28/2025 10:24:40 AM. Copyright © 2025 National Comprehensive Cancer Network, Inc. All Rights Reserved.

82. Enneking WF, Dunham WK. Resection and reconstruction for primary neoplasms involving the innominate bone. J Bone Joint Surg Am 1978;60:731–746. Available at: https://www.ncbi.nlm.nih.gov/pubmed/701308.

83. Norman A, Sissons HA. Radiographic hallmarks of peripheral chondrosarcoma. Radiology 1984;151:589–596. Available at: https://www.ncbi.nlm.nih.gov/pubmed/6718712.

84. Sanerkin NG. The diagnosis and grading of chondrosarcoma of bone: a combined cytologic and histologic approach. Cancer 1980;45:582–594. Available at: https://www.ncbi.nlm.nih.gov/pubmed/6928110.

85. Lee FY, Mankin HJ, Fondren G, et al. Chondrosarcoma of bone: an assessment of outcome. J Bone Joint Surg Am 1999;81:326–338. Available at: https://www.ncbi.nlm.nih.gov/pubmed/10199270.

86. Fiorenza F, Abudu A, Grimer RJ, et al. Risk factors for survival and local control in chondrosarcoma of bone. J Bone Joint Surg Br 2002;84:93–99. Available at: https://www.ncbi.nlm.nih.gov/pubmed/11837841.

87. Fayad LM, Ahlawat S, Khan MS, McCarthy E. Chondrosarcomas of the hands and feet: A case series and systematic review of the literature. Eur J Radiol 2015;84:2004–2012. Available at: https://www.ncbi.nlm.nih.gov/pubmed/26189572.

88. Nota SP, Braun Y, Schwab JH, et al. The Identification of Prognostic Factors and Survival Statistics of Conventional Central Chondrosarcoma. Sarcoma 2015;2015:623746. Available at: https://www.ncbi.nlm.nih.gov/pubmed/26633939.

89. Giuffrida AY, Burgueno JE, Koniaris LG, et al. Chondrosarcoma in the United States (1973 to 2003): an analysis of 2890 cases from the SEER database. J Bone Joint Surg Am 2009;91:1063–1072. Available at: https://www.ncbi.nlm.nih.gov/pubmed/19411454.

90. Andreou D, Gilg MM, Gosheger G, et al. Metastatic potential of grade I chondrosarcoma of bone: results of a multi-institutional study. Ann Surg Oncol 2016;23:120–125. Available at: https://www.ncbi.nlm.nih.gov/pubmed/26350369.

91. Sheth DS, Yasko AW, Johnson ME, et al. Chondrosarcoma of the pelvis. Prognostic factors for 67 patients treated with definitive surgery. Cancer 1996;78:745–750. Available at: https://www.ncbi.nlm.nih.gov/pubmed/8756367.

92. Pring ME, Weber KL, Unni KK, Sim FH. Chondrosarcoma of the pelvis. A review of sixty-four cases. J Bone Joint Surg Am 2001;83:1630–1642. Available at: https://www.ncbi.nlm.nih.gov/pubmed/11701784.

93. Funovics PT, Panotopoulos J, Sabeti-Aschraf M, et al. Low-grade chondrosarcoma of bone: experiences from the Vienna Bone and Soft Tissue Tumour Registry. Int Orthop 2011;35:1049–1056. Available at: https://www.ncbi.nlm.nih.gov/pubmed/20803012.

94. Andreou D, Ruppin S, Fehlberg S, et al. Survival and prognostic factors in chondrosarcoma: results in 115 patients with long-term follow-up. Acta Orthop 2011;82:749–755. Available at: https://www.ncbi.nlm.nih.gov/pubmed/22066552.

95. Veth R, Schreuder B, van Beem H, et al. Cryosurgery in aggressive, benign, and low-grade malignant bone tumours. Lancet Oncol 2005;6:25–34. Available at: https://www.ncbi.nlm.nih.gov/pubmed/15629273.

96. Ahlmann ER, Menendez LR, Fedenko AN, Learch T. Influence of cryosurgery on treatment outcome of low-grade chondrosarcoma. Clin Orthop Relat Res 2006;451:201–207. Available at: https://www.ncbi.nlm.nih.gov/pubmed/16788412.

97. Mohler DG, Chiu R, McCall DA, Avedian RS. Curettage and cryosurgery for low-grade cartilage tumors is associated with low recurrence and high function. Clin Orthop Relat Res 2010;468:2765–2773. Available at: http://www.ncbi.nlm.nih.gov/pubmed/20574801.

98. Leerapun T, Hugate RR, Inwards CY, et al. Surgical management of conventional grade I chondrosarcoma of long bones. Clin Orthop Relat

Version 2.2026 © 2025 National Comprehensive Cancer Network© (NCCN©), All rights reserved. NCCN Guidelines® and this illustration may not be reproduced in any form without the express written permission of NCCN.

PLEASE NOTE that use of this NCCN Content is governed by the End-User License Agreement, and you MAY NOT distribute this Content or use it with any artificial intelligence model or tool.
Printed by Galya Basol Kochav on 12/28/2025 10:24:40 AM. Copyright © 2025 National Comprehensive Cancer Network, Inc. All Rights Reserved.

Res 2007;463:166–172. Available at: https://www.ncbi.nlm.nih.gov/pubmed/17632422.

99. Donati D, Colangeli S, Colangeli M, et al. Surgical treatment of grade I central chondrosarcoma. Clin Orthop Relat Res 2010;468:581–589. Available at: https://www.ncbi.nlm.nih.gov/pubmed/19727994.

100. Hickey M, Farrokhyar F, Deheshi B, et al. A systematic review and meta-analysis of intralesional versus wide resection for intramedullary grade I chondrosarcoma of the extremities. Ann Surg Oncol 2011;18:1705–1709. Available at: https://www.ncbi.nlm.nih.gov/pubmed/21258968.

101. Chen X, Yu LJ, Peng HM, et al. Is intralesional resection suitable for central grade 1 chondrosarcoma: A systematic review and updated meta-analysis. Eur J Surg Oncol 2017;43:1718–1726. Available at: https://www.ncbi.nlm.nih.gov/pubmed/28666625.

102. Gonzalez Del Pino J, Lozano Calderon SA, Chebib I, Jupiter JB. Intralesional versus wide resection of low-grade chondrosarcomas of the hand. J Hand Surg Am 2016;41:541–549 e545. Available at: https://www.ncbi.nlm.nih.gov/pubmed/26803570.

103. Dierselhuis EF, Goulding KA, Stevens M, Jutte PC. Intralesional treatment versus wide resection for central low-grade chondrosarcoma of the long bones. Cochrane Database Syst Rev 2019;3:CD010778. Available at: https://www.ncbi.nlm.nih.gov/pubmed/30845364.

104. Ravindran PK, Keizer ME, Kunst H, et al. Skull-Base Chondrosarcoma: A Systematic Review of the Role of Postoperative Radiotherapy. Cancers (Basel) 2024;16:856. Available at: https://www.ncbi.nlm.nih.gov/pubmed/38473218.

105. Indelicato DJ, Rotondo RL, Begosh-Mayne D, et al. A Prospective Outcomes Study of Proton Therapy for Chordomas and Chondrosarcomas of the Spine. Int J Radiat Oncol Biol Phys 2016;95:297–303. Available at: https://www.ncbi.nlm.nih.gov/pubmed/27084648.

106. Hug EB, Loredo LN, Slater JD, et al. Proton radiation therapy for chordomas and chondrosarcomas of the skull base. J Neurosurg 1999;91:432–439. Available at: https://www.ncbi.nlm.nih.gov/pubmed/10470818.

107. Munzenrider JE, Liebsch NJ. Proton therapy for tumors of the skull base. Strahlenther Onkol 1999;175 Suppl 2:57–63. Available at: https://www.ncbi.nlm.nih.gov/pubmed/10394399.

108. Noel G, Habrand JL, Mammar H, et al. Combination of photon and proton radiation therapy for chordomas and chondrosarcomas of the skull base: the Centre de Protontherapie D'Orsay experience. Int J Radiat Oncol Biol Phys 2001;51:392–398. Available at: https://www.ncbi.nlm.nih.gov/pubmed/11567813.

109. Noel G, Feuvret L, Ferrand R, et al. Radiotherapeutic factors in the management of cervical-basal chordomas and chondrosarcomas. Neurosurgery 2004;55:1252–1260; discussion 1260–1252. Available at: https://www.ncbi.nlm.nih.gov/pubmed/15574207.

110. Ares C, Hug EB, Lomax AJ, et al. Effectiveness and safety of spot scanning proton radiation therapy for chordomas and chondrosarcomas of the skull base: first long-term report. Int J Radiat Oncol Biol Phys 2009;75:1111–1118. Available at: https://www.ncbi.nlm.nih.gov/pubmed/19386442.

111. Amichetti M, Amelio D, Cianchetti M, et al. A systematic review of proton therapy in the treatment of chondrosarcoma of the skull base. Neurosurg Rev 2010;33:155–165. Available at: https://www.ncbi.nlm.nih.gov/pubmed/19921291.

112. DeLaney TF, Liebsch NJ, Pedlow FX, et al. Long-term results of Phase II study of high dose photon/proton radiotherapy in the management of spine chordomas, chondrosarcomas, and other sarcomas. J Surg Oncol 2014;110:115–122. Available at: https://www.ncbi.nlm.nih.gov/pubmed/24752878.

113. Sahgal A, Chan MW, Atenafu EG, et al. Image-guided, intensity-modulated radiation therapy (IG-IMRT) for skull base chordoma and

Version 2.2026 © 2025 National Comprehensive Cancer Network© (NCCN©), All rights reserved. NCCN Guidelines® and this illustration may not be reproduced in any form without the express written permission of NCCN.

PLEASE NOTE that use of this NCCN Content is governed by the End-User License Agreement, and you MAY NOT distribute this Content or use it with any artificial intelligence model or tool.
Printed by Galya Basol Kochav on 12/28/2025 10:24:40 AM. Copyright © 2025 National Comprehensive Cancer Network, Inc. All Rights Reserved.

chondrosarcoma: preliminary outcomes. Neuro Oncol 2015;17:889–894. Available at: https://www.ncbi.nlm.nih.gov/pubmed/25543126.

114. Dastgheyb SS, Dreyfuss AD, LaRiviere MJ, et al. A prospective phase I/II clinical trial of high-dose proton therapy for chordomas and chondrosarcomas. Adv Radiat Oncol 2024;9:101456. Available at: https://www.ncbi.nlm.nih.gov/pubmed/38550376.

115. Schulz-Ertner D, Nikoghosyan A, Thilmann C, et al. Results of carbon ion radiotherapy in 152 patients. Int J Radiat Oncol Biol Phys 2004;58:631–640. Available at: https://www.ncbi.nlm.nih.gov/pubmed/14751537.

116. Schulz-Ertner D, Nikoghosyan A, Hof H, et al. Carbon ion radiotherapy of skull base chondrosarcomas. Int J Radiat Oncol Biol Phys 2007;67:171–177. Available at: https://www.ncbi.nlm.nih.gov/pubmed/17056193.

117. Imai R, Kamada T, Araki N, et al. Clinical efficacy of carbon ion radiotherapy for unresectable chondrosarcomas. Anticancer Res 2017;37:6959–6964. Available at: https://www.ncbi.nlm.nih.gov/pubmed/29187480.

118. Kano H, Sheehan J, Sneed PK, et al. Skull base chondrosarcoma radiosurgery: report of the North American Gamma Knife Consortium. J Neurosurg 2015;123:1268–1275. Available at: https://www.ncbi.nlm.nih.gov/pubmed/26115468.

119. Monga V, Mani H, Hirbe A, Milhem M. Non-conventional treatments for conventional chondrosarcoma. Cancers (Basel) 2020;12. Available at: https://www.ncbi.nlm.nih.gov/pubmed/32707689.

120. Mitchell AD, Ayoub K, Mangham DC, et al. Experience in the treatment of dedifferentiated chondrosarcoma. J Bone Joint Surg Br 2000;82:55–61. Available at: https://www.ncbi.nlm.nih.gov/pubmed/10697315.

121. Dickey ID, Rose PS, Fuchs B, et al. Dedifferentiated chondrosarcoma: the role of chemotherapy with updated outcomes. J Bone Joint Surg Am 2004;86:2412–2418. Available at: https://www.ncbi.nlm.nih.gov/pubmed/15523011.

122. Grimer RJ, Gosheger G, Taminiau A, et al. Dedifferentiated chondrosarcoma: prognostic factors and outcome from a European group. Eur J Cancer 2007;43:2060–2065. Available at: https://www.ncbi.nlm.nih.gov/pubmed/17720491.

123. Staals EL, Bacchini P, Bertoni F. Dedifferentiated central chondrosarcoma. Cancer 2006;106:2682–2691. Available at: https://www.ncbi.nlm.nih.gov/pubmed/16691621.

124. Cranmer LD, Chau B, Mantilla JG, et al. Is chemotherapy associated with improved overall survival in patients with dedifferentiated chondrosarcoma? A SEER database analysis. Clin Orthop Relat Res 2022;480:748–758. Available at: https://www.ncbi.nlm.nih.gov/pubmed/34648466.

125. Frezza AM, Cesari M, Baumhoer D, et al. Mesenchymal chondrosarcoma: prognostic factors and outcome in 113 patients. A European Musculoskeletal Oncology Society study. Eur J Cancer 2015;51:374–381. Available at: https://www.ncbi.nlm.nih.gov/pubmed/25529371.

126. Italiano A, Mir O, Cioffi A, et al. Advanced chondrosarcomas: role of chemotherapy and survival. Ann Oncol 2013;24:2916–2922. Available at: https://www.ncbi.nlm.nih.gov/pubmed/24099780.

127. Bishop MW, Somerville JM, Bahrami A, et al. Mesenchymal Chondrosarcoma in Children and Young Adults: A Single Institution Retrospective Review. Sarcoma 2015;2015:608279. Available at: https://www.ncbi.nlm.nih.gov/pubmed/26146478.

128. Dantonello TM, Int-Veen C, Leuschner I, et al. Mesenchymal chondrosarcoma of soft tissues and bone in children, adolescents, and young adults: experiences of the CWS and COSS study groups. Cancer 2008;112:2424–2431. Available at: https://www.ncbi.nlm.nih.gov/pubmed/18438777.

Version 2.2026 © 2025 National Comprehensive Cancer Network© (NCCN©), All rights reserved. NCCN Guidelines® and this illustration may not be reproduced in any form without the express written permission of NCCN.

PLEASE NOTE that use of this NCCN Content is governed by the End-User License Agreement, and you MAY NOT distribute this Content or use it with any artificial intelligence model or tool.
Printed by Galya Basol Kochav on 12/28/2025 10:24:40 AM. Copyright © 2025 National Comprehensive Cancer Network, Inc. All Rights Reserved.

129. van Maldegem A, Conley AP, Rutkowski P, et al. Outcome of First-Line Systemic Treatment for Unresectable Conventional, Dedifferentiated, Mesenchymal, and Clear Cell Chondrosarcoma. Oncologist 2019;24:110–116. Available at: https://www.ncbi.nlm.nih.gov/pubmed/30082492.

130. Strach MC, Grimison PS, Hong A, et al. Mesenchymal chondrosarcoma: An Australian multi-centre cohort study. Cancer Med 2023;12:368–378. Available at: https://www.ncbi.nlm.nih.gov/pubmed/35603739.

131. Schuetze SM, Bolejack V, Choy E, et al. Phase 2 study of dasatinib in patients with alveolar soft part sarcoma, chondrosarcoma, chordoma, epithelioid sarcoma, or solitary fibrous tumor. Cancer 2017;123:90–97. Available at: https://www.ncbi.nlm.nih.gov/pubmed/27696380.

132. Villalobos VM, Hoffner B, Elias AD. We can study ultrarare tumors effectively in this day and age, it just takes a cooperative approach: The role of dasatinib in assorted indolent sarcomas. Cancer 2017;123:20–24. Available at: https://www.ncbi.nlm.nih.gov/pubmed/27696384.

133. Tap WD, Villalobos VM, Cote GM, et al. Phase I study of the mutant IDH1 inhibitor ivosidenib: safety and clinical activity in patients with advanced chondrosarcoma. J Clin Oncol 2020;38:1693–1701. Available at: https://www.ncbi.nlm.nih.gov/pubmed/32208957.

134. Palmerini E, Lopez Pousa A, Grignani G, et al. Nivolumab and sunitinib in patients with advanced bone sarcomas: A multicenter, single-arm, phase 2 trial. Cancer 2025;131:e35628. Available at: https://www.ncbi.nlm.nih.gov/pubmed/39540661.

135. Kostine M, Cleven AH, de Miranda NF, et al. Analysis of PD-L1, T-cell infiltrate and HLA expression in chondrosarcoma indicates potential for response to immunotherapy specifically in the dedifferentiated subtype. Mod Pathol 2016;29:1028–1037. Available at: https://www.ncbi.nlm.nih.gov/pubmed/27312065.

136. Tawbi HA, Burgess M, Bolejack V, et al. Pembrolizumab in advanced soft-tissue sarcoma and bone sarcoma (SARC028): a multicentre, two-cohort, single-arm, open-label, phase 2 trial. Lancet Oncol 2017;18:1493–1501. Available at: https://www.ncbi.nlm.nih.gov/pubmed/28988646.

137. Paoluzzi L, Cacavio A, Ghesani M, et al. Response to anti-PD1 therapy with nivolumab in metastatic sarcomas. Clin Sarcoma Res 2016;6:24. Available at: https://www.ncbi.nlm.nih.gov/pubmed/28042471.

138. Uhl M, Welzel T, Oelmann J, et al. Active raster scanning with carbon ions: reirradiation in patients with recurrent skull base chordomas and chondrosarcomas. Strahlenther Onkol 2014;190:686–691. Available at: https://www.ncbi.nlm.nih.gov/pubmed/24663287.

139. Chordoma. NORD; 2017. Available at: https://rarediseases.org/rare-diseases/chordoma/. Accessed October 7, 2024.

140. Chugh R, Tawbi H, Lucas DR, et al. Chordoma: the nonsarcoma primary bone tumor. Oncologist 2007;12:1344–1350. Available at: https://www.ncbi.nlm.nih.gov/pubmed/18055855.

141. Shih AR, Cote GM, Chebib I, et al. Clinicopathologic characteristics of poorly differentiated chordoma. Mod Pathol 2018;31:1237–1245. Available at: https://www.ncbi.nlm.nih.gov/pubmed/29483606.

142. Walhart TA, Vacca B, Hepperla AJ, et al. SMARCB1 Loss in Poorly Differentiated Chordomas Drives Tumor Progression. Am J Pathol 2023;193:456–473. Available at: https://www.ncbi.nlm.nih.gov/pubmed/36657718.

143. Lee S, Teferi N, Vivanco-Suarez J, et al. Surgical management of skull base and spinal chordomas: A case series with comprehensive review of the literature. N Am Spine Soc J 2024;20:100569. Available at: https://www.ncbi.nlm.nih.gov/pubmed/39687058.

144. Rachinger W, Eigenbrod S, Dutzmann S, et al. Male sex as a risk factor for the clinical course of skull base chordomas. J Neurosurg 2014;120:1313–1320. Available at: https://www.ncbi.nlm.nih.gov/pubmed/24405075.

Version 2.2026 © 2025 National Comprehensive Cancer Network© (NCCN©), All rights reserved. NCCN Guidelines® and this illustration may not be reproduced in any form without the express written permission of NCCN.

PLEASE NOTE that use of this NCCN Content is governed by the End-User License Agreement, and you MAY NOT distribute this Content or use it with any artificial intelligence model or tool.
Printed by Galya Basol Kochav on 12/28/2025 10:24:40 AM. Copyright © 2025 National Comprehensive Cancer Network, Inc. All Rights Reserved.

145. Yamaguchi T, Suzuki S, Ishiiwa H, Ueda Y. Intraosseous benign notochordal cell tumours: overlooked precursors of classic chordomas? Histopathology 2004;44:597–602. Available at: https://www.ncbi.nlm.nih.gov/pubmed/15186275.

146. Deshpande V, Nielsen GP, Rosenthal DI, Rosenberg AE. Intraosseous benign notochord cell tumors (BNCT): further evidence supporting a relationship to chordoma. Am J Surg Pathol 2007;31:1573–1577. Available at: http://www.ncbi.nlm.nih.gov/pubmed/17895760.

147. Sooltangos A, Bodi I, Ghimire P, et al. Do all notochordal lesions require proton beam radiotherapy? A proposed reclassification of ecchordosis physaliphora as benign notochord cell tumor. J Neurol Surg B Skull Base 2022;83:e96–e104. Available at: https://www.ncbi.nlm.nih.gov/pubmed/35832978.

148. Yamaguchi T, Iwata J, Sugihara S, et al. Distinguishing benign notochordal cell tumors from vertebral chordoma. Skeletal Radiol 2008;37:291–299. Available at: https://www.ncbi.nlm.nih.gov/pubmed/18188556.

149. Nishiguchi T, Mochizuki K, Ohsawa M, et al. Differentiating benign notochordal cell tumors from chordomas: radiographic features on MRI, CT, and tomography. AJR Am J Roentgenol 2011;196:644–650. Available at: https://www.ncbi.nlm.nih.gov/pubmed/21343509.

150. Cui JF, Hao DP, Chen HS, et al. Computed tomography and magnetic resonance imaging features of cervical chordoma. Oncol Lett 2018;16:861–865. Available at: https://www.ncbi.nlm.nih.gov/pubmed/29963156.

151. Meyers SP, Hirsch WL, Jr., Curtin HD, et al. Chordomas of the skull base: MR features. AJNR Am J Neuroradiol 1992;13:1627–1636. Available at: https://www.ncbi.nlm.nih.gov/pubmed/1442442.

152. Weber AL, Liebsch NJ, Sanchez R, Sweriduk ST, Jr. Chordomas of the skull base. Radiologic and clinical evaluation. Neuroimaging Clin N Am 1994;4:515–527. Available at: https://www.ncbi.nlm.nih.gov/pubmed/7952953.

153. Rosenthal DI, Scott JA, Mankin HJ, et al. Sacrococcygeal chordoma: magnetic resonance imaging and computed tomography. AJR Am J Roentgenol 1985;145:143–147. Available at: https://www.ncbi.nlm.nih.gov/pubmed/3873835.

154. Plathow C, Weber MA, Debus J, Kauczor HU. [Imaging of sacral chordoma: comparison between MRI and CT]. Radiologe 2005;45:63–68. Available at: https://www.ncbi.nlm.nih.gov/pubmed/15662521.

155. Sung MS, Lee GK, Kang HS, et al. Sacrococcygeal chordoma: MR imaging in 30 patients. Skeletal Radiol 2005;34:87–94. Available at: https://www.ncbi.nlm.nih.gov/pubmed/15480648.

156. Meyer JE, Lepke RA, Lindfors KK, et al. Chordomas: their CT appearance in the cervical, thoracic and lumbar spine. Radiology 1984;153:693–696. Available at: https://www.ncbi.nlm.nih.gov/pubmed/6494465.

157. Ducou le Pointe H, Brugieres P, Chevalier X, et al. Imaging of chordomas of the mobile spine. J Neuroradiol 1991;18:267–276. Available at: https://www.ncbi.nlm.nih.gov/pubmed/1765812.

158. Ferraresi V, Nuzzo C, Zoccali C, et al. Chordoma: clinical characteristics, management and prognosis of a case series of 25 patients. BMC Cancer 2010;10:22. Available at: https://www.ncbi.nlm.nih.gov/pubmed/20109225.

159. Jawad MU, Scully SP. Surgery significantly improves survival in patients with chordoma. Spine (Phila Pa 1976) 2010;35:117–123. Available at: https://www.ncbi.nlm.nih.gov/pubmed/20042964.

160. Patel S, Nunna RS, Nie J, et al. Incidence, management, and outcomes of adult spinal chordoma patients in the United States. Global Spine J 2023;13:334–343. Available at: https://www.ncbi.nlm.nih.gov/pubmed/33583227.

161. Fuchs B, Dickey ID, Yaszemski MJ, et al. Operative management of sacral chordoma. J Bone Joint Surg Am 2005;87:2211–2216. Available at: https://www.ncbi.nlm.nih.gov/pubmed/16203885.

Version 2.2026 © 2025 National Comprehensive Cancer Network© (NCCN©), All rights reserved. NCCN Guidelines® and this illustration may not be reproduced in any form without the express written permission of NCCN.

PLEASE NOTE that use of this NCCN Content is governed by the End-User License Agreement, and you MAY NOT distribute this Content or use it with any artificial intelligence model or tool.
Printed by Galya Basol Kochav on 12/28/2025 10:24:40 AM. Copyright © 2025 National Comprehensive Cancer Network, Inc. All Rights Reserved.

162. Ruggieri P, Mavrogenis AF, Ussia G, et al. Recurrence after and complications associated with adjuvant treatments for sacral giant cell tumor. Clin Orthop Relat Res 2010;468:2954–2961. Available at: https://www.ncbi.nlm.nih.gov/pubmed/20623262.

163. Stacchiotti S, Casali PG, Lo Vullo S, et al. Chordoma of the mobile spine and sacrum: a retrospective analysis of a series of patients surgically treated at two referral centers. Ann Surg Oncol 2010;17:211–219. Available at: https://www.ncbi.nlm.nih.gov/pubmed/19847568.

164. Kayani B, Sewell MD, Tan KA, et al. Prognostic factors in the operative management of sacral chordomas. World Neurosurg 2015;84:1354–1361. Available at: https://www.ncbi.nlm.nih.gov/pubmed/26115803.

165. Forsyth PA, Cascino TL, Shaw EG, et al. Intracranial chordomas: a clinicopathological and prognostic study of 51 cases. J Neurosurg 1993;78:741–747. Available at: https://www.ncbi.nlm.nih.gov/pubmed/8468605.

166. Tzortzidis F, Elahi F, Wright D, et al. Patient outcome at long-term follow-up after aggressive microsurgical resection of cranial base chordomas. Neurosurgery 2006;59:230–237. Available at: http://www.ncbi.nlm.nih.gov/pubmed/16883163.

167. Sen C, Triana AI, Berglind N, et al. Clival chordomas: clinical management, results, and complications in 71 patients. J Neurosurg 2010;113:1059–1071. Available at: https://www.ncbi.nlm.nih.gov/pubmed/19929198.

168. Wu Z, Zhang J, Zhang L, et al. Prognostic factors for long-term outcome of patients with surgical resection of skull base chordomas-106 cases review in one institution. Neurosurg Rev 2010;33:451–456. Available at: https://www.ncbi.nlm.nih.gov/pubmed/20668904.

169. Di Maio S, Temkin N, Ramanathan D, Sekhar LN. Current comprehensive management of cranial base chordomas: 10-year meta-analysis of observational studies. J Neurosurg 2011;115:1094–1105. Available at: https://www.ncbi.nlm.nih.gov/pubmed/21819197.

170. Di Maio S, Rostomily R, Sekhar LN. Current surgical outcomes for cranial base chordomas: cohort study of 95 patients. Neurosurgery 2012;70:1355–1360; discussion 1360. Available at: https://www.ncbi.nlm.nih.gov/pubmed/22157545.

171. Radaelli S, Stacchiotti S, Ruggieri P, et al. Sacral chordoma: long-term outcome of a large series of patients surgically treated at two reference centers. Spine (Phila Pa 1976) 2016;41:1049–1057. Available at: https://www.ncbi.nlm.nih.gov/pubmed/27054448.

172. Boriani S, Bandiera S, Biagini R, et al. Chordoma of the mobile spine: fifty years of experience. Spine (Phila Pa 1976) 2006;31:493–503. Available at: https://www.ncbi.nlm.nih.gov/pubmed/16481964.

173. Meng T, Yin H, Li B, et al. Clinical features and prognostic factors of patients with chordoma in the spine: a retrospective analysis of 153 patients in a single center. Neuro Oncol 2015;17:725–732. Available at: https://www.ncbi.nlm.nih.gov/pubmed/25488908.

174. Goumenos S, Kakouratos G, Trikoupis I, et al. Clinical Outcome after Surgical Treatment of Sacral Chordomas: A Single-Center Retrospective Cohort of 27 Patients. Cancers (Basel) 2024;16. Available at: https://www.ncbi.nlm.nih.gov/pubmed/38473334.

175. Ahmed AT, Abdel-Rahman O, Morsy M, et al. Management of sacrococcygeal chordoma: a systematic review and meta-analysis of observational studies. Spine (Phila Pa 1976) 2018;43:E1157–E1169. Available at: https://www.ncbi.nlm.nih.gov/pubmed/29538244.

176. Moojen WA, Vleggeert-Lankamp CL, Krol AD, Dijkstra SP. Long-term results: adjuvant radiotherapy in en bloc resection of sacrococcygeal chordoma is advisable. Spine (Phila Pa 1976) 2011;36:E656–661. Available at: https://www.ncbi.nlm.nih.gov/pubmed/21217422.

177. Rotondo RL, Folkert W, Liebsch NJ, et al. High-dose proton-based radiation therapy in the management of spine chordomas: outcomes and clinicopathological prognostic factors. J Neurosurg Spine 2015;23:788–797. Available at: https://www.ncbi.nlm.nih.gov/pubmed/26340383.

Version 2.2026 © 2025 National Comprehensive Cancer Network© (NCCN©), All rights reserved. NCCN Guidelines® and this illustration may not be reproduced in any form without the express written permission of NCCN.

PLEASE NOTE that use of this NCCN Content is governed by the End-User License Agreement, and you MAY NOT distribute this Content or use it with any artificial intelligence model or tool.
Printed by Galya Basol Kochav on 12/28/2025 10:24:40 AM. Copyright © 2025 National Comprehensive Cancer Network, Inc. All Rights Reserved.

178. Catton C, O'Sullivan B, Bell R, et al. Chordoma: long-term follow-up after radical photon irradiation. Radiother Oncol 1996;41:67–72. Available at: https://www.ncbi.nlm.nih.gov/pubmed/8961370.

179. Wagner TD, Kobayashi W, Dean S, et al. Combination short-course preoperative irradiation, surgical resection, and reduced-field high-dose postoperative irradiation in the treatment of tumors involving the bone. Int J Radiat Oncol Biol Phys 2009;73:259–266. Available at: https://www.ncbi.nlm.nih.gov/pubmed/19100921.

180. Pennicooke B, Laufer I, Sahgal A, et al. Safety and localcControl of radiation therapy for chordoma of the spine and sacrum: a systematic review. Spine (Phila Pa 1976) 2016;41 Suppl 20:S186–S192. Available at: https://www.ncbi.nlm.nih.gov/pubmed/27509195.

181. Foweraker KL, Burton KE, Maynard SE, et al. High-dose radiotherapy in the management of chordoma and chondrosarcoma of the skull base and cervical spine: Part 1--Clinical outcomes. Clin Oncol (R Coll Radiol) 2007;19:509–516. Available at: https://www.ncbi.nlm.nih.gov/pubmed/17524633.

182. Potluri S, Jefferies SJ, Jena R, et al. Residual postoperative tumour volume predicts outcome after high-dose radiotherapy for chordoma and chondrosarcoma of the skull base and spine. Clin Oncol (R Coll Radiol) 2011;23:199–208. Available at: https://www.ncbi.nlm.nih.gov/pubmed/20980136.

183. Jian BJ, Bloch OG, Yang I, et al. Adjuvant radiation therapy and chondroid chordoma subtype are associated with a lower tumor recurrence rate of cranial chordoma. J Neurooncol 2010;98:101–108. Available at: https://www.ncbi.nlm.nih.gov/pubmed/19953297.

184. Yasuda M, Bresson D, Chibbaro S, et al. Chordomas of the skull base and cervical spine: clinical outcomes associated with a multimodal surgical resection combined with proton-beam radiation in 40 patients. Neurosurg Rev 2012;35:171–182; discussion 182–173. Available at: https://www.ncbi.nlm.nih.gov/pubmed/21863225.

185. McDonald MW, Linton OR, Moore MG, et al. Influence of residual tumor volume and radiation dose coverage in outcomes for clival chordoma. Int J Radiat Oncol Biol Phys 2016;95:304–311. Available at: https://www.ncbi.nlm.nih.gov/pubmed/26519991.

186. Dial BL, Kerr DL, Lazarides AL, et al. The role of radiotherapy for chordoma patients managed with surgery: analysis of the National Cancer Database. Spine (Phila Pa 1976) 2020;45:E742–E751. Available at: https://www.ncbi.nlm.nih.gov/pubmed/32032324.

187. Fagundes MA, Hug EB, Liebsch NJ, et al. Radiation therapy for chordomas of the base of skull and cervical spine: patterns of failure and outcome after relapse. Int J Radiat Oncol Biol Phys 1995;33:579–584. Available at: https://www.ncbi.nlm.nih.gov/pubmed/7558946.

188. Noel G, Feuvret L, Calugaru V, et al. Chordomas of the base of the skull and upper cervical spine. One hundred patients irradiated by a 3D conformal technique combining photon and proton beams. Acta Oncol 2005;44:700–708. Available at: https://www.ncbi.nlm.nih.gov/pubmed/16227160.

189. Park L, Delaney TF, Liebsch NJ, et al. Sacral chordomas: Impact of high-dose proton/photon-beam radiation therapy combined with or without surgery for primary versus recurrent tumor. Int J Radiat Oncol Biol Phys 2006;65:1514–1521. Available at: http://www.ncbi.nlm.nih.gov/pubmed/16757128.

190. Amichetti M, Cianchetti M, Amelio D, et al. Proton therapy in chordoma of the base of the skull: a systematic review. Neurosurg Rev 2009;32:403–416. Available at: https://www.ncbi.nlm.nih.gov/pubmed/19319583.

191. Staab A, Rutz HP, Ares C, et al. Spot-scanning-based proton therapy for extracranial chordoma. Int J Radiat Oncol Biol Phys 2011;81:e489–496. Available at: https://www.ncbi.nlm.nih.gov/pubmed/21497457.

192. Rutz HP, Weber DC, Sugahara S, et al. Extracranial chordoma: Outcome in patients treated with function-preserving surgery followed by spot-scanning proton beam irradiation. Int J Radiat Oncol Biol Phys

Version 2.2026 © 2025 National Comprehensive Cancer Network© (NCCN©), All rights reserved. NCCN Guidelines® and this illustration may not be reproduced in any form without the express written permission of NCCN.

PLEASE NOTE that use of this NCCN Content is governed by the End-User License Agreement, and you MAY NOT distribute this Content or use it with any artificial intelligence model or tool.
Printed by Galya Basol Kochav on 12/28/2025 10:24:40 AM. Copyright © 2025 National Comprehensive Cancer Network, Inc. All Rights Reserved.

2007;67:512–520. Available at: https://www.ncbi.nlm.nih.gov/pubmed/17084540.

193. Hug EB, Pelak M, Frank SJ, Fossati P. A Review of Particle Therapy for Skull Base Tumors: Modern Considerations and Future Directions. Int J Part Ther 2021;8:168–178. Available at: https://www.ncbi.nlm.nih.gov/pubmed/34285944.

194. Schulz-Ertner D, Karger CP, Feuerhake A, et al. Effectiveness of carbon ion radiotherapy in the treatment of skull-base chordomas. Int J Radiat Oncol Biol Phys 2007;68:449–457. Available at: https://www.ncbi.nlm.nih.gov/pubmed/17363188.

195. Takahashi S, Kawase T, Yoshida K, et al. Skull base chordomas: efficacy of surgery followed by carbon ion radiotherapy. Acta Neurochir (Wien) 2009;151:759–769. Available at: https://www.ncbi.nlm.nih.gov/pubmed/19434365.

196. Nishida Y, Kamada T, Imai R, et al. Clinical outcome of sacral chordoma with carbon ion radiotherapy compared with surgery. Int J Radiat Oncol Biol Phys 2011;79:110–116. Available at: https://www.ncbi.nlm.nih.gov/pubmed/20400242.

197. Imai R, Kamada T, Araki N, et al. Carbon ion radiation therapy for unresectable sacral chordoma: an analysis of 188 cases. Int J Radiat Oncol Biol Phys 2016;95:322–327. Available at: https://www.ncbi.nlm.nih.gov/pubmed/27084649.

198. Uhl M, Welzel T, Jensen A, et al. Carbon ion beam treatment in patients with primary and recurrent sacrococcygeal chordoma. Strahlenther Onkol 2015;191:597–603. Available at: https://www.ncbi.nlm.nih.gov/pubmed/25737378.

199. Holtzman AL, Seidensaal K, Iannalfi A, et al. Carbon ion radiotherapy: an evidence-based review and summary recommendations of clinical outcomes for skull-base chordomas and chondrosarcomas. Cancers (Basel) 2023;15. Available at: https://www.ncbi.nlm.nih.gov/pubmed/37894388.

200. Kabolizadeh P, Chen YL, Liebsch N, et al. Updated Outcome and Analysis of Tumor Response in Mobile Spine and Sacral Chordoma Treated With Definitive High-Dose Photon/Proton Radiation Therapy. Int J Radiat Oncol Biol Phys 2017;97:254–262. Available at: https://www.ncbi.nlm.nih.gov/pubmed/27986348.

201. Baumann BC, Lustig RA, Mazzoni S, et al. A prospective clinical trial of proton therapy for chordoma and chondrosarcoma: Feasibility assessment. J Surg Oncol 2019;120:200–205. Available at: https://www.ncbi.nlm.nih.gov/pubmed/31111502.

202. Zhou J, Yang B, Wang X, Jing Z. Comparison of the effectiveness of radiotherapy with photons and particles for chordoma after surgery: a meta-analysis. World Neurosurg 2018;117:46–53. Available at: https://www.ncbi.nlm.nih.gov/pubmed/29879512.

203. Gabriele P, Macias V, Stasi M, et al. Feasibility of intensity-modulated radiation therapy in the treatment of advanced cervical chordoma. Tumori 2003;89:298–304. Available at: https://www.ncbi.nlm.nih.gov/pubmed/12908787.

204. Yoneoka Y, Tsumanuma I, Fukuda M, et al. Cranial base chordoma--long term outcome and review of the literature. Acta Neurochir (Wien) 2008;150:773–778; discussion 778. Available at: https://www.ncbi.nlm.nih.gov/pubmed/18548191.

205. Zabel-du Bois A, Nikoghosyan A, Schwahofer A, et al. Intensity modulated radiotherapy in the management of sacral chordoma in primary versus recurrent disease. Radiother Oncol 2010;97:408–412. Available at: https://www.ncbi.nlm.nih.gov/pubmed/21056488.

206. Kano H, Iqbal FO, Sheehan J, et al. Stereotactic radiosurgery for chordoma: a report from the North American Gamma Knife Consortium. Neurosurgery 2011;68:379–389. Available at: https://www.ncbi.nlm.nih.gov/pubmed/21135744.

207. Bugoci DM, Girvigian MR, Chen JCT, et al. Photon-based fractionated stereotactic radiotherapy for postoperative treatment of skull

Version 2.2026 © 2025 National Comprehensive Cancer Network© (NCCN©), All rights reserved. NCCN Guidelines® and this illustration may not be reproduced in any form without the express written permission of NCCN.

PLEASE NOTE that use of this NCCN Content is governed by the End-User License Agreement, and you MAY NOT distribute this Content or use it with any artificial intelligence model or tool.
Printed by Galya Basol Kochav on 12/28/2025 10:24:40 AM. Copyright © 2025 National Comprehensive Cancer Network, Inc. All Rights Reserved.

base chordomas. Am J Clin Oncol 2012. Available at: http://www.ncbi.nlm.nih.gov/pubmed/22772429.

208. Meng T, Jin J, Jiang C, et al. Molecular Targeted Therapy in the Treatment of Chordoma: A Systematic Review. Front Oncol 2019;9:30. Available at: https://www.ncbi.nlm.nih.gov/pubmed/30775316.

209. Tamborini E, Miselli F, Negri T, et al. Molecular and biochemical analyses of platelet-derived growth factor receptor (PDGFR) B, PDGFRA, and KIT receptors in chordomas. Clin Cancer Res 2006;12:6920–6928. Available at: https://www.ncbi.nlm.nih.gov/pubmed/17145809.

210. Tamborini E, Virdis E, Negri T, et al. Analysis of receptor tyrosine kinases (RTKs) and downstream pathways in chordomas. Neuro Oncol 2010;12:776–789. Available at: https://www.ncbi.nlm.nih.gov/pubmed/20164240.

211. Barber SM, Sadrameli SS, Lee JJ, et al. Chordoma-Current Understanding and Modern Treatment Paradigms. J Clin Med 2021;10. Available at: https://www.ncbi.nlm.nih.gov/pubmed/33806339.

212. Stacchiotti S, Longhi A, Ferraresi V, et al. Phase II study of imatinib in advanced chordoma. J Clin Oncol 2012;30:914–920. Available at: https://www.ncbi.nlm.nih.gov/pubmed/22331945.

213. Casali PG, Stacchiotti S, Grosso F, et al. Adding cisplatin (CDDP) to imatinib (IM) re-establishes tumor response following secondary resistance to IM in advanced chordoma [abstract]. J Clin Oncol 2007;25:Abstract 10038. Available at: http://ascopubs.org/doi/abs/10.1200/jco.2007.25.18_suppl.10038.

214. Stacchiotti S, Marrari A, Tamborini E, et al. Response to imatinib plus sirolimus in advanced chordoma. Ann Oncol 2009;20:1886–1894. Available at: https://www.ncbi.nlm.nih.gov/pubmed/19570961.

215. Hindi N, Casali PG, Morosi C, et al. Imatinib in advanced chordoma: A retrospective case series analysis. Eur J Cancer 2015;51:2609–2614. Available at: https://www.ncbi.nlm.nih.gov/pubmed/26283036.

216. Singhal N, Kotasek D, Parnis FX. Response to erlotinib in a patient with treatment refractory chordoma. Anticancer Drugs 2009;20:953–955. Available at: https://www.ncbi.nlm.nih.gov/pubmed/19730087.

217. Launay SG, Chetaille B, Medina F, et al. Efficacy of epidermal growth factor receptor targeting in advanced chordoma: case report and literature review. BMC Cancer 2011;11:423. Available at: https://www.ncbi.nlm.nih.gov/pubmed/21970335.

218. Stacchiotti S, Tamborini E, Lo Vullo S, et al. Phase II study on lapatinib in advanced EGFR-positive chordoma. Ann Oncol 2013;24:1931–1936. Available at: https://www.ncbi.nlm.nih.gov/pubmed/23559153.

219. Bompas E, Le Cesne A, Tresch-Bruneel E, et al. Sorafenib in patients with locally advanced and metastatic chordomas: a phase II trial of the French Sarcoma Group (GSF/GETO). Ann Oncol 2015;26:2168–2173. Available at: https://www.ncbi.nlm.nih.gov/pubmed/26202596.

220. Lebellec L, Bertucci F, Tresch-Bruneel E, et al. Circulating vascular endothelial growth factor (VEGF) as predictive factor of progression-free survival in patients with advanced chordoma receiving sorafenib: an analysis from a phase II trial of the french sarcoma group (GSF/GETO). Oncotarget 2016;7:73984–73994. Available at: https://www.ncbi.nlm.nih.gov/pubmed/27659533.

221. George S, Merriam P, Maki RG, et al. Multicenter phase II trial of sunitinib in the treatment of nongastrointestinal stromal tumor sarcomas. J Clin Oncol 2009;27:3154–3160. Available at: https://www.ncbi.nlm.nih.gov/pubmed/19451429.

222. Blay JY, Chevret S, Le Cesne A, et al. Pembrolizumab in patients with rare and ultra-rare sarcomas (AcSe Pembrolizumab): analysis of a subgroup from a non-randomised, open-label, phase 2, basket trial. Lancet Oncol 2023;24:892–902. Available at: https://www.ncbi.nlm.nih.gov/pubmed/37429302.

223. Thieblemont C, Biron P, Rocher F, et al. Prognostic factors in chordoma: role of postoperative radiotherapy. Eur J Cancer

Version 2.2026 © 2025 National Comprehensive Cancer Network© (NCCN©), All rights reserved. NCCN Guidelines® and this illustration may not be reproduced in any form without the express written permission of NCCN.

PLEASE NOTE that use of this NCCN Content is governed by the End-User License Agreement, and you MAY NOT distribute this Content or use it with any artificial intelligence model or tool.
Printed by Galya Basol Kochav on 12/28/2025 10:24:40 AM. Copyright © 2025 National Comprehensive Cancer Network, Inc. All Rights Reserved.

1995;31A:2255–2259. Available at: https://www.ncbi.nlm.nih.gov/pubmed/8652252.

224. Boriani S, Saravanja D, Yamada Y, et al. Challenges of local recurrence and cure in low grade malignant tumors of the spine. Spine (Phila Pa 1976) 2009;34:S48–57. Available at: https://www.ncbi.nlm.nih.gov/pubmed/19829277.

225. Chambers PW, Schwinn CP. Chordoma. A clinicopathologic study of metastasis. Am J Clin Pathol 1979;72:765–776. Available at: https://www.ncbi.nlm.nih.gov/pubmed/389031.

226. McPherson CM, Suki D, McCutcheon IE, et al. Metastatic disease from spinal chordoma: a 10-year experience. J Neurosurg Spine 2006;5:277–280. Available at: https://www.ncbi.nlm.nih.gov/pubmed/17048762.

227. Kerekes D, Goodwin CR, Ahmed AK, et al. Local and distant recurrence in resected sacral chordomas: a systematic review and pooled cohort analysis. Global Spine J 2019;9:191–201. Available at: https://www.ncbi.nlm.nih.gov/pubmed/30984500.

228. Ailon T, Torabi R, Fisher CG, et al. Management of locally recurrent chordoma of the mobile spine and sacrum: a systematic review. Spine (Phila Pa 1976) 2016;41 Suppl 20:S193–S198. Available at: https://www.ncbi.nlm.nih.gov/pubmed/27753782.

229. Shing DC, McMullan DJ, Roberts P, et al. FUS/ERG gene fusions in Ewing's tumors. Cancer Res 2003;63:4568–4576. Available at: https://www.ncbi.nlm.nih.gov/pubmed/12907633.

230. Ng TL, O'Sullivan MJ, Pallen CJ, et al. Ewing sarcoma with novel translocation t(2;16) producing an in-frame fusion of FUS and FEV. J Mol Diagn 2007;9:459–463. Available at: https://www.ncbi.nlm.nih.gov/pubmed/17620387.

231. Ambros IM, Ambros PF, Strehl S, et al. MIC2 is a specific marker for Ewing's sarcoma and peripheral primitive neuroectodermal tumors. Evidence for a common histogenesis of Ewing's sarcoma and peripheral primitive neuroectodermal tumors from MIC2 expression and specific chromosome aberration. Cancer 1991;67:1886–1893. Available at: https://www.ncbi.nlm.nih.gov/pubmed/1848471.

232. Perlman EJ, Dickman PS, Askin FB, et al. Ewing's sarcoma--routine diagnostic utilization of MIC2 analysis: a Pediatric Oncology Group/Children's Cancer Group Intergroup Study. Hum Pathol 1994;25:304–307. Available at: https://www.ncbi.nlm.nih.gov/pubmed/8150461.

233. Olsen SH, Thomas DG, Lucas DR. Cluster analysis of immunohistochemical profiles in synovial sarcoma, malignant peripheral nerve sheath tumor, and Ewing sarcoma. Mod Pathol 2006;19:659–668. Available at: https://www.ncbi.nlm.nih.gov/pubmed/16528378.

234. Machado I, Navarro S, Llombart-Bosch A. Ewing sarcoma and the new emerging Ewing-like sarcomas: (CIC and BCOR-rearranged-sarcomas). A systematic review. Histol Histopathol 2016;31:1169–1181. Available at: https://www.ncbi.nlm.nih.gov/pubmed/27306060.

235. Sbaraglia M, Righi A, Gambarotti M, Dei Tos AP. Ewing sarcoma and Ewing-like tumors. Virchows Arch 2020;476:109–119. Available at: https://www.ncbi.nlm.nih.gov/pubmed/31802230.

236. Riggi N, Suva ML, Stamenkovic I. Ewing's Sarcoma. N Engl J Med 2021;384:154–164. Available at: https://www.ncbi.nlm.nih.gov/pubmed/33497548.

237. Glaubiger DL, Makuch R, Schwarz J, et al. Determination of prognostic factors and their influence on therapeutic results in patients with Ewing's sarcoma. Cancer 1980;45:2213–2219. Available at: http://www.ncbi.nlm.nih.gov/pubmed/7370962.

238. Gobel V, Jurgens H, Etspuler G, et al. Prognostic significance of tumor volume in localized Ewing's sarcoma of bone in children and adolescents. J Cancer Res Clin Oncol 1987;113:187–191. Available at: https://www.ncbi.nlm.nih.gov/pubmed/3558454.

Version 2.2026 © 2025 National Comprehensive Cancer Network© (NCCN©), All rights reserved. NCCN Guidelines® and this illustration may not be reproduced in any form without the express written permission of NCCN.

PLEASE NOTE that use of this NCCN Content is governed by the End-User License Agreement, and you MAY NOT distribute this Content or use it with any artificial intelligence model or tool.
Printed by Galya Basol Kochav on 12/28/2025 10:24:40 AM. Copyright © 2025 National Comprehensive Cancer Network, Inc. All Rights Reserved.

239. Ahrens S, Hoffmann C, Jabar S, et al. Evaluation of prognostic factors in a tumor volume-adapted treatment strategy for localized Ewing sarcoma of bone: the CESS 86 experience. Cooperative Ewing Sarcoma Study. Med Pediatr Oncol 1999;32:186–195. Available at: https://www.ncbi.nlm.nih.gov/pubmed/10064186.

240. Bacci G, Longhi A, Ferrari S, et al. Prognostic factors in non-metastatic Ewing's sarcoma tumor of bone: an analysis of 579 patients treated at a single institution with adjuvant or neoadjuvant chemotherapy between 1972 and 1998. Acta Oncol 2006;45:469–475. Available at: https://www.ncbi.nlm.nih.gov/pubmed/16760184.

241. Rodriguez-Galindo C, Liu T, Krasin MJ, et al. Analysis of prognostic factors in ewing sarcoma family of tumors: review of St. Jude Children's Research Hospital studies. Cancer 2007;110:375–384. Available at: https://www.ncbi.nlm.nih.gov/pubmed/17569105.

242. Serlo J, Helenius I, Vettenranta K, et al. Surgically treated patients with axial and peripheral Ewing's sarcoma family of tumours: A population based study in Finland during 1990-2009. Eur J Surg Oncol 2015;41:893–898. Available at: https://www.ncbi.nlm.nih.gov/pubmed/25817983.

243. Grevener K, Haveman LM, Ranft A, et al. Management and outcome of Ewing sarcoma of the head and neck. Pediatr Blood Cancer 2016;63:604–610. Available at: https://www.ncbi.nlm.nih.gov/pubmed/26702872.

244. Survival Rates for Ewing Tumors. cancer.org: 2023. Available at: https://www.cancer.org/cancer/types/ewing-tumor/detection-diagnosis-staging/survival-rates.html. Accessed September 12, 2024.

245. Bacci G, Boriani S, Balladelli A, et al. Treatment of nonmetastatic Ewing's sarcoma family tumors of the spine and sacrum: the experience from a single institution. Eur Spine J 2009;18:1091–1095. Available at: https://www.ncbi.nlm.nih.gov/pubmed/19277725.

246. Bosma SE, Ayu O, Fiocco M, et al. Prognostic factors for survival in Ewing sarcoma: A systematic review. Surg Oncol 2018;27:603–610. Available at: https://www.ncbi.nlm.nih.gov/pubmed/30449479.

247. Cangir A, Vietti TJ, Gehan EA, et al. Ewing's sarcoma metastatic at diagnosis. Results and comparisons of two intergroup Ewing's sarcoma studies. Cancer 1990;66:887–893. Available at: http://www.ncbi.nlm.nih.gov/pubmed/2201433.

248. Dang A, Feng X, Hamm J, et al. Survival outcomes in metastatic Ewing sarcoma treated With whole-lung radiation. Cureus 2022;14:e26750. Available at: https://www.ncbi.nlm.nih.gov/pubmed/35967186.

249. Paulino AC, Mai WY, Teh BS. Radiotherapy in metastatic ewing sarcoma. Am J Clin Oncol 2013;36:283–286. Available at: https://www.ncbi.nlm.nih.gov/pubmed/22547005.

250. Oberlin O, Deley MC, Bui BN, et al. Prognostic factors in localized Ewing's tumours and peripheral neuroectodermal tumours: the third study of the French Society of Paediatric Oncology (EW88 study). Br J Cancer 2001;85:1646–1654. Available at: https://www.ncbi.nlm.nih.gov/pubmed/11742482.

251. Paulussen M, Ahrens S, Dunst J, et al. Localized Ewing tumor of bone: final results of the cooperative Ewing's Sarcoma Study CESS 86. J Clin Oncol 2001;19:1818–1829. Available at: https://www.ncbi.nlm.nih.gov/pubmed/11251014.

252. Pan HY, Morani A, Wang WL, et al. Prognostic factors and patterns of relapse in ewing sarcoma patients treated with chemotherapy and r0 resection. Int J Radiat Oncol Biol Phys 2015;92:349–357. Available at: https://www.ncbi.nlm.nih.gov/pubmed/25772182.

253. Kissane JM, Askin FB, Foulkes M, et al. Ewing's sarcoma of bone: clinicopathologic aspects of 303 cases from the Intergroup Ewing's Sarcoma Study. Hum Pathol 1983;14:773–779. Available at: https://www.ncbi.nlm.nih.gov/pubmed/6885037.

254. Gupta AA, Pappo A, Saunders N, et al. Clinical outcome of children and adults with localized Ewing sarcoma: impact of chemotherapy dose and timing of local therapy. Cancer 2010;116:3189–3194. Available at: https://www.ncbi.nlm.nih.gov/pubmed/20564643.

Version 2.2026 © 2025 National Comprehensive Cancer Network© (NCCN©), All rights reserved. NCCN Guidelines® and this illustration may not be reproduced in any form without the express written permission of NCCN.

PLEASE NOTE that use of this NCCN Content is governed by the End-User License Agreement, and you MAY NOT distribute this Content or use it with any artificial intelligence model or tool.
Printed by Galya Basol Kochav on 12/28/2025 10:24:40 AM. Copyright © 2025 National Comprehensive Cancer Network, Inc. All Rights Reserved.

255. Lee J, Hoang BH, Ziogas A, Zell JA. Analysis of prognostic factors in Ewing sarcoma using a population-based cancer registry. Cancer 2010;116:1964–1973. Available at: https://www.ncbi.nlm.nih.gov/pubmed/20151425.

256. Treglia G, Salsano M, Stefanelli A, et al. Diagnostic accuracy of (1)(8)F-FDG-PET and PET/CT in patients with Ewing sarcoma family tumours: a systematic review and a meta-analysis. Skeletal Radiol 2012;41:249–256. Available at: https://www.ncbi.nlm.nih.gov/pubmed/22072239.

257. Campbell KM, Shulman DS, Grier HE, DuBois SG. Role of bone marrow biopsy for staging new patients with Ewing sarcoma: A systematic review. Pediatr Blood Cancer 2021;68:e28807. Available at: https://www.ncbi.nlm.nih.gov/pubmed/33219750.

258. Siegel MJ, Acharyya S, Hoffer FA, et al. Whole-body MR imaging for staging of malignant tumors in pediatric patients: results of the American College of Radiology Imaging Network 6660 Trial. Radiology 2013;266:599–609. Available at: https://www.ncbi.nlm.nih.gov/pubmed/23264347.

259. Boddu S, Walko CM, Bienasz S, et al. Clinical utility of genomic profiling in the treatment of advanced sarcomas: a single-center experience. JCO Precis Oncol 2018;2:1–8. Available at: https://www.ncbi.nlm.nih.gov/pubmed/35135155.

260. Laetsch TW, Roy A, Xu L, et al. Undifferentiated sarcomas in children harbor clinically relevant oncogenic fusions and gene copy-number alterations: a report from the Children's Oncology Group. Clin Cancer Res 2018;24:3888–3897. Available at: https://www.ncbi.nlm.nih.gov/pubmed/29691299.

261. Avigad S, Cohen IJ, Zilberstein J, et al. The predictive potential of molecular detection in the nonmetastatic Ewing family of tumors. Cancer 2004;100:1053–1058. Available at: https://www.ncbi.nlm.nih.gov/pubmed/14983502.

262. de Alava E, Kawai A, Healey JH, et al. EWS-FLI1 fusion transcript structure is an independent determinant of prognosis in Ewing's sarcoma. J Clin Oncol 1998;16:1248–1255. Available at: https://www.ncbi.nlm.nih.gov/pubmed/9552022.

263. Zoubek A, Dockhorn-Dworniczak B, Delattre O, et al. Does expression of different EWS chimeric transcripts define clinically distinct risk groups of Ewing tumor patients? J Clin Oncol 1996;14:1245–1251. Available at: http://www.ncbi.nlm.nih.gov/pubmed/8648380.

264. Le Deley MC, Delattre O, Schaefer KL, et al. Impact of EWS-ETS fusion type on disease progression in Ewing's sarcoma/peripheral primitive neuroectodermal tumor: prospective results from the cooperative Euro-E.W.I.N.G. 99 trial. J Clin Oncol 2010;28:1982–1988. Available at: https://www.ncbi.nlm.nih.gov/pubmed/20308673.

265. van Doorninck JA, Ji L, Schaub B, et al. Current treatment protocols have eliminated the prognostic advantage of type 1 fusions in Ewing sarcoma: a report from the Children's Oncology Group. J Clin Oncol 2010;28:1989–1994. Available at: http://www.ncbi.nlm.nih.gov/pubmed/20308669.

266. Burgert EO, Jr., Nesbit ME, Garnsey LA, et al. Multimodal therapy for the management of nonpelvic, localized Ewing's sarcoma of bone: intergroup study IESS-II. J Clin Oncol 1990;8:1514–1524. Available at: https://www.ncbi.nlm.nih.gov/pubmed/2099751.

267. Nesbit ME, Jr., Gehan EA, Burgert EO, Jr., et al. Multimodal therapy for the management of primary, nonmetastatic Ewing's sarcoma of bone: a long-term follow-up of the First Intergroup study. J Clin Oncol 1990;8:1664–1674. Available at: https://www.ncbi.nlm.nih.gov/pubmed/2213103.

268. Grier HE, Krailo MD, Tarbell NJ, et al. Addition of ifosfamide and etoposide to standard chemotherapy for Ewing's sarcoma and primitive neuroectodermal tumor of bone. N Engl J Med 2003;348:694–701. Available at: https://www.ncbi.nlm.nih.gov/pubmed/12594313.

Version 2.2026 © 2025 National Comprehensive Cancer Network© (NCCN©), All rights reserved. NCCN Guidelines® and this illustration may not be reproduced in any form without the express written permission of NCCN.

PLEASE NOTE that use of this NCCN Content is governed by the End-User License Agreement, and you MAY NOT distribute this Content or use it with any artificial intelligence model or tool.
Printed by Galya Basol Kochav on 12/28/2025 10:24:40 AM. Copyright © 2025 National Comprehensive Cancer Network, Inc. All Rights Reserved.

269. Shamberger RC, LaQuaglia MP, Gebhardt MC, et al. Ewing sarcoma/primitive neuroectodermal tumor of the chest wall: impact of initial versus delayed resection on tumor margins, survival, and use of radiation therapy. Ann Surg 2003;238:563–567; discussion 567–568. Available at: https://www.ncbi.nlm.nih.gov/pubmed/14530727.

270. Krasin MJ, Davidoff AM, Rodriguez-Galindo C, et al. Definitive surgery and multiagent systemic therapy for patients with localized Ewing sarcoma family of tumors: local outcome and prognostic factors. Cancer 2005;104:367–373. Available at: https://www.ncbi.nlm.nih.gov/pubmed/15948159.

271. Wexler LH, DeLaney TF, Tsokos M, et al. Ifosfamide and etoposide plus vincristine, doxorubicin, and cyclophosphamide for newly diagnosed Ewing's sarcoma family of tumors. Cancer 1996;78:901–911. Available at: https://www.ncbi.nlm.nih.gov/pubmed/8756388.

272. Rosito P, Mancini AF, Rondelli R, et al. Italian Cooperative Study for the treatment of children and young adults with localized Ewing sarcoma of bone: a preliminary report of 6 years of experience. Cancer 1999;86:421–428. Available at: https://www.ncbi.nlm.nih.gov/pubmed/10430250.

273. Kolb EA, Kushner BH, Gorlick R, et al. Long-term event-free survival after intensive chemotherapy for Ewing's family of tumors in children and young adults. J Clin Oncol 2003;21:3423–3430. Available at: https://www.ncbi.nlm.nih.gov/pubmed/12972518.

274. Oberlin O, Habrand JL, Zucker JM, et al. No benefit of ifosfamide in Ewing's sarcoma: a nonrandomized study of the French Society of Pediatric Oncology. J Clin Oncol 1992;10:1407–1412. Available at: https://www.ncbi.nlm.nih.gov/pubmed/1517783.

275. Bacci G, Picci P, Ferrari S, et al. Neoadjuvant chemotherapy for Ewing's sarcoma of bone: no benefit observed after adding ifosfamide and etoposide to vincristine, actinomycin, cyclophosphamide, and doxorubicin in the maintenance phase--results of two sequential studies. Cancer 1998;82:1174–1183. Available at: http://www.ncbi.nlm.nih.gov/pubmed/9506366.

276. Yock TI, Krailo M, Fryer CJ, et al. Local control in pelvic Ewing sarcoma: analysis from INT-0091--a report from the Children's Oncology Group. J Clin Oncol 2006;24:3838–3843. Available at: https://www.ncbi.nlm.nih.gov/pubmed/16921035.

277. Granowetter L, Womer R, Devidas M, et al. Dose-intensified compared with standard chemotherapy for nonmetastatic Ewing sarcoma family of tumors: a Children's Oncology Group Study. J Clin Oncol 2009;27:2536–2541. Available at: https://www.ncbi.nlm.nih.gov/pubmed/19349548.

278. Womer RB, West DC, Krailo MD, et al. Randomized controlled trial of interval-compressed chemotherapy for the treatment of localized Ewing sarcoma: a report from the Children's Oncology Group. J Clin Oncol 2012;30:4148–4154. Available at: https://www.ncbi.nlm.nih.gov/pubmed/23091096.

279. Brennan B, Kirton L, Marec-Berard P, et al. Comparison of two chemotherapy regimens in patients with newly diagnosed Ewing sarcoma (EE2012): an open-label, randomised, phase 3 trial. Lancet 2022;400:1513–1521. Available at: https://www.ncbi.nlm.nih.gov/pubmed/36522207.

280. Miser JS, Krailo MD, Tarbell NJ, et al. Treatment of metastatic Ewing's sarcoma or primitive neuroectodermal tumor of bone: evaluation of combination ifosfamide and etoposide--a Children's Cancer Group and Pediatric Oncology Group study. J Clin Oncol 2004;22:2873–2876. Available at: https://www.ncbi.nlm.nih.gov/pubmed/15254055.

281. Paulussen M, Craft AW, Lewis I, et al. Results of the EICESS-92 Study: two randomized trials of Ewing's sarcoma treatment--cyclophosphamide compared with ifosfamide in standard-risk patients and assessment of benefit of etoposide added to standard treatment in high-risk patients. J Clin Oncol 2008;26:4385–4393. Available at: https://www.ncbi.nlm.nih.gov/pubmed/18802150.

282. Le Deley MC, Paulussen M, Lewis I, et al. Cyclophosphamide compared with ifosfamide in consolidation treatment of standard-risk Ewing sarcoma: results of the randomized noninferiority Euro-EWING99-

Version 2.2026 © 2025 National Comprehensive Cancer Network© (NCCN©), All rights reserved. NCCN Guidelines® and this illustration may not be reproduced in any form without the express written permission of NCCN.

PLEASE NOTE that use of this NCCN Content is governed by the End-User License Agreement, and you MAY NOT distribute this Content or use it with any artificial intelligence model or tool.
Printed by Galya Basol Kochav on 12/28/2025 10:24:40 AM. Copyright © 2025 National Comprehensive Cancer Network, Inc. All Rights Reserved.

R1 trial. J Clin Oncol 2014;32:2440–2448. Available at: https://www.ncbi.nlm.nih.gov/pubmed/24982464.

283. Ferrari S, Sundby Hall K, Luksch R, et al. Nonmetastatic Ewing family tumors: high-dose chemotherapy with stem cell rescue in poor responder patients. Results of the Italian Sarcoma Group/Scandinavian Sarcoma Group III protocol. Ann Oncol 2011;22:1221–1227. Available at: https://www.ncbi.nlm.nih.gov/pubmed/21059639.

284. Gaspar N, Rey A, Berard PM, et al. Risk adapted chemotherapy for localised Ewing's sarcoma of bone: the French EW93 study. Eur J Cancer 2012;48:1376–1385. Available at: https://www.ncbi.nlm.nih.gov/pubmed/22516209.

285. Kushner BH, Meyers PA. How effective is dose-intensive/myeloablative therapy against Ewing's sarcoma/primitive neuroectodermal tumor metastatic to bone or bone marrow? The Memorial Sloan-Kettering experience and a literature review. J Clin Oncol 2001;19:870–880. Available at: http://www.ncbi.nlm.nih.gov/pubmed/11157041.

286. Juergens C, Weston C, Lewis I, et al. Safety assessment of intensive induction with vincristine, ifosfamide, doxorubicin, and etoposide (VIDE) in the treatment of Ewing tumors in the EURO-E.W.I.N.G. 99 clinical trial. Pediatr Blood Cancer 2006;47:22–29. Available at: https://www.ncbi.nlm.nih.gov/pubmed/16572419.

287. Oberlin O, Rey A, Desfachelles AS, et al. Impact of high-dose busulfan plus melphalan as consolidation in metastatic Ewing tumors: a study by the Societe Francaise des Cancers de l'Enfant. J Clin Oncol 2006;24:3997–4002. Available at: http://www.ncbi.nlm.nih.gov/pubmed/16921053.

288. Rosenthal J, Bolotin E, Shakhnovits M, et al. High-dose therapy with hematopoietic stem cell rescue in patients with poor prognosis Ewing family tumors. Bone Marrow Transplant 2008;42:311–318. Available at: https://www.ncbi.nlm.nih.gov/pubmed/18587438.

289. Burdach S, Thiel U, Schoniger M, et al. Total body MRI-governed involved compartment irradiation combined with high-dose chemotherapy and stem cell rescue improves long-term survival in Ewing tumor patients with multiple primary bone metastases. Bone Marrow Transplant 2010;45:483–489. Available at: https://www.ncbi.nlm.nih.gov/pubmed/19684633.

290. Ladenstein R, Potschger U, Le Deley MC, et al. Primary disseminated multifocal Ewing sarcoma: results of the Euro-EWING 99 trial. J Clin Oncol 2010;28:3284–3291. Available at: https://www.ncbi.nlm.nih.gov/pubmed/20547982.

291. Whelan J, Le Deley MC, Dirksen U, et al. High-dose chemotherapy and blood autologous stem-cell rescue compared with standard chemotherapy in localized high-risk Ewing sarcoma: results of Euro-E.W.I.N.G.99 and Ewing-2008. J Clin Oncol 2018;36:JCO2018782516. Available at: https://www.ncbi.nlm.nih.gov/pubmed/30188789.

292. Dunst J, Jurgens H, Sauer R, et al. Radiation therapy in Ewing's sarcoma: an update of the CESS 86 trial. Int J Radiat Oncol Biol Phys 1995;32:919–930. Available at: https://www.ncbi.nlm.nih.gov/pubmed/7607966.

293. Schuck A, Ahrens S, Paulussen M, et al. Local therapy in localized Ewing tumors: results of 1058 patients treated in the CESS 81, CESS 86, and EICESS 92 trials. Int J Radiat Oncol Biol Phys 2003;55:168–177. Available at: https://www.ncbi.nlm.nih.gov/pubmed/12504050.

294. DuBois SG, Krailo MD, Gebhardt MC, et al. Comparative evaluation of local control strategies in localized Ewing sarcoma of bone: a report from the Children's Oncology Group. Cancer 2015;121:467–475. Available at: https://www.ncbi.nlm.nih.gov/pubmed/25251206.

295. Ahmed SK, Witten BG, Harmsen WS, et al. Analysis of local control outcomes and clinical prognostic factors in localized pelvic Ewing sarcoma patients treated with radiation therapy: a report from the Children's Oncology Group. Int J Radiat Oncol Biol Phys 2023;115:337–346. Available at: https://www.ncbi.nlm.nih.gov/pubmed/36302496.

Version 2.2026 © 2025 National Comprehensive Cancer Network© (NCCN©), All rights reserved. NCCN Guidelines® and this illustration may not be reproduced in any form without the express written permission of NCCN.

PLEASE NOTE that use of this NCCN Content is governed by the End-User License Agreement, and you MAY NOT distribute this Content or use it with any artificial intelligence model or tool.
Printed by Galya Basol Kochav on 12/28/2025 10:24:40 AM. Copyright © 2025 National Comprehensive Cancer Network, Inc. All Rights Reserved.

296. Schuck A, Ahrens S, von Schorlemer I, et al. Radiotherapy in Ewing tumors of the vertebrae: treatment results and local relapse analysis of the CESS 81/86 and EICESS 92 trials. Int J Radiat Oncol Biol Phys 2005;63:1562–1567. Available at: https://www.ncbi.nlm.nih.gov/pubmed/16137838.

297. Indelicato DJ, Keole SR, Shahlaee AH, et al. Definitive radiotherapy for ewing tumors of extremities and pelvis: long-term disease control, limb function, and treatment toxicity. Int J Radiat Oncol Biol Phys 2008;72:871–877. Available at: https://www.ncbi.nlm.nih.gov/pubmed/18455323.

298. Krasin MJ, Rodriguez-Galindo C, Billups CA, et al. Definitive irradiation in multidisciplinary management of localized Ewing sarcoma family of tumors in pediatric patients: outcome and prognostic factors. Int J Radiat Oncol Biol Phys 2004;60:830–838. Available at: https://www.ncbi.nlm.nih.gov/pubmed/15465200.

299. Paulino AC, Nguyen TX, Mai WY, et al. Dose response and local control using radiotherapy in non-metastatic Ewing sarcoma. Pediatr Blood Cancer 2007;49:145–148. Available at: https://www.ncbi.nlm.nih.gov/pubmed/16732580.

300. Haeusler J, Ranft A, Boelling T, et al. The value of local treatment in patients with primary, disseminated, multifocal Ewing sarcoma (PDMES). Cancer 2010;116:443–450. Available at: https://www.ncbi.nlm.nih.gov/pubmed/19924786.

301. Paulussen M, Ahrens S, Burdach S, et al. Primary metastatic (stage IV) Ewing tumor: survival analysis of 171 patients from the EICESS studies. European Intergroup Cooperative Ewing Sarcoma Studies. Ann Oncol 1998;9:275–281. Available at: https://www.ncbi.nlm.nih.gov/pubmed/9602261.

302. Casey DL, Wexler LH, Meyers PA, et al. Radiation for bone metastases in Ewing sarcoma and rhabdomyosarcoma. Pediatr Blood Cancer 2015;62:445–449. Available at: https://www.ncbi.nlm.nih.gov/pubmed/25346208.

303. Bedetti B, Wiebe K, Ranft A, et al. Local control in Ewing sarcoma of the chest wall: results of the EURO-EWING 99 trial. Ann Surg Oncol 2015;22:2853–2859. Available at: https://www.ncbi.nlm.nih.gov/pubmed/26104542.

304. Denbo JW, Shannon Orr W, Wu Y, et al. Timing of surgery and the role of adjuvant radiotherapy in ewing sarcoma of the chest wall: a single-institution experience. Ann Surg Oncol 2012;19:3809–3815. Available at: https://www.ncbi.nlm.nih.gov/pubmed/22752372.

305. Baumann BC, Nagda SN, Kolker JD, et al. Efficacy and safety of stereotactic body radiation therapy for the treatment of pulmonary metastases from sarcoma: A potential alternative to resection. J Surg Oncol 2016;114:65–69. Available at: https://www.ncbi.nlm.nih.gov/pubmed/27111504.

306. Mehta N, Selch M, Wang PC, et al. Safety and efficacy of stereotactic body radiation therapy in the treatment of pulmonary metastases from high grade sarcoma. Sarcoma 2013;2013:360214. Available at: https://www.ncbi.nlm.nih.gov/pubmed/24198717.

307. Brown LC, Lester RA, Grams MP, et al. Stereotactic body radiotherapy for metastatic and recurrent ewing sarcoma and osteosarcoma. Sarcoma 2014;2014:418270. Available at: https://www.ncbi.nlm.nih.gov/pubmed/25548538.

308. Tanguturi SK, George S, Marcus KJ, et al. Whole lung irradiation in adults with metastatic Ewing sarcoma: practice patterns and implications for treatment. Sarcoma 2015;2015:591698. Available at: https://www.ncbi.nlm.nih.gov/pubmed/26199562.

309. Burgers JM, van Glabbeke M, Busson A, et al. Osteosarcoma of the limbs. Report of the EORTC-SIOP 03 trial 20781 investigating the value of adjuvant treatment with chemotherapy and/or prophylactic lung irradiation. Cancer 1988;61:1024–1031. Available at: https://www.ncbi.nlm.nih.gov/pubmed/3276390.

310. Ronchi L, Buwenge M, Cortesi A, et al. Whole lung irradiation in patients with osteosarcoma and Ewing sarcoma. Anticancer Res

Version 2.2026 © 2025 National Comprehensive Cancer Network© (NCCN©), All rights reserved. NCCN Guidelines® and this illustration may not be reproduced in any form without the express written permission of NCCN.

PLEASE NOTE that use of this NCCN Content is governed by the End-User License Agreement, and you MAY NOT distribute this Content or use it with any artificial intelligence model or tool.
Printed by Galya Basol Kochav on 12/28/2025 10:24:40 AM. Copyright © 2025 National Comprehensive Cancer Network, Inc. All Rights Reserved.

2018;38:4977–4985. Available at: https://www.ncbi.nlm.nih.gov/pubmed/30194141.

311. Bolling T, Schuck A, Paulussen M, et al. Whole lung irradiation in patients with exclusively pulmonary metastases of Ewing tumors. Toxicity analysis and treatment results of the EICESS-92 trial. Strahlenther Onkol 2008;184:193–197. Available at: https://www.ncbi.nlm.nih.gov/pubmed/18398583.

312. Bacci G, Forni C, Longhi A, et al. Long-term outcome for patients with non-metastatic Ewing's sarcoma treated with adjuvant and neoadjuvant chemotherapies. 402 patients treated at Rizzoli between 1972 and 1992. Eur J Cancer 2004;40:73–83. Available at: http://www.ncbi.nlm.nih.gov/pubmed/14687792.

313. Stahl M, Ranft A, Paulussen M, et al. Risk of recurrence and survival after relapse in patients with Ewing sarcoma. Pediatr Blood Cancer 2011;57:549–553. Available at: https://www.ncbi.nlm.nih.gov/pubmed/21442722.

314. Rodriguez-Galindo C, Billups CA, Kun LE, et al. Survival after recurrence of Ewing tumors: the St Jude Children's Research Hospital experience, 1979-1999. Cancer 2002;94:561–569. Available at: https://www.ncbi.nlm.nih.gov/pubmed/11900241.

315. Bacci G, Ferrari S, Longhi A, et al. Therapy and survival after recurrence of Ewing's tumors: the Rizzoli experience in 195 patients treated with adjuvant and neoadjuvant chemotherapy from 1979 to 1997. Ann Oncol 2003;14:1654–1659. Available at: https://www.ncbi.nlm.nih.gov/pubmed/14581274.

316. Leavey PJ, Mascarenhas L, Marina N, et al. Prognostic factors for patients with Ewing sarcoma (EWS) at first recurrence following multi-modality therapy: A report from the Children's Oncology Group. Pediatr Blood Cancer 2008;51:334–338. Available at: http://www.ncbi.nlm.nih.gov/pubmed/18506764.

317. Ferrari S, Luksch R, Hall KS, et al. Post-relapse survival in patients with Ewing sarcoma. Pediatr Blood Cancer 2015;62:994–999. Available at: https://www.ncbi.nlm.nih.gov/pubmed/25585917.

318. Robinson SI, Ahmed SK, Okuno SH, et al. Clinical outcomes of adult patients with relapsed Ewing sarcoma: a 30-year single-institution experience. Am J Clin Oncol 2014;37:585–591. Available at: https://www.ncbi.nlm.nih.gov/pubmed/23466580.

319. Van Mater D, Wagner L. Management of recurrent Ewing sarcoma: challenges and approaches. Onco Targets Ther 2019;12:2279–2288. Available at: https://www.ncbi.nlm.nih.gov/pubmed/30988632.

320. Bernstein ML, Devidas M, Lafreniere D, et al. Intensive therapy with growth factor support for patients with Ewing tumor metastatic at diagnosis: Pediatric Oncology Group/Children's Cancer Group Phase II Study 9457--a report from the Children's Oncology Group. J Clin Oncol 2006;24:152–159. Available at: https://www.ncbi.nlm.nih.gov/pubmed/16382125.

321. Hunold A, Weddeling N, Paulussen M, et al. Topotecan and cyclophosphamide in patients with refractory or relapsed Ewing tumors. Pediatr Blood Cancer 2006;47:795–800. Available at: https://www.ncbi.nlm.nih.gov/pubmed/16411206.

322. Kushner BH, Kramer K, Meyers PA, et al. Pilot study of topotecan and high-dose cyclophosphamide for resistant pediatric solid tumors. Med Pediatr Oncol 2000;35:468–474. Available at: https://www.ncbi.nlm.nih.gov/pubmed/11070479.

323. Saylors RL, 3rd, Stine KC, Sullivan J, et al. Cyclophosphamide plus topotecan in children with recurrent or refractory solid tumors: a Pediatric Oncology Group phase II study. J Clin Oncol 2001;19:3463–3469. Available at: https://www.ncbi.nlm.nih.gov/pubmed/11481351.

324. Casey DA, Wexler LH, Merchant MS, et al. Irinotecan and temozolomide for Ewing sarcoma: the Memorial Sloan-Kettering experience. Pediatr Blood Cancer 2009;53:1029–1034. Available at: https://www.ncbi.nlm.nih.gov/pubmed/19637327.

Version 2.2026 © 2025 National Comprehensive Cancer Network© (NCCN©), All rights reserved. NCCN Guidelines® and this illustration may not be reproduced in any form without the express written permission of NCCN.

PLEASE NOTE that use of this NCCN Content is governed by the End-User License Agreement, and you MAY NOT distribute this Content or use it with any artificial intelligence model or tool.
Printed by Galya Basol Kochav on 12/28/2025 10:24:40 AM. Copyright © 2025 National Comprehensive Cancer Network, Inc. All Rights Reserved.

325. Wagner LM, Crews KR, Iacono LC, et al. Phase I trial of temozolomide and protracted irinotecan in pediatric patients with refractory solid tumors. Clin Cancer Res 2004;10:840–848. Available at: https://www.ncbi.nlm.nih.gov/pubmed/14871959.

326. Wagner LM, McAllister N, Goldsby RE, et al. Temozolomide and intravenous irinotecan for treatment of advanced Ewing sarcoma. Pediatr Blood Cancer 2007;48:132–139. Available at: https://www.ncbi.nlm.nih.gov/pubmed/16317751.

327. Raciborska A, Bilska K, Drabko K, et al. Vincristine, irinotecan, and temozolomide in patients with relapsed and refractory Ewing sarcoma. Pediatr Blood Cancer 2013;60:1621–1625. Available at: https://www.ncbi.nlm.nih.gov/pubmed/23776128.

328. van Maldegem AM, Benson C, Rutkowski P, et al. Etoposide and carbo-or cisplatin combination therapy in refractory or relapsed Ewing sarcoma: a large retrospective study. Pediatr Blood Cancer 2015;62:40–44. Available at: https://www.ncbi.nlm.nih.gov/pubmed/25251256.

329. Burdach S, Jurgens H, Peters C, et al. Myeloablative radiochemotherapy and hematopoietic stem-cell rescue in poor-prognosis Ewing's sarcoma. J Clin Oncol 1993;11:1482–1488. Available at: https://www.ncbi.nlm.nih.gov/pubmed/8101562.

330. Barker LM, Pendergrass TW, Sanders JE, Hawkins DS. Survival after recurrence of Ewing's sarcoma family of tumors. J Clin Oncol 2005;23:4354–4362. Available at: https://www.ncbi.nlm.nih.gov/pubmed/15781881.

331. McTiernan A, Driver D, Michelagnoli MP, et al. High dose chemotherapy with bone marrow or peripheral stem cell rescue is an effective treatment option for patients with relapsed or progressive Ewing's sarcoma family of tumours. Ann Oncol 2006;17:1301–1305. Available at: http://www.ncbi.nlm.nih.gov/pubmed/16782749.

332. Italiano A, Mir O, Mathoulin-Pelissier S, et al. Cabozantinib in patients with advanced Ewing sarcoma or osteosarcoma (CABONE): a multicentre, single-arm, phase 2 trial. Lancet Oncol 2020;21:446–455. Available at: https://www.ncbi.nlm.nih.gov/pubmed/32078813.

333. Attia S, Bolejack V, Ganjoo KN, et al. A phase II trial of regorafenib in patients with advanced Ewing sarcoma and related tumors of soft tissue and bone: SARC024 trial results. Cancer Med 2023;12:1532–1539. Available at: https://www.ncbi.nlm.nih.gov/pubmed/35950293.

334. McCabe M, Kirton L, Khan M, et al. Phase III assessment of topotecan and cyclophosphamide and high-dose ifosfamide in rEECur: An international randomized controlled trial of chemotherapy for the treatment of recurrent and primary refractory Ewing sarcoma (RR-ES). Journal of Clinical Oncology 2022;40:LBA2–LBA2. Available at: https://ascopubs.org/doi/abs/10.1200/JCO.2022.40.17_suppl.LBA2.

335. Navid F, Willert JR, McCarville MB, et al. Combination of gemcitabine and docetaxel in the treatment of children and young adults with refractory bone sarcoma. Cancer 2008;113:419–425. Available at: https://www.ncbi.nlm.nih.gov/pubmed/18484657.

336. Van Winkle P, Angiolillo A, Krailo M, et al. Ifosfamide, carboplatin, and etoposide (ICE) reinduction chemotherapy in a large cohort of children and adolescents with recurrent/refractory sarcoma: the Children's Cancer Group (CCG) experience. Pediatr Blood Cancer 2005;44:338–347. Available at: https://www.ncbi.nlm.nih.gov/pubmed/15503297.

337. Subbiah V, Brana I, Longhi A, et al. Antitumor activity of lurbinectedin, a selective inhibitor of oncogene transcription, in patients with relapsed Ewing sarcoma: results of a basket phase II study. Clin Cancer Res 2022;28:2762–2770. Available at: https://www.ncbi.nlm.nih.gov/pubmed/35486638.

338. Xue R, Lewis VO, Moon BS, Lin PP. Local recurrence of Ewing sarcoma: is wide excision an acceptable treatment? J Surg Oncol 2019;120:746–752. Available at: https://www.ncbi.nlm.nih.gov/pubmed/31286523.

339. Dominkus M, Ruggieri P, Bertoni F, et al. Histologically verified lung metastases in benign giant cell tumours--14 cases from a single institution.

Version 2.2026 © 2025 National Comprehensive Cancer Network© (NCCN©), All rights reserved. NCCN Guidelines® and this illustration may not be reproduced in any form without the express written permission of NCCN.

PLEASE NOTE that use of this NCCN Content is governed by the End-User License Agreement, and you MAY NOT distribute this Content or use it with any artificial intelligence model or tool.
Printed by Galya Basol Kochav on 12/28/2025 10:24:40 AM. Copyright © 2025 National Comprehensive Cancer Network, Inc. All Rights Reserved.

Int Orthop 2006;30:499–504. Available at: https://www.ncbi.nlm.nih.gov/pubmed/16909252.

340. Viswanathan S, Jambhekar NA. Metastatic giant cell tumor of bone: are there associated factors and best treatment modalities? Clin Orthop Relat Res 2010;468:827–833. Available at: http://www.ncbi.nlm.nih.gov/pubmed/19597900.

341. van der Heijden L, Dijkstra PDS, Blay JY, Gelderblom H. Giant cell tumour of bone in the denosumab era. Eur J Cancer 2017;77:75–83. Available at: https://www.ncbi.nlm.nih.gov/pubmed/28365529.

342. Anract P, De Pinieux G, Cottias P, et al. Malignant giant-cell tumours of bone. Clinico-pathological types and prognosis: a review of 29 cases. Int Orthop 1998;22:19–26. Available at: https://www.ncbi.nlm.nih.gov/pubmed/9549577.

343. Bertoni F, Bacchini P, Staals EL. Malignancy in giant cell tumor of bone. Cancer 2003;97:2520–2529. Available at: https://www.ncbi.nlm.nih.gov/pubmed/12733152.

344. Purohit S, Pardiwala DN. Imaging of giant cell tumor of bone. Indian J Orthop 2007;41:91–96. Available at: https://www.ncbi.nlm.nih.gov/pubmed/21139758.

345. Thomas DM, Skubitz KM. Giant cell tumour of bone. Curr Opin Oncol 2009;21:338–344. Available at: https://www.ncbi.nlm.nih.gov/pubmed/19444102.

346. Werner M. Giant cell tumour of bone: morphological, biological and histogenetical aspects. Int Orthop 2006;30:484–489. Available at: https://www.ncbi.nlm.nih.gov/pubmed/17013643.

347. McDonald DJ, Sim FH, McLeod RA, Dahlin DC. Giant-cell tumor of bone. J Bone Joint Surg Am 1986;68:235–242. Available at: https://www.ncbi.nlm.nih.gov/pubmed/3511063.

348. Campanacci M, Baldini N, Boriani S, Sudanese A. Giant-cell tumor of bone. J Bone Joint Surg Am 1987;69:106–114. Available at: https://www.ncbi.nlm.nih.gov/pubmed/3805057.

349. Saiz P, Virkus W, Piasecki P, et al. Results of giant cell tumor of bone treated with intralesional excision. Clin Orthop Relat Res 2004:221–226. Available at: https://www.ncbi.nlm.nih.gov/pubmed/15241169.

350. Malek F, Krueger P, Hatmi ZN, et al. Local control of long bone giant cell tumour using curettage, burring and bone grafting without adjuvant therapy. Int Orthop 2006;30:495–498. Available at: https://www.ncbi.nlm.nih.gov/pubmed/16896875.

351. Kivioja AH, Blomqvist C, Hietaniemi K, et al. Cement is recommended in intralesional surgery of giant cell tumors: a Scandinavian Sarcoma Group study of 294 patients followed for a median time of 5 years. Acta Orthop 2008;79:86–93. Available at: https://www.ncbi.nlm.nih.gov/pubmed/18283578.

352. Errani C, Ruggieri P, Asenzio MA, et al. Giant cell tumor of the extremity: A review of 349 cases from a single institution. Cancer Treat Rev 2010;36:1–7. Available at: https://www.ncbi.nlm.nih.gov/pubmed/19879054.

353. Klenke FM, Wenger DE, Inwards CY, et al. Giant cell tumor of bone: risk factors for recurrence. Clin Orthop Relat Res 2011;469:591–599. Available at: https://www.ncbi.nlm.nih.gov/pubmed/20706812.

354. O'Donnell RJ, Springfield DS, Motwani HK, et al. Recurrence of giant-cell tumors of the long bones after curettage and packing with cement. J Bone Joint Surg Am 1994;76:1827–1833. Available at: https://www.ncbi.nlm.nih.gov/pubmed/7989388.

355. Blackley HR, Wunder JS, Davis AM, et al. Treatment of giant-cell tumors of long bones with curettage and bone-grafting. J Bone Joint Surg Am 1999;81:811–820. Available at: https://www.ncbi.nlm.nih.gov/pubmed/10391546.

Version 2.2026 © 2025 National Comprehensive Cancer Network© (NCCN©), All rights reserved. NCCN Guidelines® and this illustration may not be reproduced in any form without the express written permission of NCCN.

PLEASE NOTE that use of this NCCN Content is governed by the End-User License Agreement, and you MAY NOT distribute this Content or use it with any artificial intelligence model or tool.
Printed by Galya Basol Kochav on 12/28/2025 10:24:40 AM. Copyright © 2025 National Comprehensive Cancer Network, Inc. All Rights Reserved.

356. Prosser GH, Baloch KG, Tillman RM, et al. Does curettage without adjuvant therapy provide low recurrence rates in giant-cell tumors of bone? Clin Orthop Relat Res 2005:211–218. Available at: https://www.ncbi.nlm.nih.gov/pubmed/15930941.

357. Arbeitsgemeinschaft K, Becker WT, Dohle J, et al. Local recurrence of giant cell tumor of bone after intralesional treatment with and without adjuvant therapy. J Bone Joint Surg Am 2008;90:1060–1067. Available at: https://www.ncbi.nlm.nih.gov/pubmed/18451399.

358. Balke M, Schremper L, Gebert C, et al. Giant cell tumor of bone: treatment and outcome of 214 cases. J Cancer Res Clin Oncol 2008;134:969–978. Available at: https://www.ncbi.nlm.nih.gov/pubmed/18322700.

359. Pietschmann MF, Dietz RA, Utzschneider S, et al. The influence of adjuvants on local recurrence rate in giant cell tumour of the bone. Acta Chir Belg 2010;110:584–589. Available at: https://www.ncbi.nlm.nih.gov/pubmed/21337837.

360. Klenke FM, Wenger DE, Inwards CY, et al. Recurrent giant cell tumor of long bones: analysis of surgical management. Clin Orthop Relat Res 2011;469:1181–1187. Available at: https://www.ncbi.nlm.nih.gov/pubmed/20857250.

361. Trieb K, Bitzan P, Lang S, et al. Recurrence of curetted and bone-grafted giant-cell tumours with and without adjuvant phenol therapy. Eur J Surg Oncol 2001;27:200–202. Available at: https://www.ncbi.nlm.nih.gov/pubmed/11289759.

362. Turcotte RE, Wunder JS, Isler MH, et al. Giant cell tumor of long bone: a Canadian Sarcoma Group study. Clin Orthop Relat Res 2002:248–258. Available at: https://www.ncbi.nlm.nih.gov/pubmed/11953616.

363. Oda Y, Miura H, Tsuneyoshi M, Iwamoto Y. Giant cell tumor of bone: oncological and functional results of long-term follow-up. Jpn J Clin Oncol 1998;28:323–328. Available at: https://www.ncbi.nlm.nih.gov/pubmed/9703860.

364. Boons HW, Keijser LC, Schreuder HW, et al. Oncologic and functional results after treatment of giant cell tumors of bone. Arch Orthop Trauma Surg 2002;122:17–23. Available at: https://www.ncbi.nlm.nih.gov/pubmed/11995874.

365. Su YP, Chen WM, Chen TH. Giant-cell tumors of bone: an analysis of 87 cases. Int Orthop 2004;28:239–243. Available at: https://www.ncbi.nlm.nih.gov/pubmed/15160253.

366. Rastogi S, Prashanth I, Khan SA, et al. Giant cell tumor of bone: Is curettage the answer? Indian J Orthop 2007;41:109–114. Available at: https://www.ncbi.nlm.nih.gov/pubmed/21139761.

367. Guo W, Sun X, Zang J, Qu H. Intralesional excision versus wide resection for giant cell tumor involving the acetabulum: which is better? Clin Orthop Relat Res 2012;470:1213–1220. Available at: http://www.ncbi.nlm.nih.gov/pubmed/22125245.

368. Mavrogenis AF, Igoumenou VG, Megaloikonomos PD, et al. Giant cell tumor of bone revisited. SICOT J 2017;3:54. Available at: https://www.ncbi.nlm.nih.gov/pubmed/28905737.

369. Labs K, Perka C, Schmidt RG. Treatment of stages 2 and 3 giant-cell tumor. Arch Orthop Trauma Surg 2001;121:83–86. Available at: https://www.ncbi.nlm.nih.gov/pubmed/11195127.

370. Mankin HJ, Hornicek FJ. Treatment of giant cell tumors with allograft transplants: a 30-year study. Clin Orthop Relat Res 2005;439:144–150. Available at: https://www.ncbi.nlm.nih.gov/pubmed/16205153.

371. Mendenhall WM, Zlotecki RA, Scarborough MT, et al. Giant cell tumor of bone. Am J Clin Oncol 2006;29:96–99. Available at: https://www.ncbi.nlm.nih.gov/pubmed/16462511.

372. Saini R, Bali K, Bachhal V, et al. En bloc excision and autogenous fibular reconstruction for aggressive giant cell tumor of distal radius: a report of 12 cases and review of literature. J Orthop Surg Res 2011;6:14. Available at: https://www.ncbi.nlm.nih.gov/pubmed/21385393.

Version 2.2026 © 2025 National Comprehensive Cancer Network© (NCCN©), All rights reserved. NCCN Guidelines® and this illustration may not be reproduced in any form without the express written permission of NCCN.

PLEASE NOTE that use of this NCCN Content is governed by the End-User License Agreement, and you MAY NOT distribute this Content or use it with any artificial intelligence model or tool.
Printed by Galya Basol Kochav on 12/28/2025 10:24:40 AM. Copyright © 2025 National Comprehensive Cancer Network, Inc. All Rights Reserved.

373. Dahlin DC. Caldwell Lecture. Giant cell tumor of bone: highlights of 407 cases. AJR Am J Roentgenol 1985;144:955–960. Available at: https://www.ncbi.nlm.nih.gov/pubmed/3872579.

374. Schwartz LH, Okunieff PG, Rosenberg A, Suit HD. Radiation therapy in the treatment of difficult giant cell tumors. Int J Radiat Oncol Biol Phys 1989;17:1085–1088. Available at: https://www.ncbi.nlm.nih.gov/pubmed/2808042.

375. Bennett CJ, Jr., Marcus RB, Jr., Million RR, Enneking WF. Radiation therapy for giant cell tumor of bone. Int J Radiat Oncol Biol Phys 1993;26:299–304. Available at: https://www.ncbi.nlm.nih.gov/pubmed/8491687.

376. Malone S, O'Sullivan B, Catton C, et al. Long-term follow-up of efficacy and safety of megavoltage radiotherapy in high-risk giant cell tumors of bone. Int J Radiat Oncol Biol Phys 1995;33:689–694. Available at: https://www.ncbi.nlm.nih.gov/pubmed/7558960.

377. Chakravarti A, Spiro IJ, Hug EB, et al. Megavoltage radiation therapy for axial and inoperable giant-cell tumor of bone. J Bone Joint Surg Am 1999;81:1566–1573. Available at: https://www.ncbi.nlm.nih.gov/pubmed/10565648.

378. Nair MK, Jyothirmayi R. Radiation therapy in the treatment of giant cell tumor of bone. Int J Radiat Oncol Biol Phys 1999;43:1065–1069. Available at: https://www.ncbi.nlm.nih.gov/pubmed/10192357.

379. Miszczyk L, Wydmanski J, Spindel J. Efficacy of radiotherapy for giant cell tumor of bone: given either postoperatively or as sole treatment. Int J Radiat Oncol Biol Phys 2001;49:1239–1242. Available at: https://www.ncbi.nlm.nih.gov/pubmed/11286829.

380. Caudell JJ, Ballo MT, Zagars GK, et al. Radiotherapy in the management of giant cell tumor of bone. Int J Radiat Oncol Biol Phys 2003;57:158–165. Available at: https://www.ncbi.nlm.nih.gov/pubmed/12909228.

381. Feigenberg SJ, Marcus Jr RB, Zlotecki RA, et al. Radiation therapy for giant cell tumors of bone. Clin Orthop Relat Res 2003:207–216. Available at: https://www.ncbi.nlm.nih.gov/pubmed/12782877.

382. Ruka W, Rutkowski P, Morysinski T, et al. The megavoltage radiation therapy in treatment of patients with advanced or difficult giant cell tumors of bone. Int J Radiat Oncol Biol Phys 2010;78:494–498. Available at: https://www.ncbi.nlm.nih.gov/pubmed/20004531.

383. Bhatia S, Miszczyk L, Roelandts M, et al. Radiotherapy for marginally resected, unresectable or recurrent giant cell tumor of the bone: a rare cancer network study. Rare Tumors 2011;3:e48. Available at: https://www.ncbi.nlm.nih.gov/pubmed/22355503.

384. Ma Y, Xu W, Yin H, et al. Therapeutic radiotherapy for giant cell tumor of the spine: a systemic review. Eur Spine J 2015;24:1754–1760. Available at: https://www.ncbi.nlm.nih.gov/pubmed/25943724.

385. Hug EB, Muenter MW, Adams JA, et al. 3-D-conformal radiation therapy for pediatric giant cell tumors of the skull base. Strahlenther Onkol 2002;178:239–244. Available at: https://www.ncbi.nlm.nih.gov/pubmed/12082682.

386. Roeder F, Timke C, Zwicker F, et al. Intensity modulated radiotherapy (IMRT) in benign giant cell tumors--a single institution case series and a short review of the literature. Radiat Oncol 2010;5:18. Available at: https://www.ncbi.nlm.nih.gov/pubmed/20187955.

387. Palmerini E, Picci P, Reichardt P, Downey G. Malignancy in Giant Cell Tumor of Bone: A Review of the Literature. Technol Cancer Res Treat 2019;18:1533033819840000. Available at: https://www.ncbi.nlm.nih.gov/pubmed/30935298.

388. Musharbash FN, Edelstein A, El Abiad JM, et al. Risk of malignant transformation of giant cell tumors of bone is 8 times lower with megavoltage vs. orthovoltage radiation therapy. Sarcoma 2022;2022:7216296. Available at: https://www.ncbi.nlm.nih.gov/pubmed/36311815.

Version 2.2026 © 2025 National Comprehensive Cancer Network© (NCCN©), All rights reserved. NCCN Guidelines® and this illustration may not be reproduced in any form without the express written permission of NCCN.

PLEASE NOTE that use of this NCCN Content is governed by the End-User License Agreement, and you MAY NOT distribute this Content or use it with any artificial intelligence model or tool.
Printed by Galya Basol Kochav on 12/28/2025 10:24:40 AM. Copyright © 2025 National Comprehensive Cancer Network, Inc. All Rights Reserved.

389. Thomas D, Henshaw R, Skubitz K, et al. Denosumab in patients with giant-cell tumour of bone: an open-label, phase 2 study. Lancet Oncol 2010;11:275–280. Available at: https://www.ncbi.nlm.nih.gov/pubmed/20149736.

390. Branstetter DG, Nelson SD, Manivel JC, et al. Denosumab induces tumor reduction and bone formation in patients with giant-cell tumor of bone. Clin Cancer Res 2012;18:4415–4424. Available at: https://www.ncbi.nlm.nih.gov/pubmed/22711702.

391. Chawla S, Henshaw R, Seeger L, et al. Safety and efficacy of denosumab for adults and skeletally mature adolescents with giant cell tumour of bone: interim analysis of an open-label, parallel-group, phase 2 study. Lancet Oncol 2013;14:901–908. Available at: https://www.ncbi.nlm.nih.gov/pubmed/23867211.

392. Ueda T, Morioka H, Nishida Y, et al. Objective tumor response to denosumab in patients with giant cell tumor of bone: a multicenter phase II trial. Ann Oncol 2015;26:2149–2154. Available at: https://www.ncbi.nlm.nih.gov/pubmed/26205395.

393. Tsukamoto S, Tanaka Y, Mavrogenis AF, et al. Is treatment with denosumab associated with local recurrence in patients with giant cell tumor of bone treated with curettage? A systematic review. Clin Orthop Relat Res 2020;478:1076–1085. Available at: https://www.ncbi.nlm.nih.gov/pubmed/31794487.

394. Hindiskere S, Errani C, Doddarangappa S, et al. Is a short-course of preoperative denosumab as effective as prolonged therapy for giant cell tumor of bone? Clin Orthop Relat Res 2020;478:2522–2533. Available at: https://www.ncbi.nlm.nih.gov/pubmed/32401001.

395. Perrin DL, Visgauss JD, Wilson DA, et al. The role of Denosumab in joint preservation for patients with giant cell tumour of bone. Bone Joint J 2021;103-B:184–191. Available at: https://www.ncbi.nlm.nih.gov/pubmed/33380180.

396. Trovarelli G, Rizzo A, Cerchiaro M, et al. The evaluation and management of lung metastases in patients with giant cell tumors of bone in the denosumab era. Curr Oncol 2024;31:2158–2171. Available at: https://www.ncbi.nlm.nih.gov/pubmed/38668063.

397. Rutkowski P, Ferrari S, Grimer RJ, et al. Surgical downstaging in an open-label phase II trial of denosumab in patients with giant cell tumor of bone. Ann Surg Oncol 2015;22:2860–2868. Available at: https://www.ncbi.nlm.nih.gov/pubmed/26033180.

398. Chawla S, Blay JY, Rutkowski P, et al. Denosumab in patients with giant-cell tumour of bone: a multicentre, open-label, phase 2 study. Lancet Oncol 2019;20:1719–1729. Available at: https://www.ncbi.nlm.nih.gov/pubmed/31704134.

399. Martin-Broto J, Cleeland CS, Glare PA, et al. Effects of denosumab on pain and analgesic use in giant cell tumor of bone: interim results from a phase II study. Acta Oncol 2014;53:1173–1179. Available at: https://www.ncbi.nlm.nih.gov/pubmed/24834795.

400. Errani C, Tsukamoto S, Leone G, et al. Denosumab may increase the risk of local recurrence in patients with giant-cell tumor of bone treated with curettage. J Bone Joint Surg Am 2018;100:496–504. Available at: https://www.ncbi.nlm.nih.gov/pubmed/29557866.

401. Scoccianti G, Totti F, Scorianz M, et al. Preoperative denosumab with curettage and cryotherapy in giant cell tumor of bone: is there an increased risk of local recurrence? Clin Orthop Relat Res 2018;476:1783–1790. Available at: https://www.ncbi.nlm.nih.gov/pubmed/30778015.

402. Muller DA, Beltrami G, Scoccianti G, et al. Risks and benefits of combining denosumab and surgery in giant cell tumor of bone-a case series. World J Surg Oncol 2016;14:281. Available at: https://www.ncbi.nlm.nih.gov/pubmed/27809843.

403. Engellau J, Seeger L, Grimer R, et al. Assessment of denosumab treatment effects and imaging response in patients with giant cell tumor of bone. World J Surg Oncol 2018;16:191. Available at: https://www.ncbi.nlm.nih.gov/pubmed/30231890.

Version 2.2026 © 2025 National Comprehensive Cancer Network© (NCCN©), All rights reserved. NCCN Guidelines® and this illustration may not be reproduced in any form without the express written permission of NCCN.

PLEASE NOTE that use of this NCCN Content is governed by the End-User License Agreement, and you MAY NOT distribute this Content or use it with any artificial intelligence model or tool.
Printed by Galya Basol Kochav on 12/28/2025 10:24:40 AM. Copyright © 2025 National Comprehensive Cancer Network, Inc. All Rights Reserved.

404. Aponte-Tinao LA, Piuzzi NS, Roitman P, Farfalli GL. A high-grade sarcoma arising in a patient with recurrent benign giant cell tumor of the proximal tibia while receiving treatment with denosumab. Clin Orthop Relat Res 2015;473:3050–3055. Available at: https://www.ncbi.nlm.nih.gov/pubmed/25758379.

405. Broehm CJ, Garbrecht EL, Wood J, Bocklage T. Two Cases of Sarcoma Arising in Giant Cell Tumor of Bone Treated with Denosumab. Case Rep Med 2015;2015:767198. Available at: https://www.ncbi.nlm.nih.gov/pubmed/26798348.

406. van Langevelde K, Cleven AHG, Navas Canete A, et al. Malignant transformation of giant cell tumor of bone and the association with denosumab treatment: a radiology and pathology perspective. Sarcoma 2022;2022:3425221. Available at: https://www.ncbi.nlm.nih.gov/pubmed/35814640.

407. Kaiser U, Neumann K, Havemann K. Generalised giant-cell tumour of bone: successful treatment of pulmonary metastases with interferon alpha, a case report. J Cancer Res Clin Oncol 1993;119:301–303. Available at: https://www.ncbi.nlm.nih.gov/pubmed/8440744.

408. Yasko AW. Interferon therapy for giant cell tumor of bone. Current Opinion in Orthopaedics 2006;17:568–572 Available at: http://journals.lww.com/co-ortho/Fulltext/2006/12000/Interferon_therapy_for_giant_cell_tumor_of_bone.17.aspx.

409. Kaban LB, Troulis MJ, Wilkinson MS, et al. Adjuvant antiangiogenic therapy for giant cell tumors of the jaws. J Oral Maxillofac Surg 2007;65:2018–2024; discussion 2024. Available at: https://www.ncbi.nlm.nih.gov/pubmed/17884531.

410. Wei F, Liu X, Liu Z, et al. Interferon alfa-2b for recurrent and metastatic giant cell tumor of the spine: report of two cases. Spine (Phila Pa 1976) 2010;35:E1418–1422. Available at: https://www.ncbi.nlm.nih.gov/pubmed/21030898.

411. Lin PP, Guzel VB, Moura MF, et al. Long-term follow-up of patients with giant cell tumor of the sacrum treated with selective arterial embolization. Cancer 2002;95:1317–1325. Available at: https://www.ncbi.nlm.nih.gov/pubmed/12216101.

412. Hosalkar HS, Jones KJ, King JJ, Lackman RD. Serial arterial embolization for large sacral giant-cell tumors: mid- to long-term results. Spine (Phila Pa 1976) 2007;32:1107–1115. Available at: https://www.ncbi.nlm.nih.gov/pubmed/17471094.

413. Onishi H, Kaya M, Wada T, et al. Giant cell tumor of the sacrum treated with selective arterial embolization. Int J Clin Oncol 2010;15:416–419. Available at: https://www.ncbi.nlm.nih.gov/pubmed/20198397.

414. Emori M, Kaya M, Sasaki M, et al. Pre-operative selective arterial embolization as a neoadjuvant therapy for proximal humerus giant cell tumor of bone: radiological and histological evaluation. Jpn J Clin Oncol 2012;42:851–855. Available at: https://www.ncbi.nlm.nih.gov/pubmed/22689917.

415. SEER Cancer Statistics Fact Sheets: Bone and Joint Cancer. Bethesda, MD: National Cancer Institute; 2021. Available at: http://seer.cancer.gov/statfacts/html/bones.html. Accessed September 8, 2021.

416. Prescribing information: denosumab injection, for subcutaneous use. 2021. Available at: https://www.accessdata.fda.gov/drugsatfda_docs/label/2021/125320s207lbl.pdf. Accessed September 8, 2021.

417. Cheng JC, Johnston JO. Giant cell tumor of bone. Prognosis and treatment of pulmonary metastases. Clin Orthop Relat Res 1997:205–214. Available at: https://www.ncbi.nlm.nih.gov/pubmed/9170381.

418. Siebenrock KA, Unni KK, Rock MG. Giant-cell tumour of bone metastasising to the lungs. A long-term follow-up. J Bone Joint Surg Br 1998;80:43–47. Available at: https://www.ncbi.nlm.nih.gov/pubmed/9460951.

Version 2.2026 © 2025 National Comprehensive Cancer Network© (NCCN©), All rights reserved. NCCN Guidelines® and this illustration may not be reproduced in any form without the express written permission of NCCN.

PLEASE NOTE that use of this NCCN Content is governed by the End-User License Agreement, and you MAY NOT distribute this Content or use it with any artificial intelligence model or tool.
Printed by Galya Basol Kochav on 12/28/2025 10:24:40 AM. Copyright © 2025 National Comprehensive Cancer Network, Inc. All Rights Reserved.

419. Rosario M, Kim HS, Yun JY, Han I. Surveillance for lung metastasis from giant cell tumor of bone. J Surg Oncol 2017;116:907–913. Available at: https://www.ncbi.nlm.nih.gov/pubmed/28650536.

420. Kim C, Davis LE, Albert CM, et al. Osteosarcoma in pediatric and adult populations: are adults just big kids? Cancers (Basel) 2023;15. Available at: https://www.ncbi.nlm.nih.gov/pubmed/37894411.

421. Klein MJ, Siegal GP. Osteosarcoma: anatomic and histologic variants. Am J Clin Pathol 2006;125:555–581. Available at: https://www.ncbi.nlm.nih.gov/pubmed/16627266.

422. Antonescu CR, Huvos AG. Low-grade osteogenic sarcoma arising in medullary and surface osseous locations. Am J Clin Pathol 2000;114 Suppl:S90–103. Available at: https://www.ncbi.nlm.nih.gov/pubmed/11996175.

423. Sheth DS, Yasko AW, Raymond AK, et al. Conventional and dedifferentiated parosteal osteosarcoma. Diagnosis, treatment, and outcome. Cancer 1996;78:2136–2145. Available at: https://www.ncbi.nlm.nih.gov/pubmed/8918422.

424. Bertoni F, Bacchini P, Staals EL, Davidovitz P. Dedifferentiated parosteal osteosarcoma: the experience of the Rizzoli Institute. Cancer 2005;103:2373–2382. Available at: https://www.ncbi.nlm.nih.gov/pubmed/15852358.

425. Okada K, Unni KK, Swee RG, Sim FH. High grade surface osteosarcoma: a clinicopathologic study of 46 cases. Cancer 1999;85:1044–1054. Available at: https://www.ncbi.nlm.nih.gov/pubmed/10091787.

426. Staals EL, Bacchini P, Bertoni F. High-grade surface osteosarcoma: a review of 25 cases from the Rizzoli Institute. Cancer 2008;112:1592–1599. Available at: https://www.ncbi.nlm.nih.gov/pubmed/18300258.

427. Davis AM, Bell RS, Goodwin PJ. Prognostic factors in osteosarcoma: a critical review. J Clin Oncol 1994;12:423–431. Available at: https://www.ncbi.nlm.nih.gov/pubmed/8113851.

428. Ferrari S, Bertoni F, Mercuri M, et al. Predictive factors of disease-free survival for non-metastatic osteosarcoma of the extremity: an analysis of 300 patients treated at the Rizzoli Institute. Ann Oncol 2001;12:1145–1150. Available at: https://www.ncbi.nlm.nih.gov/pubmed/11583198.

429. Bielack SS, Kempf-Bielack B, Delling G, et al. Prognostic factors in high-grade osteosarcoma of the extremities or trunk: an analysis of 1,702 patients treated on neoadjuvant cooperative osteosarcoma study group protocols. J Clin Oncol 2002;20:776–790. Available at: https://www.ncbi.nlm.nih.gov/pubmed/11821461.

430. Bacci G, Longhi A, Ferrari S, et al. Prognostic significance of serum lactate dehydrogenase in osteosarcoma of the extremity: experience at Rizzoli on 1421 patients treated over the last 30 years. Tumori 2004;90:478–484. Available at: https://www.ncbi.nlm.nih.gov/pubmed/15656333.

431. Bacci G, Longhi A, Versari M, et al. Prognostic factors for osteosarcoma of the extremity treated with neoadjuvant chemotherapy: 15-year experience in 789 patients treated at a single institution. Cancer 2006;106:1154–1161. Available at: https://www.ncbi.nlm.nih.gov/pubmed/16421923.

432. Whelan JS, Jinks RC, McTiernan A, et al. Survival from high-grade localised extremity osteosarcoma: combined results and prognostic factors from three European Osteosarcoma Intergroup randomised controlled trials. Ann Oncol 2012;23:1607–1616. Available at: https://www.ncbi.nlm.nih.gov/pubmed/22015453.

433. Ogura K, Fujiwara T, Yasunaga H, et al. Development and external validation of nomograms predicting distant metastases and overall survival after neoadjuvant chemotherapy and surgery for patients with nonmetastatic osteosarcoma: A multi-institutional study. Cancer 2015;121:3844–3852. Available at: https://www.ncbi.nlm.nih.gov/pubmed/26194185.

434. Bertrand TE, Cruz A, Binitie O, et al. Do surgical margins affect local recurrence and survival in extremity, nonmetastatic, high-grade

Version 2.2026 © 2025 National Comprehensive Cancer Network© (NCCN©), All rights reserved. NCCN Guidelines® and this illustration may not be reproduced in any form without the express written permission of NCCN.

PLEASE NOTE that use of this NCCN Content is governed by the End-User License Agreement, and you MAY NOT distribute this Content or use it with any artificial intelligence model or tool.
Printed by Galya Basol Kochav on 12/28/2025 10:24:40 AM. Copyright © 2025 National Comprehensive Cancer Network, Inc. All Rights Reserved.

osteosarcoma? Clin Orthop Relat Res 2016;474:677–683. Available at: https://www.ncbi.nlm.nih.gov/pubmed/26013153.

435. Lee RJ, Arshi A, Schwartz HC, Christensen RE. Characteristics and prognostic factors of osteosarcoma of the jaws: a retrospective cohort study. JAMA Otolaryngol Head Neck Surg 2015;141:470–477. Available at: https://www.ncbi.nlm.nih.gov/pubmed/25811167.

436. Xin S, Wei G. Prognostic factors in osteosarcoma: A study level meta-analysis and systematic review of current practice. J Bone Oncol 2020;21:100281. Available at: https://www.ncbi.nlm.nih.gov/pubmed/32140401.

437. Collins M, Wilhelm M, Conyers R, et al. Benefits and adverse events in younger versus older patients receiving neoadjuvant chemotherapy for osteosarcoma: findings from a meta-analysis. J Clin Oncol 2013;31:2303–2312. Available at: https://www.ncbi.nlm.nih.gov/pubmed/23669227.

438. Altaf S, Enders F, Jeavons E, et al. High-BMI at diagnosis is associated with inferior survival in patients with osteosarcoma: a report from the Children's Oncology Group. Pediatr Blood Cancer 2013;60:2042–2046. Available at: https://www.ncbi.nlm.nih.gov/pubmed/23955975.

439. Bacci G, Briccoli A, Ferrari S, et al. Neoadjuvant chemotherapy for osteosarcoma of the extremities with synchronous lung metastases: treatment with cisplatin, adriamycin and high dose of methotrexate and ifosfamide. Oncol Rep 2000;7:339–346. Available at: https://www.ncbi.nlm.nih.gov/pubmed/10671683.

440. Daw NC, Billups CA, Rodriguez-Galindo C, et al. Metastatic osteosarcoma. Cancer 2006;106:403–412. Available at: https://www.ncbi.nlm.nih.gov/pubmed/16353204.

441. Fu Y, Lan T, Cai H, et al. Meta-analysis of serum lactate dehydrogenase and prognosis for osteosarcoma. Medicine (Baltimore) 2018;97:e0741. Available at: https://www.ncbi.nlm.nih.gov/pubmed/29742740.

442. Gu R, Sun Y. Does serum alkaline phosphatase level really indicate the prognosis in patients with osteosarcoma? A meta-analysis. J Cancer Res Ther 2018;14:S468–S472. Available at: https://www.ncbi.nlm.nih.gov/pubmed/29970708.

443. Sun J, Xu H, Qi M, et al. Identification of key genes in osteosarcoma by meta-analysis of gene expression microarray. Mol Med Rep 2019;20:3075–3084. Available at: https://www.ncbi.nlm.nih.gov/pubmed/31432118.

444. Marulanda GA, Henderson ER, Johnson DA, et al. Orthopedic surgery options for the treatment of primary osteosarcoma. Cancer Control 2008;15:13–20. Available at: https://www.ncbi.nlm.nih.gov/pubmed/18094657.

445. Bacci G, Ferrari S, Lari S, et al. Osteosarcoma of the limb. Amputation or limb salvage in patients treated by neoadjuvant chemotherapy. J Bone Joint Surg Br 2002;84:88–92. Available at: https://www.ncbi.nlm.nih.gov/pubmed/11837839.

446. Mavrogenis AF, Abati CN, Romagnoli C, Ruggieri P. Similar survival but better function for patients after limb salvage versus amputation for distal tibia osteosarcoma. Clin Orthop Relat Res 2012;470:1735–1748. Available at: https://www.ncbi.nlm.nih.gov/pubmed/22270466.

447. Simon MA, Aschliman MA, Thomas N, Mankin HJ. Limb-salvage treatment versus amputation for osteosarcoma of the distal end of the femur. 1986. J Bone Joint Surg Am 2005;87:2822. Available at: https://www.ncbi.nlm.nih.gov/pubmed/16322634.

448. Aksnes LH, Bauer HCF, Jebsen NL, et al. Limb-sparing surgery preserves more function than amputation: a Scandinavian sarcoma group study of 118 patients. J Bone Joint Surg Br 2008;90:786–794. Available at: http://www.ncbi.nlm.nih.gov/pubmed18539673.

449. Nagarajan R, Neglia JP, Clohisy DR, Robison LL. Limb salvage and amputation in survivors of pediatric lower-extremity bone tumors: what are the long-term implications? J Clin Oncol 2002;20:4493–4501. Available at: http://www.ncbi.nlm.nih.gov/pubmed12431974.

Version 2.2026 © 2025 National Comprehensive Cancer Network© (NCCN©), All rights reserved. NCCN Guidelines® and this illustration may not be reproduced in any form without the express written permission of NCCN.

PLEASE NOTE that use of this NCCN Content is governed by the End-User License Agreement, and you MAY NOT distribute this Content or use it with any artificial intelligence model or tool.
Printed by Galya Basol Kochav on 12/28/2025 10:24:40 AM. Copyright © 2025 National Comprehensive Cancer Network, Inc. All Rights Reserved.

450. Carrle D, Bielack SS. Current strategies of chemotherapy in osteosarcoma. Int Orthop 2006;30:445–451. Available at: https://www.ncbi.nlm.nih.gov/pubmed/16896870.

451. Winkler K, Beron G, Kotz R, et al. Neoadjuvant chemotherapy for osteogenic sarcoma: results of a Cooperative German/Austrian study. J Clin Oncol 1984;2:617–624. Available at: https://www.ncbi.nlm.nih.gov/pubmed/6202851.

452. Link MP, Goorin AM, Miser AW, et al. The effect of adjuvant chemotherapy on relapse-free survival in patients with osteosarcoma of the extremity. N Engl J Med 1986;314:1600–1606. Available at: https://www.ncbi.nlm.nih.gov/pubmed/3520317.

453. Eilber F, Giuliano A, Eckardt J, et al. Adjuvant chemotherapy for osteosarcoma: a randomized prospective trial. J Clin Oncol 1987;5:21–26. Available at: https://www.ncbi.nlm.nih.gov/pubmed/3543236.

454. Link MP, Goorin AM, Horowitz M, et al. Adjuvant chemotherapy of high-grade osteosarcoma of the extremity. Updated results of the Multi-Institutional Osteosarcoma Study. Clin Orthop Relat Res 1991:8–14. Available at: https://www.ncbi.nlm.nih.gov/pubmed/1884563.

455. Meyers PA, Heller G, Healey J, et al. Chemotherapy for nonmetastatic osteogenic sarcoma: the Memorial Sloan-Kettering experience. J Clin Oncol 1992;10:5–15. Available at: https://www.ncbi.nlm.nih.gov/pubmed/1370176.

456. Goorin AM, Schwartzentruber DJ, Devidas M, et al. Presurgical chemotherapy compared with immediate surgery and adjuvant chemotherapy for nonmetastatic osteosarcoma: Pediatric Oncology Group Study POG-8651. J Clin Oncol 2003;21:1574–1580. Available at: https://www.ncbi.nlm.nih.gov/pubmed/12697883.

457. Bramwell VH, Burgers M, Sneath R, et al. A comparison of two short intensive adjuvant chemotherapy regimens in operable osteosarcoma of limbs in children and young adults: the first study of the European Osteosarcoma Intergroup. J Clin Oncol 1992;10:1579–1591. Available at: https://www.ncbi.nlm.nih.gov/pubmed/1403038.

458. Souhami RL, Craft AW, Van der Eijken JW, et al. Randomised trial of two regimens of chemotherapy in operable osteosarcoma: a study of the European Osteosarcoma Intergroup. Lancet 1997;350:911–917. Available at: https://www.ncbi.nlm.nih.gov/pubmed/9314869.

459. Fuchs N, Bielack SS, Epler D, et al. Long-term results of the co-operative German-Austrian-Swiss osteosarcoma study group's protocol COSS-86 of intensive multidrug chemotherapy and surgery for osteosarcoma of the limbs. Ann Oncol 1998;9:893–899. Available at: https://www.ncbi.nlm.nih.gov/pubmed/9789613.

460. Bacci G, Ferrari S, Bertoni F, et al. Long-term outcome for patients with nonmetastatic osteosarcoma of the extremity treated at the istituto ortopedico rizzoli according to the istituto ortopedico rizzoli/osteosarcoma-2 protocol: an updated report. J Clin Oncol 2000;18:4016–4027. Available at: http://www.ncbi.nlm.nih.gov/pubmed/11118462.

461. Bacci G, Briccoli A, Ferrari S, et al. Neoadjuvant chemotherapy for osteosarcoma of the extremity: long-term results of the Rizzoli's 4th protocol. Eur J Cancer 2001;37:2030–2039. Available at: http://www.ncbi.nlm.nih.gov/pubmed/11597381.

462. Ferrari S, Smeland S, Mercuri M, et al. Neoadjuvant chemotherapy with high-dose Ifosfamide, high-dose methotrexate, cisplatin, and doxorubicin for patients with localized osteosarcoma of the extremity: a joint study by the Italian and Scandinavian Sarcoma Groups. J Clin Oncol 2005;23:8845–8852. Available at: https://www.ncbi.nlm.nih.gov/pubmed/16246977.

463. Lewis IJ, Nooij MA, Whelan J, et al. Improvement in histologic response but not survival in osteosarcoma patients treated with intensified chemotherapy: a randomized phase III trial of the European Osteosarcoma Intergroup. J Natl Cancer Inst 2007;99:112–128. Available at: https://www.ncbi.nlm.nih.gov/pubmed/17227995.

464. Meyers PA, Schwartz CL, Krailo MD, et al. Osteosarcoma: the addition of muramyl tripeptide to chemotherapy improves overall survival--a report from the Children's Oncology Group. J Clin Oncol 2008;26:633–638. Available at: https://www.ncbi.nlm.nih.gov/pubmed/18235123.

Version 2.2026 © 2025 National Comprehensive Cancer Network© (NCCN©), All rights reserved. NCCN Guidelines® and this illustration may not be reproduced in any form without the express written permission of NCCN.

PLEASE NOTE that use of this NCCN Content is governed by the End-User License Agreement, and you MAY NOT distribute this Content or use it with any artificial intelligence model or tool.
Printed by Galya Basol Kochav on 12/28/2025 10:24:40 AM. Copyright © 2025 National Comprehensive Cancer Network, Inc. All Rights Reserved.

465. Winkler K, Beron G, Delling G, et al. Neoadjuvant chemotherapy of osteosarcoma: results of a randomized cooperative trial (COSS-82) with salvage chemotherapy based on histological tumor response. J Clin Oncol 1988;6:329–337. Available at: https://www.ncbi.nlm.nih.gov/pubmed/2448428.

466. Li Z, Ma X, Wang Z, et al. A meta-analysis of the efficacy and safety of first-line chemotherapeutic agents for osteosarcoma. Adv Clin Exp Med 2024;33:445–454. Available at: https://www.ncbi.nlm.nih.gov/pubmed/37747442.

467. Basaran M, Bavbek ES, Saglam S, et al. A phase II study of cisplatin, ifosfamide and epirubicin combination chemotherapy in adults with nonmetastatic and extremity osteosarcomas. Oncology 2007;72:255–260. Available at: https://www.ncbi.nlm.nih.gov/pubmed/18185020.

468. Le Deley MC, Guinebretiere JM, Gentet JC, et al. SFOP OS94: a randomised trial comparing preoperative high-dose methotrexate plus doxorubicin to high-dose methotrexate plus etoposide and ifosfamide in osteosarcoma patients. Eur J Cancer 2007;43:752–761. Available at: https://www.ncbi.nlm.nih.gov/pubmed/17267204.

469. Provisor AJ, Ettinger LJ, Nachman JB, et al. Treatment of nonmetastatic osteosarcoma of the extremity with preoperative and postoperative chemotherapy: a report from the Children's Cancer Group. J Clin Oncol 1997;15:76–84. Available at: https://www.ncbi.nlm.nih.gov/pubmed/8996127.

470. Bernthal NM, Federman N, Eilber FR, et al. Long-term results (>25 years) of a randomized, prospective clinical trial evaluating chemotherapy in patients with high-grade, operable osteosarcoma. Cancer 2012;118:5888–5893. Available at: https://www.ncbi.nlm.nih.gov/pubmed/22648705.

471. Bacci G, Mercuri M, Longhi A, et al. Grade of chemotherapy-induced necrosis as a predictor of local and systemic control in 881 patients with non-metastatic osteosarcoma of the extremities treated with neoadjuvant chemotherapy in a single institution. Eur J Cancer 2005;41:2079–2085. Available at: http://www.ncbi.nlm.nih.gov/pubmed/16115755.

472. Cesari M, Alberghini M, Vanel D, et al. Periosteal osteosarcoma: a single-institution experience. Cancer 2011;117:1731–1735. Available at: https://www.ncbi.nlm.nih.gov/pubmed/21472720.

473. Grimer RJ, Bielack S, Flege S, et al. Periosteal osteosarcoma--a European review of outcome. Eur J Cancer 2005;41:2806–2811. Available at: https://www.ncbi.nlm.nih.gov/pubmed/16290134.

474. Tsukamoto S, Righi A, Kido A, et al. Effect of adjuvant chemotherapy on periosteal osteosarcoma: a systematic review. Jpn J Clin Oncol 2022;52:896–904. Available at: https://www.ncbi.nlm.nih.gov/pubmed/35485208.

475. Bacci G, Ferrari S, Tienghi A, et al. A comparison of methods of loco-regional chemotherapy combined with systemic chemotherapy as neo-adjuvant treatment of osteosarcoma of the extremity. Eur J Surg Oncol 2001;27:98–9104. Available at: http://www.ncbi.nlm.nih.gov/pubmed/11237499.

476. Guadagnolo BA, Zagars GK, Raymond AK, et al. Osteosarcoma of the jaw/craniofacial region: outcomes after multimodality treatment. Cancer 2009;115:3262–3270. Available at: https://www.ncbi.nlm.nih.gov/pubmed/19382187.

477. Ciernik IF, Niemierko A, Harmon DC, et al. Proton-based radiotherapy for unresectable or incompletely resected osteosarcoma. Cancer 2011;117:4522–4530. Available at: https://www.ncbi.nlm.nih.gov/pubmed/21448934.

478. DeLaney TF, Park L, Goldberg SI, et al. Radiotherapy for local control of osteosarcoma. Int J Radiat Oncol Biol Phys 2005;61:492–498. Available at: https://www.ncbi.nlm.nih.gov/pubmed/15667972.

479. Marina NM, Smeland S, Bielack SS, et al. Comparison of MAPIE versus MAP in patients with a poor response to preoperative chemotherapy for newly diagnosed high-grade osteosarcoma (EURAMOS-1): an open-label, international, randomised controlled trial. Lancet Oncol 2016;17:1396–1408. Available at: https://www.ncbi.nlm.nih.gov/pubmed/27569442.

Version 2.2026 © 2025 National Comprehensive Cancer Network© (NCCN©), All rights reserved. NCCN Guidelines® and this illustration may not be reproduced in any form without the express written permission of NCCN.

PLEASE NOTE that use of this NCCN Content is governed by the End-User License Agreement, and you MAY NOT distribute this Content or use it with any artificial intelligence model or tool.
Printed by Galya Basol Kochav on 12/28/2025 10:24:40 AM. Copyright © 2025 National Comprehensive Cancer Network, Inc. All Rights Reserved.

480. Smeland S, Muller C, Alvegard TA, et al. Scandinavian Sarcoma Group Osteosarcoma Study SSG VIII: prognostic factors for outcome and the role of replacement salvage chemotherapy for poor histological responders. Eur J Cancer 2003;39:488–494. Available at: https://www.ncbi.nlm.nih.gov/pubmed/12751380.

481. Smeland S, Bruland OS, Hjorth L, et al. Results of the Scandinavian Sarcoma Group XIV protocol for classical osteosarcoma: 63 patients with a minimum follow-up of 4 years. Acta Orthop 2011;82:211–216. Available at: https://www.ncbi.nlm.nih.gov/pubmed/21434784.

482. Ferrari S, Ruggieri P, Cefalo G, et al. Neoadjuvant chemotherapy with methotrexate, cisplatin, and doxorubicin with or without ifosfamide in nonmetastatic osteosarcoma of the extremity: An Italian Sarcoma Group trial ISG/OS-1. J Clin Oncol 2012;30:2112–2118. Available at: http://www.ncbi.nlm.nih.gov/pubmed/22564997.

483. Bielack SS, Smeland S, Whelan JS, et al. Methotrexate, doxorubicin, and cisplatin (MAP) plus maintenance pegylated interferon alfa-2b versus MAP alone in patients with resectable high-grade osteosarcoma and good histologic response to preoperative MAP: first results of the EURAMOS-1 good response randomized controlled trial. J Clin Oncol 2015;33:2279–2287. Available at: https://www.ncbi.nlm.nih.gov/pubmed/26033801.

484. Meyers PA, Heller G, Healey JH, et al. Osteogenic sarcoma with clinically detectable metastasis at initial presentation. J Clin Oncol 1993;11:449–453. Available at: http://www.ncbi.nlm.nih.gov/pubmed/8445419.

485. Sheng G, Gao Y, Yang Y, Wu H. Osteosarcoma and metastasis. Front Oncol 2021;11:780264. Available at: https://www.ncbi.nlm.nih.gov/pubmed/34956899.

486. Bacci G, Briccoli A, Mercuri M, et al. Osteosarcoma of the extremities with synchronous lung metastases: long-term results in 44 patients treated with neoadjuvant chemotherapy. J Chemother 1998;10:69–76. Available at: https://www.ncbi.nlm.nih.gov/pubmed/9531078.

487. Bacci G, Briccoli A, Rocca M, et al. Neoadjuvant chemotherapy for osteosarcoma of the extremities with metastases at presentation: recent experience at the Rizzoli Institute in 57 patients treated with cisplatin, doxorubicin, and a high dose of methotrexate and ifosfamide. Ann Oncol 2003;14:1126–1134. Available at: http://www.ncbi.nlm.nih.gov/pubmed/12853357.

488. Smeland S, Bielack SS, Whelan J, et al. Survival and prognosis with osteosarcoma: outcomes in more than 2000 patients in the EURAMOS-1 (European and American Osteosarcoma Study) cohort. Eur J Cancer 2019;109:36–50. Available at: https://www.ncbi.nlm.nih.gov/pubmed/30685685.

489. Goorin AM, Harris MB, Bernstein M, et al. Phase II/III trial of etoposide and high-dose ifosfamide in newly diagnosed metastatic osteosarcoma: a pediatric oncology group trial. J Clin Oncol 2002;20:426–433. Available at: https://www.ncbi.nlm.nih.gov/pubmed/11786570.

490. Winkler K, Torggler S, Beron G, et al. [Results of treatment in primary disseminated osteosarcoma. Analysis of the follow-up of patients in the cooperative osteosarcoma studies COSS-80 and COSS-82]. Onkologie 1989;12:92–96. Available at: https://www.ncbi.nlm.nih.gov/pubmed/2660050.

491. Bacci G, Mercuri M, Briccoli A, et al. Osteogenic sarcoma of the extremity with detectable lung metastases at presentation. Results of treatment of 23 patients with chemotherapy followed by simultaneous resection of primary and metastatic lesions. Cancer 1997;79:245–254. Available at: https://www.ncbi.nlm.nih.gov/pubmed/9010097.

492. Mettmann VL, Blattmann C, Friedel G, et al. Primary multi-systemic metastases in osteosarcoma: presentation, treatment, and survival of 83 patients of the Cooperative Osteosarcoma Study Group. Cancers (Basel) 2024;16:275. Available at: https://www.ncbi.nlm.nih.gov/pubmed/38254767.

493. Daw NC, Chou AJ, Jaffe N, et al. Recurrent osteosarcoma with a single pulmonary metastasis: a multi-institutional review. Br J Cancer

Version 2.2026 © 2025 National Comprehensive Cancer Network© (NCCN©), All rights reserved. NCCN Guidelines® and this illustration may not be reproduced in any form without the express written permission of NCCN.

PLEASE NOTE that use of this NCCN Content is governed by the End-User License Agreement, and you MAY NOT distribute this Content or use it with any artificial intelligence model or tool.
Printed by Galya Basol Kochav on 12/28/2025 10:24:40 AM. Copyright © 2025 National Comprehensive Cancer Network, Inc. All Rights Reserved.

2015;112:278–282. Available at: https://www.ncbi.nlm.nih.gov/pubmed/25422914.

494. Tabone MD, Kalifa C, Rodary C, et al. Osteosarcoma recurrences in pediatric patients previously treated with intensive chemotherapy. J Clin Oncol 1994;12:2614–2620. Available at: https://www.ncbi.nlm.nih.gov/pubmed/7989936.

495. Saeter G, Hoie J, Stenwig AE, et al. Systemic relapse of patients with osteogenic sarcoma. Prognostic factors for long term survival. Cancer 1995;75:1084–1093. Available at: https://www.ncbi.nlm.nih.gov/pubmed/7850705.

496. Ferrari S, Briccoli A, Mercuri M, et al. Postrelapse survival in osteosarcoma of the extremities: prognostic factors for long-term survival. J Clin Oncol 2003;21:710–715. Available at: https://www.ncbi.nlm.nih.gov/pubmed/12586810.

497. Buddingh EP, Anninga JK, Versteegh MI, et al. Prognostic factors in pulmonary metastasized high-grade osteosarcoma. Pediatr Blood Cancer 2010;54:216–221. Available at: https://www.ncbi.nlm.nih.gov/pubmed/19890902.

498. Briccoli A, Rocca M, Salone M, et al. High grade osteosarcoma of the extremities metastatic to the lung: long-term results in 323 patients treated combining surgery and chemotherapy, 1985-2005. Surg Oncol 2010;19:193–199. Available at: https://www.ncbi.nlm.nih.gov/pubmed/19515554.

499. Bielack SS, Kempf-Bielack B, Branscheid D, et al. Second and subsequent recurrences of osteosarcoma: presentation, treatment, and outcomes of 249 consecutive cooperative osteosarcoma study group patients. J Clin Oncol 2009;27:557–565. Available at: https://www.ncbi.nlm.nih.gov/pubmed/19075282.

500. Berger M, Grignani G, Ferrari S, et al. Phase 2 trial of two courses of cyclophosphamide and etoposide for relapsed high-risk osteosarcoma patients. Cancer 2009;115:2980–2987. Available at: https://www.ncbi.nlm.nih.gov/pubmed/19452540.

501. Gentet JC, Brunat-Mentigny M, Demaille MC, et al. Ifosfamide and etoposide in childhood osteosarcoma. A phase II study of the French Society of Paediatric Oncology. Eur J Cancer 1997;33:232–237. Available at: https://www.ncbi.nlm.nih.gov/pubmed/9135494.

502. Miser JS, Kinsella TJ, Triche TJ, et al. Ifosfamide with mesna uroprotection and etoposide: an effective regimen in the treatment of recurrent sarcomas and other tumors of children and young adults. J Clin Oncol 1987;5:1191–1198. Available at: https://www.ncbi.nlm.nih.gov/pubmed/3114435.

503. Duffaud F, Mir O, Boudou-Rouquette P, et al. Efficacy and safety of regorafenib in adult patients with metastatic osteosarcoma: a non-comparative, randomised, double-blind, placebo-controlled, phase 2 study. Lancet Oncol 2019;20:120–133. Available at: https://www.ncbi.nlm.nih.gov/pubmed/30477937.

504. Davis LE, Bolejack V, Ryan CW, et al. Randomized double-blind phase II study of regorafenib in patients with metastatic osteosarcoma. J Clin Oncol 2019;37:1424–1431. Available at: https://www.ncbi.nlm.nih.gov/pubmed/31013172.

505. Merimsky O, Meller I, Flusser G, et al. Gemcitabine in soft tissue or bone sarcoma resistant to standard chemotherapy: a phase II study. Cancer Chemother Pharmacol 2000;45:177–181. Available at: https://www.ncbi.nlm.nih.gov/pubmed/10663634.

506. Palmerini E, Jones RL, Marchesi E, et al. Gemcitabine and docetaxel in relapsed and unresectable high-grade osteosarcoma and spindle cell sarcoma of bone. BMC Cancer 2016;16:280. Available at: https://www.ncbi.nlm.nih.gov/pubmed/27098543.

507. Magnan H, Goodbody CM, Riedel E, et al. Ifosfamide dose-intensification for patients with metastatic Ewing sarcoma. Pediatr Blood Cancer 2015;62:594–597. Available at: https://www.ncbi.nlm.nih.gov/pubmed/25630954.

508. Maki RG, Wathen JK, Patel SR, et al. Randomized phase II study of gemcitabine and docetaxel compared with gemcitabine alone in patients

Version 2.2026 © 2025 National Comprehensive Cancer Network© (NCCN©), All rights reserved. NCCN Guidelines® and this illustration may not be reproduced in any form without the express written permission of NCCN.

PLEASE NOTE that use of this NCCN Content is governed by the End-User License Agreement, and you MAY NOT distribute this Content or use it with any artificial intelligence model or tool.
Printed by Galya Basol Kochav on 12/28/2025 10:24:40 AM. Copyright © 2025 National Comprehensive Cancer Network, Inc. All Rights Reserved.

with metastatic soft tissue sarcomas: results of sarcoma alliance for research through collaboration study 002 [corrected]. J Clin Oncol 2007;25:2755–2763. Available at: https://www.ncbi.nlm.nih.gov/pubmed/17602081.

509. Low K, Foulkes P, Hills F, et al. The efficacy of gemcitabine and docetaxel chemotherapy for the treatment of relapsed and refractory osteosarcoma: A systematic review and pre-clinical study. Cancer Med 2024;13:e70248. Available at: https://www.ncbi.nlm.nih.gov/pubmed/39315544.

510. Subbiah V, Anderson PM, Kairemo K, et al. Alpha particle radium 223 dichloride in high-risk osteosarcoma: a phase I dose escalation trial. Clin Cancer Res 2019;25:3802–3810. Available at: https://www.ncbi.nlm.nih.gov/pubmed/30733229.

511. Anderson PM, Wiseman GA, Dispenzieri A, et al. High-dose samarium-153 ethylene diamine tetramethylene phosphonate: low toxicity of skeletal irradiation in patients with osteosarcoma and bone metastases. J Clin Oncol 2002;20:189–196. Available at: https://www.ncbi.nlm.nih.gov/pubmed/11773169.

512. Loeb DM, Garrett-Mayer E, Hobbs RF, et al. Dose-finding study of 153Sm-EDTMP in patients with poor-prognosis osteosarcoma. Cancer 2009;115:2514–2522. Available at: https://www.ncbi.nlm.nih.gov/pubmed/19338063.

513. Grignani G, Palmerini E, Dileo P, et al. A phase II trial of sorafenib in relapsed and unresectable high-grade osteosarcoma after failure of standard multimodal therapy: an Italian Sarcoma Group study. Ann Oncol 2012;23:508–516. Available at: https://www.ncbi.nlm.nih.gov/pubmed/21527590.

514. Grignani G, Palmerini E, Ferraresi V, et al. Sorafenib and everolimus for patients with unresectable high-grade osteosarcoma progressing after standard treatment: a non-randomised phase 2 clinical trial. Lancet Oncol 2015;16:98–107. Available at: https://www.ncbi.nlm.nih.gov/pubmed/25498219.

515. Lashkari A, Chow WA, Valdes F, et al. Tandem high-dose chemotherapy followed by autologous transplantation in patients with locally advanced or metastatic sarcoma. Anticancer Res 2009;29:3281–3288. Available at: https://www.ncbi.nlm.nih.gov/pubmed/19661346.

516. Fagioli F, Aglietta M, Tienghi A, et al. High-dose chemotherapy in the treatment of relapsed osteosarcoma: an Italian sarcoma group study. J Clin Oncol 2002;20:2150–2156. Available at: https://www.ncbi.nlm.nih.gov/pubmed/11956277.

517. Elledge CR, Krasin MJ, Ladra MM, et al. A multi-institutional phase 2 trial of stereotactic body radiotherapy in the treatment of bone metastases in pediatric and young adult patients with sarcoma. Cancer 2021;127:739–747. Available at: https://www.ncbi.nlm.nih.gov/pubmed/33170960.

518. Papagelopoulos PJ, Galanis EC, Sim FH, Unni KK. Clinicopathologic features, diagnosis, and treatment of malignant fibrous histiocytoma of bone. Orthopedics 2000;23:59–65; quiz 66–57. Available at: https://www.ncbi.nlm.nih.gov/pubmed/10642003.

519. Bacci G, Avella M, Picci P, et al. Primary chemotherapy and delayed surgery for malignant fibrous histiocytoma of bone in the extremity. Tumori 1990;76:537–542. Available at: https://www.ncbi.nlm.nih.gov/pubmed/2178284.

520. Bacci G, Picci P, Mercuri M, et al. Neoadjuvant chemotherapy for high grade malignant fibrous histiocytoma of bone. Clin Orthop Relat Res 1998:178–189. Available at: https://www.ncbi.nlm.nih.gov/pubmed/9577426.

521. Bramwell VH, Steward WP, Nooij M, et al. Neoadjuvant chemotherapy with doxorubicin and cisplatin in malignant fibrous histiocytoma of bone: A European Osteosarcoma Intergroup study. J Clin Oncol 1999;17:3260–3269. Available at: https://www.ncbi.nlm.nih.gov/pubmed/10506628.

522. (NCI) NCI. NCI Dictionary of Cancer Terms: National Cancer Institute; 2025. Available at:

Version 2.2026 © 2025 National Comprehensive Cancer Network© (NCCN©), All rights reserved. NCCN Guidelines® and this illustration may not be reproduced in any form without the express written permission of NCCN.

PLEASE NOTE that use of this NCCN Content is governed by the End-User License Agreement, and you MAY NOT distribute this Content or use it with any artificial intelligence model or tool.
Printed by Galya Basol Kochav on 12/28/2025 10:24:40 AM. Copyright © 2025 National Comprehensive Cancer Network, Inc. All Rights Reserved.

https://www.cancer.gov/publications/dictionaries/cancer-terms/def/multigene-panel-test.

523. Centers for Medicare & Medicaid Services. Billing and coding: MolDX: targeted and comprehensive genomic profile next generation sequencing testing in cancer. Available at: https://www.cms.gov/medicare-coverage-database/view/article.aspx?articleid=54901&ver=15&LCDId=36021&Date=&DocID=A56973&bc=gQAAAAIAIAAA. Accessed September 8, 2021.

524. Groisberg R, Hong DS, Holla V, et al. Clinical genomic profiling to identify actionable alterations for investigational therapies in patients with diverse sarcomas. Oncotarget 2017;8:39254–39267. Available at: https://www.ncbi.nlm.nih.gov/pubmed/28424409.

525. Xie X, Bian Y, Li H, et al. A Comprehensive Understanding of the Genomic Bone Tumor Landscape: A Multicenter Prospective Study. Front Oncol 2022;12:835004. Available at: https://www.ncbi.nlm.nih.gov/pubmed/35756627.

526. Maio M, Ascierto PA, Manzyuk L, et al. Pembrolizumab in microsatellite instability high or mismatch repair deficient cancers: updated analysis from the phase II KEYNOTE-158 study. Ann Oncol 2022;33:929–938. Available at: https://www.ncbi.nlm.nih.gov/pubmed/35680043.

527. Marabelle A, Fakih M, Lopez J, et al. Association of tumour mutational burden with outcomes in patients with advanced solid tumours treated with pembrolizumab: prospective biomarker analysis of the multicohort, open-label, phase 2 KEYNOTE-158 study. Lancet Oncol 2020;21:1353–1365. Available at: https://www.ncbi.nlm.nih.gov/pubmed/32919526.

528. Schenker M BM, Richardet M, et al. . CheckMate 848: A randomized, open-label, phase 2 study of nivolumab in combination with ipilimumab or nivolumab monotherapy in patients with advanced or metastatic solid tumors of high tumor mutational burden. [abstract]. Presented at the American Association for Cancer Research (AACR) 2022 Annual Meeting; April 8–13, 2022; New Orleans, LA.

529. Stacchiotti S, Casali PG. Systemic therapy options for unresectable and metastatic chordomas. Curr Oncol Rep 2011;13:323–330. Available at: https://www.ncbi.nlm.nih.gov/pubmed/21584646.

Version 2.2026 © 2025 National Comprehensive Cancer Network© (NCCN©), All rights reserved. NCCN Guidelines® and this illustration may not be reproduced in any form without the express written permission of NCCN.